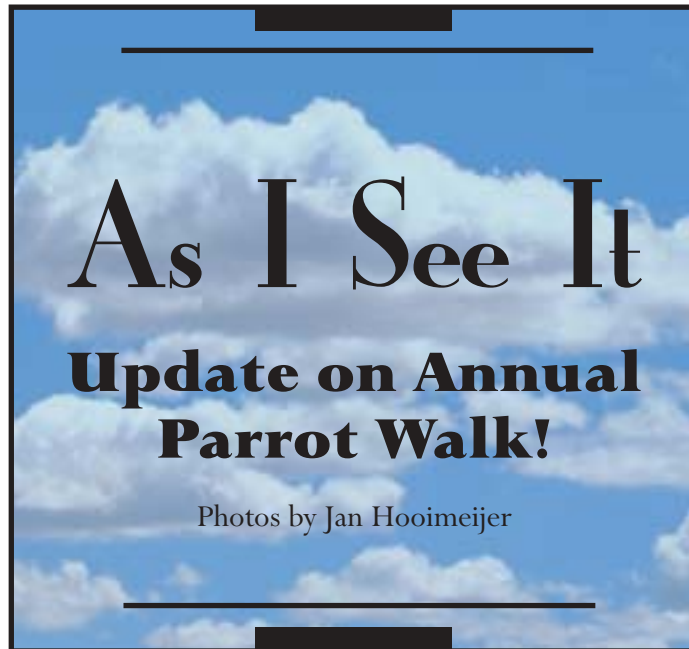




Dr. Jan Hooimeijer of HBF-Netherlands held another of his Parrot Walk picnics to promote the human/avian bond among his clients (see Avian Examiner #23). Here are some new images from the most recent celebration. These owners started with “caged” or misbehaving birds and transformed them into healthy, full-fledged family members through some behavior modification techniques and a change in diet to Harrison’s Bird Foods.



Contents

- As I See It 1
Update on Annual Parrot Walk
- Clinical Case Notes 2
Lockjaw Syndrome in Juvenile Cockatoos
New Spherical Avian Collar
Use of Fipronil in Canaries
Biochemistry Tips
Severe Malnutrition in a Macaw
- A Closer Look 5
Interpreting Avian Nutrition in the Literature
- HBD News 6
New HBD Multimedia Resource
High Potency Available in Sample Packs
Upcoming Meetings for HBD
- Using Harrison's 7
We Got Mail
- The Results Speak for Themselves 8



Clinical CASE NOTES

Lockjaw Syndrome in Juvenile Cockatiels

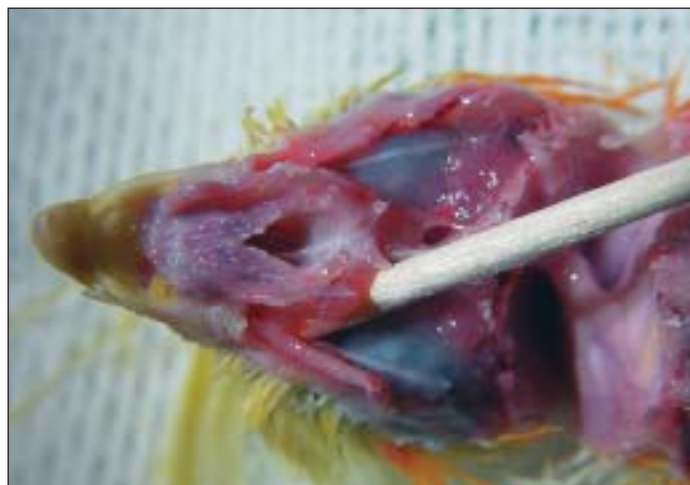Marc H. Kramer, DVM

A “lockjaw” syndrome is occasionally seen in hand-fed juvenile cockatiels. Affected birds initially demonstrate upper respiratory signs, including nasal or ocular discharge, sneezing, and swelling or redness of the cere. Subsequently, they become progressively unable to open and

close the mouth and have difficulty prehending food. Accumulation of food on the feathers of the face and neck, weight loss, and generalized unthriftiness commonly result.

It is believed that in these cases, bacteria invade from the sinuses into skeletal muscles of the mandible, resulting in “lockjaw.” Microscopically, affected birds reveal necrotizing rhinitis and sinusitis, as well as myositis, perineuritis, and osteomyelitis affecting the jaw muscles and cranial bones.

Bordetella avium has been implicated as a possible etiologic agent in this syndrome. However, multiple bacterial agents other than *B. avium* have been isolated from the



The infraorbital sinus should be closely inspected and cultured in clinical cases of lockjaw.


lungs and sinuses in many of these cases. *B. avium* in particular may cause permanent damage to the ciliary apparatus of the upper respiratory tract, leaving affected birds with chronically impaired respiratory tracts.

Once chronic inflammation and fibrosis develop, it is unlikely that jaw mobility can be restored. Antibiotic therapy is often unrewarding in these cases. However, some cases may respond to antibiotics (based on culture and sensitivity testing), supportive gavage feeding with Harrison's Bird Foods Juvenile Formula, and treatment with vitamin E/selenium.

(Ed note: This condition is not seen in birds that are fed a balanced diet. To show the variety of potential organisms, one of my long-standing clients has also empirically treated this condition with antifungals. Virologist Helga Gerlach from Germany believes B. avium is not a primary pathogen and requires concurrent infection, such as with a virus or mycoplasma, to be expressed.)

New Spherical Avian Collar

Gary Nelson, DVM



Based on many years of dissatisfaction with designs for avian collars, I developed a unique, patent-pending, spherical cervical collar that is currently being field tested by avian specialists to confirm its effectiveness. Made of medical grade, clear, polycarbonate plastic, the ergonomic form and function of the spherical collar are intended to enhance mobility, comfort, visibility, safety and ease of use. In my experience, it serves as a complementary tool for the many challenging conditions facing veterinarians and their avian patients.



Malnourished juvenile cockatiels (as reflected in this bird's poor feather condition) appear to be particularly susceptible to the syndrome of temporomandibulitis, temporomandibular joint rigidity, or “lockjaw.”

The two-step lock allows the identical hemispheres to be loosely applied on the bird before engaging the final catch. A sideways sliding action secures the sphere. The collar is designed to release rapidly using digital pressure simultaneously on two distinct points. It is possible for one person to both restrain an alert patient and apply or remove the collar.

As with any restraint device, monitoring food and water intake is important. Most birds wearing the spherical collar readily adapt to eating from their usual sources, but some modifications may be required in individual cases.

Use of Fipronil in Canaries

Peter Sandmeier, Dr med vet, Dipl ECAMS

Fipronil has been used with success to treat red mites in canaries and other passerines, although there have been no published doses. In larger birds, such as doves or ducks, I and other colleagues use fipronil at the

mammalian dose (7.5-15 mg/kg or 3-6 ml/kg Frontline®). At least in Europe, the only product on the market is Frontline® (Merial), which is available only in the 2.5 mg/ml strength.

To apply fiponil to a 20 g canary, I spray Frontline® onto a gloved finger and then rub the finger over the ventral and dorsal surfaces of the body as well as under each wing. These birds probably get a higher dose than the theoretical 15 mg/kg, but I have never seen any toxic reactions.

Biochemistry Tips*

Kendal Harr, DVM

The recommended methods of the International Federation of Clinical Chemists (IFCC) should be used to make sure that biochemistry values are standardized. If your laboratory, or more likely your dry chemistry unit, does not use these methods, then your values may not be dependable or comparable to IFCC-

obtained results. If you are depending on in-house testing to make diagnoses, your practice should be participating in the Veterinary Laboratory Association Quality Assurance Program. More information on this program can be accessed on the web at www.dclchem.com/veterinary/vla.html.

Evaluating Liver Needle Biopsies

Cole TL, Center SA, Flood SN, et al: Diagnostic comparison of needle and wedge biopsy specimens of the liver in dogs and cats. *J Am Vet Med Assoc* 220 (10):1483-90, 2002.

A recent study performed in dogs and cats illustrates the need for combined diagnostic testing, not complete dependence on liver biopsy, for the diagnosis of hepatic disease.

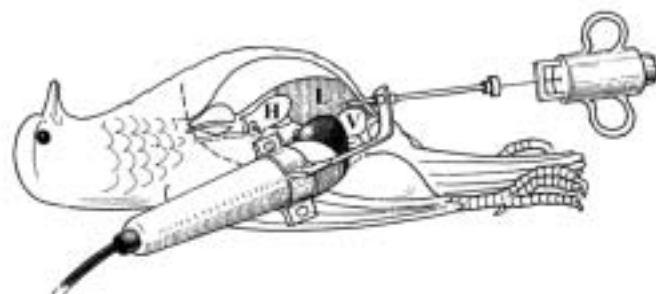
- OBJECTIVE: To compare morphologic diagnoses determined from needle biopsy specimens obtained from the livers of dogs and cats with morphologic diagnoses determined from wedge biopsy specimens.
- DESIGN: Prospective study.
- ANIMALS: 124 dogs and cats.
- PROCEDURE: 2 needle biopsy specimens were obtained from each animal; wedge biopsy specimens were obtained from

the same liver lobe during laparotomy or postmortem examination. Histologic features were scored independently by 3 individuals; a morphologic diagnosis was rendered after histologic features were scored. Cases were included only if at least 2 of the 3 examiners agreed on the morphologic diagnosis; the definitive diagnosis was considered to be the morphologic diagnosis rendered for the wedge biopsy specimen. Physical characteristics (length, width, surface area, degree of fragmentation, and number of portal triads for needle biopsy specimens and surface area for wedge biopsy specimens) were determined.

- RESULTS: Definitive diagnoses included hepatic necrosis (n = 10), cholangitis-cholangiohepatitis (13), chronic hepatitis-cirrhosis (12), canine vacuolar hepatopathy (11), portosystemic vascular anomaly-microvascular dysplasia (17), neoplasia (10), miscellaneous hepatic disorders (18), and no hepatic disease (33). For individual examiners, the morphologic diagnosis assigned to needle biopsy specimens agreed with the morphologic diagnosis assigned to wedge biopsy specimens for 56 and 67% of the specimens. All 3 examiners agreed on the mor-



Courtesy of Peter Coutteel



Ultrasound may assist in collecting needle biopsy samples from the liver of birds (from *Exotic DVM* 3[4]:29, 2001).

* Adapted from Harr K: Diagnostic value of biochemistry. In Harrison GJ, Lightfoot T, Flinchum G (eds): *Avian Veterinary Compendium*, HBD Intl, Inc, in press.

phologic diagnosis assigned to needle and wedge biopsy specimens for 44 and 65% of the specimens, respectively. Morphologic diagnoses assigned to needle biopsy specimens concurred with the definitive diagnosis for 59 of 124 (48%) animals.

■ **CONCLUSIONS AND CLINICAL RELEVANCE:** Results suggest that needle biopsy specimens of the liver from

dogs and cats must be interpreted with caution.

In human medicine, especially liver disease and transplant centers, galactose clearance tests are routinely used to assess hepatic function. Microchips for some in-house analyzers can run galactose concentrations. A human medical lab in a liver transplant center can

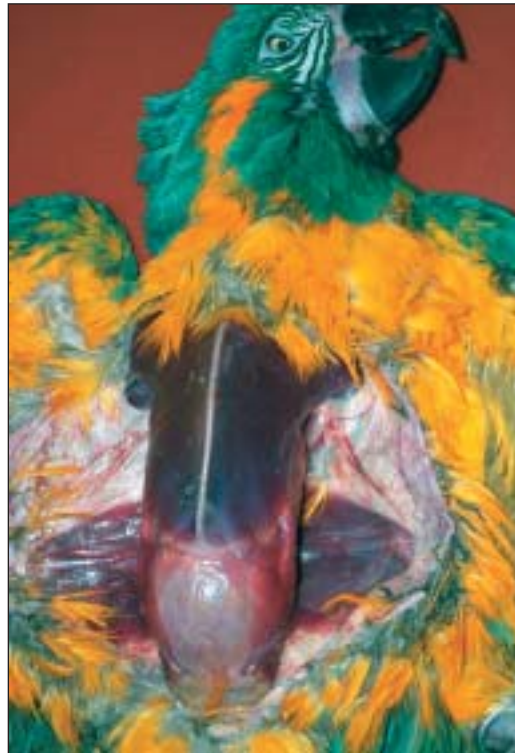also test galactose concentration. A known dose of galactose/kg body weight is given IV and then, at a set time, the samples are drawn. Because galactose is stable, no real special handling procedures are required. Current work by Jaensch, et al (Jaensch MJ, Cullen L, Raidal SR: Assessment of liver function in galahs/cockatoos (*Eolophus*

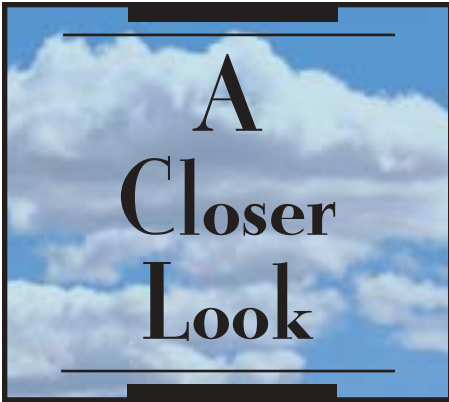roseicapillus) after partial hepatectomy: A comparison of plasma enzyme concentrations, serum bile acid levels, and galactose clearance tests. J Avian Med Surg 14:164-171, 2000) indicates that galactose clearance may also be useful in birds, specifically cockatoos. Standards for parrots need to be established.

Severe Malnutrition in a Macaw

Jan Hooimeijer, DVM

A blue-throated (caninde) macaw (*Ara glaucogularis*) that had been imported into The Netherlands from the United States was presented for necropsy at 7 years of age. The bird was extremely underdeveloped and weighed only 499 grams. The upper beak showed signs of lateral deviation. The feathers, which were of extremely poor quality, were being molted from the wings and tail at the same time. The necropsy revealed shell-less egg material in the abdomen and oviduct. I believe these clinical signs resulted from malnutrition. It was later revealed that the bird had been fed only seeds and nuts during its lifetime.





Failure to Recognize Nutritional Deficiencies of Seed Mix

Gionfriddo JR, Powell CC: A parrot with unilateral blepharitis. *Vet Med* 98(1):12-24, 2003.

Commentary:

In the Letters column of *Vet Med* 98(4):288, 2003, Robert F. Giddings, DVM, Dipl ABVP-Avian responded to the above article, which had shown a disregard for the role of nutritional disorders in most common bird presentations. The primary author of the article, a board certified ophthalmologist, admitted she had assumed seed mixes were balanced because the label said so.

One of the tip-offs should have been the condition of the beak (as shown in the photograph of the bird in the article). The beak appeared hyperkeratotic, although the authors stated, "We noted no physical abnormalities other than those involving the bird's eye."

An elongated, flaking beak, is one of the early signs of malnutrition. This bird probably also had a good chance of bone abnormalities [Harcourt-Brown N: Incidence of juvenile osteodystrophy in hand-reared grey parrots (*Psittacus erithacus*)] and disturbances in the plantar foot pattern. I would also have expected to find an abnormal fecal Gram's stain, as described by Michael Stanford (Effects of dietary change on fecal Gram's stains in African grey parrots. *Exotic DVM* 4(6):12, 2003.)

A good reference for veterinarians may be: Hess L, Mauldin G, Rosenthal K: Estimated nutrient content of diets commonly fed pet birds. *Vet Rec* 150(13):399-404, 2002. The conclusion of this article states that the optimal diet for pet birds is high in a complete and balanced formulated product, supporting manufacturers' claims that formulated products provide a more complete and balanced diet for birds than human food and seed, although not all formulated products are necessarily of comparable quality. Feeding human food and seeds met with deficiencies of vitamins A, D₃, and E, plus amino acids, tryptophan, methionine, arginine, lysine and minerals such as calcium. Excess fat made the fat-soluble vitamin problems worse.



Progression of beak lesions related to malnutrition: 1) from initial overgrowth of superficial layers, 2) to flaking, 3) to advanced elongation and delamination

Possible Role of Excess Vitamin A in Hypovitaminosis E

McDonald D: Deficiencies of vitamin E and the implications for avian reproduction. *Exotic DVM* 5(1):42-44, 2003.

Commentary:

This article states that the fat-soluble vitamins compete for site uptake and that an excess of vitamin A could occupy sites needed by other nutrients. Therefore, even though adequate vitamin E may be present in the diet, an excess of another fat-soluble vitamin can lead to a vitamin E deficiency. Graphs in this article show that Harrison's Bird Foods are some of the few products without excess vitamin A and with proper ratios of vitamins A and E.

Is Organic Food Better Than Conventional?

Asami DK, Hong Y-J, Barrett DM, Mitchell AE: Comparison of the total phenolic and ascorbic acid content of freeze-dried and air-dried marionberry, strawberry, and corn grown using conventional, organic, and sustainable agricultural practices. *J Agric Food Chem* 51(5):1237-1241, 2003.

Secondary phenolic metabolites play an important role in plant defense mechanisms, and increasing evidence indicates that many are important in human health. To date, few studies have investigated the impact of various agricultural practices on levels of secondary plant metabolites. To address this issue, the total phenolic (TP) content of marionberries, strawberries, and corn grown by sustainable, organic, or conventional cultural practices were measured. Statistically higher levels of TPs were consistently found in organically and sustainably grown foods as compared to those produced by conventional agricultural practices.

Commentary:

By Debra McDonald, PhD, Nutritional Consultant to HBD Intl): Phenolics can also help bind up some of the excess iron for those species susceptible to iron storage disease (ISD).



New HBD Multimedia Resource



The new updated version of the powerful HBD multimedia presentation, which features avian veterinarians discussing their use of Harrison's Bird Foods, is now available in several formats: VHS video (the original format), CD-ROM (for your office computer), DVD (for your home entertainment center) and online at www.harrisonsbirdfoods.com (for your convenience).

High Potency Available in Sample Packs

Just a reminder that High Potency Coarse and Fine are both available in trial sizes for you to distribute to new HBD clients.



HBD NEWS



Tanya Harrison Coffinberry

Invitation for Avian Technicians

Your technicians are invited to check out the Tech Talk section of the Avian Medicine Online message boards located at www.avianmedicine.net. Techs are encouraged to submit questions or contribute to conversations regarding the common problems of avian technicians.



Upcoming Meetings for HBD in Europe

Three special programs focusing on avian nutrition are planned for Europe in the upcoming months:

- September 28, 2003** - One-day Avian Veterinary Conference, Loughborough, United Kingdom. Sponsored by HBF-UK, speakers include Brian Stockdale, Alan Jones, Greg Harrison and Michael Stanford.
- October 4, 2003** - Parrot Symposium for Aviculturists and Veterinarians, Amsterdam, The Netherlands. Hosted by HBF-Netherlands, the primary speaker will be Jan Hooimeijer.
- November 22, 2003** - Avian Nutrition Seminar, Munich, Germany. Hosted by Rüdiger Korbelt, students and faculty from all the veterinary schools in Germany have been issued a special invitation. Speakers include Dr. Greg Harrison, Nutritionist Debra McDonald from Australia and veterinarian Michael Stanford from the United Kingdom.



At the 2003 conference of the Association of Avian Veterinarians European Committee held in Tenerife, Canary Islands, Dr. Greg Harrison (right) shares stimulating conversation with two of Harrison's Bird Foods' representatives in Europe: veterinarians Jan Hooimeijer of HBF-Netherlands (left) and Brian Stockdale of HBF-UK.



HBD's Tanya Harrison Coffinberry and Dr. Greg Harrison (from left) meet with Chris and Rebecca Taylor of Beck's Bird Farm and their veterinarian Michael Stanford (right) at the recent 2003 International Conference on Exotics (ICE) in Palm Beach, Florida. At the conference, Stanford reported on positive nutritional results from feeding Harrison's Bird Foods to African greys bred by the Taylor's in their aviary in the United Kingdom.



HBD Sales Through Pet Shops and Catalogs

HBD does not sell its products to pet stores or catalog distributors, although some veterinary colleagues choose to. This relationship works best in cases where the products are sold to the end user at the same price as in veterinary clinics. Using the HBD recommended retail price permits the veterinarian to be able to set aside clinic space for the products and to offer (at no charge) advice on how to use the products. Veterinarians often seek ways to increase business, but discounting products for short-term gain has never worked. Client loyalty is based on education and dependability, not discounts.

Humane Issues Raised as a Result of Research Study

As a result of the ongoing research of Michael Stanford reported in Exotic DVM Veterinary Magazine (showing a lack of potential

secondary gram-negative bacteria and more ideal ionized calcium and vitamin D₃ levels in birds fed Harrison's), the Ethics Committee at the Royal College of Veterinary Surgeons in the United Kingdom is questioning whether it is humane to keep Stanford's control birds on a seed supplement diet that is now proven to be detrimental to their health.

Power Treats

For over a decade, Dr. Friedrich Janeczek of Germany has used HBD's Power Treats as the primary conversion food for parrots. Janeczek recently reported adding nuts and seeds for certain species, such as green-winged and hyacinth macaws, while feeding up to 50% Power Treats (15% fat) on a regular basis.

HBD for Fruit-eating Parrot

Pesquet's parrot (*Psittichas fulgidus*) of New Guinea is a mountain dwelling parrot that consumes a lot of fruit. A study by the Bronx Zoo on basic minimum nitrogen needs showed Pesquet's parrots to require the lowest amount known for any bird. Dr. Friedrich Janeczek has pairs of Pesquet's parrots breeding successfully on a diet of 60% Harrison's Juvenile Formula and 40% fruit.

WE GET MAIL

High Potency Fine for Duckling

I am a licensed wildlife rehabber in Colorado. I recently received one duck egg that was left after a predator attacked the nest. The duckling hatched, and without siblings, it would have been hard to raise. I tried feeding duck food but it wouldn't eat it. I had Harrison's High Potency Fine Grind on hand because I feed it to my conures, so I put some in a little water. The little duckling has been eating it ever since — it's 6 days old today. He has also started picking it up dry. Thanks for helping me save a little life!
— Dee West
dlwest@ball.com

From Pet Birds to Whole Aviary

We have a small but growing aviary in Baltimore, Maryland. When we acquired our first companion birds, Donald W. Zantop, DVM of the Fallston Veterinary Clinic, told us about Harrison's Bird Food. We compared the ingredients list to other formulated diets on the market and found that only Harrison's Bird Food was 100% organic. We liked the fact that we could read and understand the ingredients list without a dictionary.

Several years ago when we decided to start an aviary of our own we made one important decision: to put all of our breeding pairs on a diet of Harrison's Bird Food with some fresh vegetables and fruit. We still did not know exactly how good your food was until we were given some rescued birds that were in very poor shape. It was amazing to see how easily the birds took to the new food after being on an all-seed diet for many years, and in no time, the birds were looking better and had more energy.

Today all of our baby birds are weaned on Harrison's Bird Food and all new owners are given some Harrison's to take home with them. We are very happy with the results that we have seen in our breeding pairs and are looking forward to a very productive breeding season this year.

— EZ Aviary, Baltimore, MD
EZAviary@comcast.net
www.EZAviary.com

Educating Australian Vet Students

The 4th year veterinary students loved the HBD video, handouts and the message it gives. Keep up the good work. Thanks again,

— Dr. Lucio Filippich
University of Queensland,
Australia



HBD's Avian Examiner is brought to you as a service of HBD International, Inc., manufacturer and distributor of Harrison's Bird Foods. This publication is part of HBD's commitment to building avian practice through education and nutritionally sound diets. Although every effort has been made to ensure the accuracy of the information presented herein (particularly drug doses), it is the responsibility of the clinician to critically evaluate the contents, to stay informed of pharmacokinetic information and to observe recommendations provided in the manufacturers' inserts. Reader responses, comments and suggestions are encouraged. Please mail to Avian Examiner, 7108 Crossroads Blvd., Suite 325, Brentwood, TN 37027 or fax to 800-279-5984.



PRSR STD
U.S. POSTAGE
PAID
THE BUREAU, INC.
33406

HBD International, Inc.

7108 Crossroads Blvd., Suite 325
Brentwood, TN 37027
800-346-0269 Fax 800-279-5984
615-221-9919
customerservice@harrisonsbirdfoods.com
www.harrisonsbirdfoods.com

The Results Speak for Themselves



These healthy young African grey parrots were hand-raised on Harrison's Juvenile Formula and hatched from parents that had been fed Harrison's Bird Foods.