

HBD's



AVIAN Examiner

Number 22



Exterior and interior of the new Harrison's Bird Foods warehouse in Brentwood, Tennessee.

HBD NEWS

We've Moved!

Since August 19, 2002, the Operations of HBD Intl, Inc. have been conducted from a warehouse/office complex in the beautiful countryside near Nashville, Tennessee. Tanya Harrison-Coffinberry, Jean Coffinberry and Nancy Coste have moved from the former office in Delray Beach, Florida in order to provide more direct supervision of the packaging and shipping of Harrison's

Bird Foods products. This move is expected to have a positive impact on:

- speed of delivery
- accuracy of orders
- consistency in quality control.

The new address is:

HBD Intl, Inc.
7108 Crossroads Blvd.
Suite 325
Brentwood, TN 37027

Phone numbers and email:

800-346-0269 or 615-221-9919
<customerservice@Harrisons
BirdFoods.com>

Contents

Thoughts on Avian Cases 2

Tracheal Endoscopy in a Canary
Quick Diagnosis of Spinal Cord
Trauma
Eclectus "Toe-tapping"
Introducing Some New Bird
Products to Try

HBD Client Booklets Available 3

A Closer Look 4

Preventing Atherosclerosis with
Antioxidants

What Your Avian Veterinarian Wants You to Know 5

About Fatty Liver and Kidney
Syndrome in Birds
(Client education handout)

Using Harrison's 6,7

Your Patients Have Problems?
We Have Solutions!
Palm Cockatoo Prospers On High
Potency
Tube-feeding Harrison's Juvenile
Formula to an Adult Lovebird
We Get Mail

The Results Speak for Themselves 8

Thoughts on AVIAN CASES

Tracheal Endoscopy in a Canary

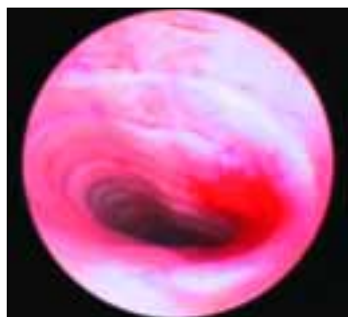
Greg J. Harrison, DVM, Dipl ABVP,
Dipl ECAMS
Lake Worth, Florida

Canaries presenting with respiratory signs are commonly suspected of having tracheal mites. The traditional examination for these mites is to wet the neck skin

.....
The traditional examination is to use a light source and magnification to visualize the mites.
.....

with alcohol and use a light source and magnification to transilluminate the trachea and visualize the mites. This technique is frequently difficult, especially in birds with minimal mite infestation and those with subcutaneous fat accumulation.

Several canaries from a collection were presented with



dyspnea, and no mites were seen via transtracheal illumination. It was decided to attempt tracheal endoscopy without anesthesia. A cotton-tipped applicator was first

used to dry the oral pharynx. Then a Storz 1.2 mm semi-flexible endoscope was introduced by passing the tip over the back of the tongue and into the trachea, going all the way into the syrinx. In one bird, it was obvious there were mites up and down the trachea. In another bird, mites could not be seen. However, lactated Ringer's was placed on a slide and the tip of this scope was dipped in the solution. Mites that could not be seen with the naked eye or even with endoscopy had come out on the tip of the scope.

Eclectus "Toe-tapping"

Brian Speer, DVM,
Dipl ABVP, Dipl ECAMS
Oakley, California
From BirdMed Discussion List
(BirdMed@numbat.murdoch.edu.au)
2/01/02

(Ed note: There continues to be discussion among veterinarians and breeders about the relationship of nutrients to toe-tapping, wing-flapping and other aberrant behavior in Eclectus parrots. Following is one practitioner's experience with the condition.)

The "toe-tapping syndrome" of Eclectus parrots, as originally described in the avicultural literature, was a rhythmic extension and contraction of the digits, particularly when the birds were at rest. At stimulation, this syndrome seemed to be voluntarily controllable by the birds. Fairly consistently, when multivitamin supplementation was discontinued, this behavior would dissipate. There was no wing-flipping, pruritis,

foot and/or leg mutilation or feather picking associated with the problem. There are general ideas as to etiology of the toe-tapping syndrome, but there are also additional conditions that seem to be "lumped" into this one syndrome.

In our experience, many of these feather picking, progressive neuropathy, leg-mutilating Eclectus parrots have ultimately been diagnosed with proventricular dilatation syndrome (PDD). Until the advanced stage of illness, most of these birds have not manifested proventricular dilatation. The differential diagnosis for toe-tapping Eclectus parrots may need to be broadened to include PDD, chronic lead toxicosis and some atypical forms of renal disease.

Quick Diagnosis of Spinal Cord Trauma

Greg J. Harrison, DVM, Dipl ABVP,
Dipl ECAMS
Lake Worth, Florida

A Quaker parakeet presented with posterior paresis without pain. The owner insisted there was no reason to suspect trauma. Alcohol was placed on the dorsal sinus process, and a hemotoma was easily identified at the thoraco-lumbar junction. This would indicate traumatic injury to the spinal cord and would suggest conservative therapy before proceeding to diagnostic tests for other CNS diseases.

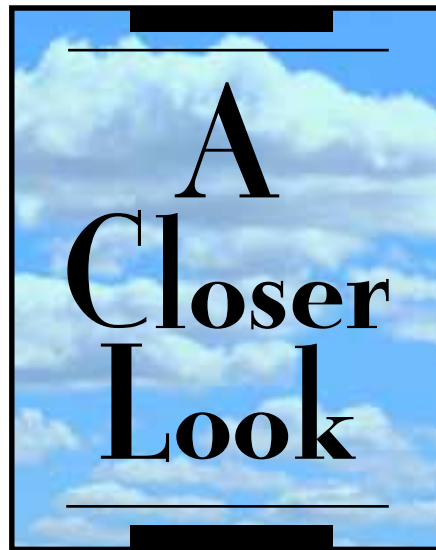
Preventing Atherosclerosis with Antioxidants

Debra McDonald, PhD

Atherosclerosis is problematic in many older psittacines. It involves the deposition of cholesterol within the innermost lining of the arteries and is associated with an inflammatory response and subsequent fibrosis. Accumulation of cholesterol can lead to atherosclerosis, but is it possible to prevent the disease with a nutritionally balanced diet rich in antioxidants.

What are Antioxidants?

Antioxidants help to counter the detrimental effects of oxygen-free radicals, which form naturally during metabolism and in response to external factors such as X-rays, UV radiation and pollution. Oxygen-free radicals have been implicated in the development of several diseases in humans, including cancer, inflammatory conditions and heart disease, highlighting the need to consider antioxidant levels as part of preventive medicine in all animals. Antioxidants



work by preventing “bad” LDL-cholesterol (low density lipoprotein cholesterol) from being oxidized and producing “foam” cells, which form fatty streaks in the walls of blood vessels. Eventually these produce atherosclerosis and arterial narrowing and increase the risk of heart attack.

Natural sources of antioxidants include vitamins A, C and E, as well as carotenoids such as β -carotene and astaxanthin. These are found in fruits, vegetables and whole grain products. Produce high in vitamin C includes capsicum (sweet red peppers) and black currants; smaller amounts are found in strawberries, cabbage, broccoli, oranges and mango. Antioxidants in food prevent oxygen from causing food to become rancid, discolored or lose flavor.

Vitamin E, an important antioxidant in the diet of birds, is the generic term for tocopherol (synthesized by green plant parts) and tocotrienol derivatives (synthesized in bran and germ fractions). Vitamin E is important to protect against free radical injury, to enhance the immune response and to play a role in the prevention of cancer, heart disease, cataracts and a number of other diseases. Along with β -carotene it is found in the core of the LDL particle, and large doses of vitamin E can prevent oxidation.

While vitamin E levels are relatively high in sunflower oil, hazelnuts and almonds, the amounts contained in these oils are below recommendations for animals maintained in captivity. In addition, the high polyunsaturated fatty acid content of these nuts may negate the high vitamin E content. The vitamin E of red palm oil has both cholesterol-lowering and cancer-inhibiting properties. These effects are specifically attributed to the high tocotrienol component of the palm oil vitamin E, which can comprise up to 70% of the vitamin E concentrate. The anti-cancer properties of the tocotrienol component of the red palm oil may be mediated through a direct cytotoxic activity or through an ability to stimulate the host immune system.



Linda and Greg Harrison met with Debra McDonald (left) during the recent conference of the AAV - Australian Committee, held in Surfers' Paradise, Queensland.



What Your Avian Veterinarian Wants You to Know About Fatty Liver and Kidney Syndrome in Birds

By Debra McDonald
Démac Wildlife Nutrition
Healesville, Victoria, Australia

Fatty liver and kidney syndrome (FLKS) is a disease (usually found in chickens) that is associated with an accumulation of a large amount of fat in the abdomen and liver, resulting in an enlarged liver (hepatomegaly) that is weakened and easily damaged. The liver contains many blood vessels that are easily ruptured during egg laying. When a hen is straining to lay, the enlarged liver is more vulnerable to injury, and the rupture of large blood vessels can lead to sufficient blood loss, resulting in death. While FLKS is often seen in healthy birds in a high state of egg production, it also affects young birds with approximately 50% higher mortality among females than males.

Although there are some hereditary tendencies towards the disease, these are not the only causes, as fatty liver in animals is often associated with toxic or nutritional diseases as well as a stressful environment.

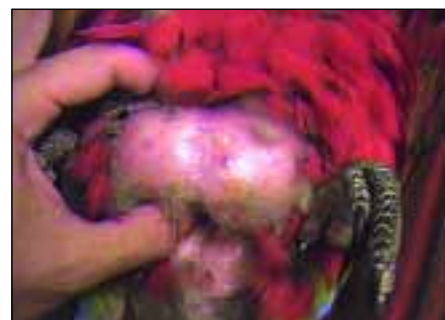One aspect of FLKS that is often ignored is the influence of dietary pesticides. While pesticide levels of

Nutritional aspects include:

- an imbalance in energy metabolism, resulting in lipid infiltration into the liver and many other organs
- protein and amino acid imbalances (low protein leads to FLKS but high dietary protein results in a biotin deficiency that can also predispose a bird to FLKS)
- inadequate levels of dietary calcium, long-chain saturated fatty acids and the vitamins choline and biotin.

individual ingredients may be deemed to be safe, a combination of a variety of pesticides or an accumulation of pesticides in tissues can result in pesticide toxicity. PCBs (polychlorinated biphenyls) increase liver and body weights of birds and can increase total cholesterol. In addition, many pesticides have estrogenic actions, and high estrogen levels are associated with FLKS. These estrogenic pesticides mimic the action of normal endogenous hormones and influence normal ovarian function. A combination of estrogen and a positive energy balance (excess dietary energy) create sufficient fat deposition in the liver for FLKS to occur.

So, while a balanced diet may minimize the potential for a bird to develop FLKS, if the ingredients are sourced from nonorganic sources, certain birds may still be susceptible to developing the disease. The best way to prevent FLKS in pet birds is to provide a nutritionally balanced diet that is composed of organic ingredients.



Massively obese scarlet macaw showing fat deposition in abdomen.

Mark H. Kramer, DVM

©2002 Harrison's Bird Foods





Your Patients Have Problems? We Have Solutions!

Friedrich Janeczek, DVM
Avifood - Germany

The use of Harrison's premium, certified organic, formulated bird foods can help maintain the bird's health while leading to improved results in treating bird diseases. Following are some examples of clinically tested applications.



Nolito Manuel C. Jardinel

■ Lipomas in Budgerigars, Amazons, Galahs and Blue and Gold Macaws

Weight reduction programs are immediately started in birds with lipomas. Within the first 8 weeks, the birds should receive limited quantities of High Potency Coarse

or Fine (15% protein, 2% fat), fruits and vegetables. During this diet change from seed mixture or table food, a slight body weight reduction can be noted. After these 8 weeks each bird will get the following approximate limited daily rations of Adult Lifetime Coarse or Fine (5% protein, 6% fat) until they reach their ideal body weight:

Budgerigar - 4 g
Amazon - 15-20 g
Galah - 15-20 g
Blue and gold macaw - 20-25 g

To satisfy eventual urge of hunger, fresh vegetables or fruits could be offered at the following amounts per bird:

Budgerigar - 2 g
Amazon or galah - 5 g
Blue and gold macaw - 15 g

After arriving at the desired weight, the food amount will be increased to maintain the body weight. At this stage, the lipomas have generally completely disappeared. Surgical removal of the remainder of the lipoma is often not necessary!

■ Chronic Disturbances of the Normal Bacterial Intestinal Microflora

Experience has shown that the intermittent use of antibiotics rarely has long-term success in cases of infection with potential pathogenic bacteria in the gut. What does work to establish a lasting normal intestinal microflora as well as reduce if not totally eliminate potentially pathogenic bacteria in the gut are: 1) diet change from conventional seed mixtures to Harrison's; 2) reduc-

tion of fruit and vegetables (for recommended amounts see above); 3) higher level of husbandry hygiene.

■ Elevated Liver Parameters, Triglycerides and Cholesterol

Necropsies and clinical examinations suggest the presence of chronic liver diseases in the majority of parrots and parakeets on a seed/table food diet. A diet change from the conventional seed mixture to Harrison's leads to improvement of the hepatopathies and a reduction of the increased levels of triglycerides and cholesterol. The therapeutic success can be documented through regular biochemical serum profiles.

■ Tube-feeding Sick Birds or Patients with Body Weight Loss

During acute illness and reduced food intake, the intensive metabolism of bird patients leads very quickly to a life-threatening loss of body weight. Using a silicon crop tube, one can administer the easily digestible hand-feeding formula, **Passerine Formula 1 (Psittacine Intensive Care Formula**, 35% crude protein, 19% crude fat) and the bird will receive a sufficient amount of liquid, nutrients, vitamins, minerals and trace minerals. Necessary medication can easily be mixed into the food. After a distinct improvement of the patient, a slow changeover to the hand-feeding formula, **Juvenile**

Hand-feeding Formula (18% crude protein, 11% crude fat), is recommended. After that, preferably **High Potency Coarse** or **Fine** should be given. These have similar ingredients as the **Juvenile Hand-feeding Formula** and seem to be the perfect convalescent food for your patient.

■ Hand-raising Parrots and Parakeet Chicks

The hand-raising food, **Passerine formula 2 (Psittacine Neonate Formula)** is ideally suited for the hand-raising of parrots and parakeet chicks from their 1st to 21st day of life. Its 26% crude protein and 12% crude fat, together with its easy digestibility and balanced composition, lead to weight gains similar to parental raising. After the 22nd day, one recommends a slow change to the Juvenile Hand-feeding Formula. **High Potency Coarse** or **Fine** should preferably be used for the weaning of the chicks.

■ Passing of Undigested Seeds

A few diseases of the digestive tract (eg, proventricular dilatation disease, chronic infections with bacteria and fungi) can lead to the excretion of undigested seeds in the feces as well as to emaciation of the birds even after good food intake. In such cases, the feeding of **High Potency Fine** is highly recommended to support the therapy. The extruded food

particles (app. 3 mm in size) consist of finely ground components. They dissolve within the crop and proventriculus into an easy digestible mush. Additional offerings of digestive enzymes (Avizyme) can support the absorption of the nutrients. **High Potency Fine** is also suitable for the prophylactic feeding of clinically inconspicuous birds in collections with proventricular dilatation disease.

■ Mycotic Diseases in Parrots and Parakeets

Chronic infections with fungi, yeasts and mycotoxins are frequent reasons for the death of parrots. Regular intake of seed mixtures and nuts contaminated with fungi, their spores and mycotoxins, as well as permanent housing in badly aired rooms without direct sunshine are the principal causes for the development of a mycotic disease. With exclusive antimycotic treatment, a lasting therapy success is rather unlikely. The complete change from the previous, mostly unbalanced and qualitatively inferior diet to Harrison's High Potency Coarse or Fine with a higher content of vitamin A and its precursors are an essential therapeutic and prophylactic measures.

Palm Cockatoo Prospers On High Potency

*Greg J. Harrison, DVM, Dipl ABVP, Dipl ECAMS
Lake Worth, Florida*

A recently purchased palm cockatoo was presented.



Within a month, the fecal Gram's stain results were improving, and the feathers had started to molt into normal, shiny, black contour feathers.



Five months later, the bird had lost most of the beak keratin. After a grinding to remove 1 cm of build-up on the occlusal surface, none has regrown. The bird has become calm and beautiful, as shown with visiting veterinarian, Jan Sjöberg from Oslo, Norway.

Physical examination showed pansystemic accumulation of keratin, most notably on the beak, legs and feet. The feathers were an abnormal brownish-black color. The fecal Gram's stain showed a very scant number of normal bacteria. At the time of purchase, the client was told to continue feeding a diet consisting of about 40% formulated bird food and the rest, a combination of sunflower seeds, apple and broccoli.

Although palm cockatoos are relatively rare and seem to have specific dietary needs, others in our care have thrived on Harrison's High Potency Coarse Grind. We

normally add a nut every day and approximately 20 g green leafy vegetables, but avoid sweet fruit. The bird was converted to the new diet in a few days.

Tube-feeding Harrison's Juvenile Formula to an Adult Lovebird

*H.M. Good, DVM
Santa Cruz, CA*

A 7-year-old peach-faced lovebird of unknown sex was presented at my clinic in an emergency after being attacked by a larger bird. Its lower beak and mandible had been fractured, and the tongue was deeply lacerated. The owners did not want to attempt treatment and then signed the bird over to me.

During the initial phase, it was obvious that I would need to tube-feed it — its tongue was grossly inflamed and painful, and its lower beak/mandible was useless. It was given injectable Baytril® as a tube-fed oral medication along with Harrison's Juvenile Formula during that time, and it progressed well from the depressed, shocky and painful state it was in. About 10 days later, I anesthetized it, debrided the beak fracture site and used dental acrylic to repair it. It soon became apparent that the beak was not the only thing stopping it from eating on its own. The bird continued to require being tube fed, and approximately 10

days after that, its tongue fell out, leaving only an immobile small stub. It became apparent that this bird would always need some kind of special feeding assistance, and tube-feeding became the only way to properly maintain this bird.

It has been 6 years now, and this lovebird has lived on Harrison's Juvenile Formula tube fed approximately 6 times per day, and he has done considerably well. He has had occasional crop-emptying problems, which improve if I don't overfill the crop and watch for yeast overgrowth. I do occasionally acidify the drinking water with vinegar and add acidophilus to the gruel. Recently, after consultation with Dr. Harrison, I added milk thistle to the regimen, which seemed to turn around the bird's lethargy and bright green stools.

WE GET MAIL

We are slowly winning the battle (for formulated diets in our practice) — sales of Harrison's have shot up and the birds are so much the better for it. Almost all the clients are delighted at the ease with which the birds take to it.

William Lewis, BVSc, MRCVS

My own cockatoo exhibited mited gas or borborygmus when eating bean-laden diets like the early Kray diet. Harrison's cured this!

Shawn Ashley, DVM



HBD's Avian Examiner is brought to you as a service of HBD International, Inc., manufacturer and distributor of Harrison's Bird Foods. This publication is part of HBD's commitment to building avian practice through education and nutritionally sound diets. Although every effort has been made to ensure the accuracy of the information presented herein (particularly drug doses), it is the responsibility of the clinician to critically evaluate the contents, to stay informed of pharmacokinetic information and to observe recommendations provided in the manufacturers' inserts. Reader responses, comments and suggestions are encouraged. Please mail to Avian Examiner Publications, 7108 Crossroads Blvd., Suite 325, Brentwood, TN 37027 or fax to 800-279-5984.



HBD International, Inc.

7108 Crossroads Blvd., Suite 325
Brentwood, TN 37027
800-346-0269 Fax 800-279-5984
615-221-9919
customerservice@harrisonsbirdfoods.com
www.harrisonsbirdfoods.com

PRSRT STD
U.S. POSTAGE
PAID
THE BUREAU, INC.
33406

The Results Speak for Themselves



Murray, a yellow-collared macaw (*Ara auricollis*), initially showed subtle signs of malnutrition: a dull, drab appearance to the feathers with a black discoloration within the feathers (which are not uniformly green, anyway), retained pin feathers, dry and flaky beak, long nails. Even as early as 3 months following a diet change to Harrison's, improvement was obvious.