

**F**ungal infections are frequently associated with morbidity and mortality in companion birds. Like bacterial- and viral-induced diseases, the clinical features of a fungal infection may be influenced by stress factors and the age and condition of the patient. Candidiasis is frequently associated with gastrointestinal problems in neonates. Aspergillosis continues to be an important respiratory disease in psittacine species, zoo species and raptors. Improved preventive techniques and therapeutic regimes have enhanced the practitioner's ability to deal with common fungal pathogens.

However, many clinical reports detail the effects of less commonly diagnosed fungal pathogens about which relatively little is known. Current interest in avian pathology has resulted in the identification of disease conditions that were unrecognized in the past. Several of the avian fungal agents have zoonotic implications that must be addressed in the management of the patient.

Reducing stress, maintaining a healthy environment, carefully limiting the use of antibiotics and reducing exposure to fungal organisms are important in preventing these diseases.

---

CHAPTER

35

MYCOSES

---

**Louise Bauck**

## Common Fungal Diseases

### Candidiasis

*Candida albicans* is an opportunistic yeast that can cause a variety of problems associated with the avian digestive tract (see Color 19). This agent is frequently implicated in cases of ingluvitis (commonly referred to as “sour crop”).<sup>16</sup> The clinician should be reminded that this terminology is a summation of a clinical sign and not a diagnosis. *Candida* sp. can apparently be a primary cause of crop-related infections or can be a secondary pathogen that takes advantage of an already damaged esophageal mucosa or of a slowed crop-emptying time.

#### Transmission and Predisposing Factors

*Candida albicans* is a common environmental organism and may be a normal inhabitant of the avian digestive tract. The loss of normal bacterial flora (eg, through the use of antibiotics) can cause an increase in the number of candida organisms. Immature animals are thought to develop spontaneous primary candidiasis possibly because of an immature immune system or incompletely developed gastrointestinal (GI) defenses. Neonatal cockatiels are thought to be especially prone to primary candidiasis.<sup>45</sup>

#### Pathogenesis and Incubation

Reduced competition with normal gut flora or a break or weakness in the mucous membranes may precipitate colonization and budding by this opportunistic yeast. The magnitude and outcome of the infection may depend on the age of the bird and status of the immune system. Chronic or systemic infections may result in septate hyphae and reproductive chlamydo spores that can be demonstrated by histologic examination. *Candida* sp. infections are characterized by necrosis with minimal inflammation.<sup>5</sup> The exact incubation period is unknown, but birds being treated with antibiotics frequently show increased numbers of yeast several days after initiating antibiotic therapy.

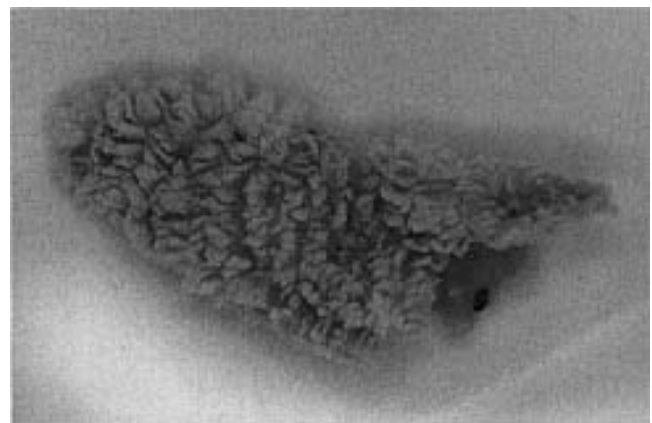
Systemic candidiasis is rare but has been reported in companion birds. In these cases, yeast may be present in the blood, bone marrow and parenchymous organs.<sup>17</sup> Severe stress or immunosuppression may be necessary to potentiate systemic infections.

#### Clinical Disease and Pathology

In most young birds, the crop is the principal site of a candida infection. In many cases, the crop may be the only portion of the digestive tract affected. However, several reports also indicate that in some young birds, the proventriculus or ventriculus can be the primary site of yeast replication in the absence of crop lesions.<sup>7,17,20</sup> The characteristic *Candida* lesion is a catarrhal-to-muroid exudate consisting of raised, white mucosal plaques and whitish-to-clear mucus that may or may not be associated with a foul odor. Chronic cases may develop a “turkish towel” appearance produced by multiple tag-like plaques of mucosa and inflammatory cells (Figure 35.1) (see Color 19).<sup>52</sup>

Clinical signs associated with candida-induced ingluvitis in neonates include regurgitation or vomiting, increased crop-emptying time, depression, anorexia and occasional crop impactions.<sup>42</sup> In older birds, the crop may be distended with mucus, and crop emptying may be hindered by necrotic mucosal debris. Candida lesions in the oral cavity are recognized by the appearance of white plaques covered by a tenacious mucus.<sup>31,34</sup> Candida has been associated with impacted food, beak abnormalities and tongue necrosis in a variety of adult birds. Yeast infections in ratites have been associated with extensive necrosis of the upper beak.<sup>34</sup>

Although less frequent, candida infections may also be found outside of the GI tract. Yeast infections affecting the cloaca and vent of turkeys and geese have been reported.<sup>4,28</sup> Skin lesions, particularly on the head and neck, have been described in companion birds and pigeons.<sup>39,52</sup> Primary candida infections have also been associated with foot lesions in waterfowl.<sup>12,36</sup> Respiratory infections caused by candida occasionally have been reported in psittacine



**FIG 35.1** Characteristic “turkish towel” appearance of the crop mucosa in a young budgerigar with severe candidiasis.

birds.<sup>19,20</sup> Birds being treated with prolonged antibiotic therapy for upper respiratory tract infections may develop secondary candida infections. Systemic candidiasis in a flock of canaries was associated with central nervous system signs in addition to those routinely noted with gastrointestinal infections.<sup>35</sup> Pericardial lesions attributed to *Candida* spp. were reported in a Sun Conure.<sup>48</sup> Lameness was the principal clinical sign in a Blue-fronted Amazon with candidiasis.<sup>17</sup>

### Diagnosis and Differential Diagnosis

A subjective diagnosis of gastrointestinal candidiasis is often suggested by the history and clinical signs. A Gram's stain of material collected from the site of suspected infection is helpful in confirming a diagnosis (see Color 8). Identifying yeast with a Gram's stain suggests only that the organism is present. Histologic evaluation of biopsy samples is necessary to confirm that the yeast are causing pathologic changes. However, identifying large numbers of budding organisms is suggestive of a prolific population of yeast. Negative cytologic results do not rule out candidiasis, because deep mucosal scrapings are necessary to achieve adequate samples in some cases.<sup>34</sup>

Gram's stains usually provide adequate visualization of yeast but dry smears can also be stained with Diff-Quik<sup>a</sup> and new methylene blue. Lactophenol cotton blue is recommended for wet mounts.<sup>5</sup> The yeast organism, which is often budding, is small (3 to 6  $\mu$ m diameter), and has been compared to the size of an avian red blood cell nucleus.<sup>27</sup> Hyphal forms are considered more diagnostic of a primary yeast infection but are less commonly found in a live patient (see Color 10).

Because candida is frequently a secondary pathogen, the clinician should attempt to determine the predisposing factors that lead to a candida infection. Oral and upper gastrointestinal candidiasis may show signs similar to those of trichomoniasis, hypovitaminosis A, avian poxviruses, bacterial infections, psittacine beak and feather disease, neonatal gastrointestinal viruses, ingested foreign bodies and toxicities. Culturing the organism may be helpful, especially in cases involving beak abnormalities or systemic problems. Sabouraud's<sup>b</sup> or cornmeal agar are the recommended culture media.<sup>5</sup>

### Treatment

Effective candida therapy must include the resolution of predisposing factors such as environmental or nutritional stress, poor hygiene and unnecessary an-

tibiotic therapy. Nystatin is the most frequently used medication for initially treating upper gastrointestinal candidiasis in the avian patient, although some of the azole antifungals are undoubtedly more effective. Nystatin has few side effects and is not absorbed from the gastrointestinal tract following oral administration. It is readily accepted by most birds and can be mixed with a neonate's feeding formula (Table 35.1). Ocular candidiasis is usually responsive to amphotericin B ointment or amphotericin B injected subconjunctivally.

TABLE 35.1 Some Antifungal Agents Used in Companion Species

Amphotericin B <sup>c</sup> (injectable)	1.5 mg/kg IV TID x 3 days 1.0 mg/ml saline intratracheal BID 1 mg/ml saline nebulized for 15 min BID
Flucytosine <sup>d</sup> (capsules)	250 mg/kg PO BID x 21 days
Ketoconazole <sup>e</sup> suspension (tablets)	10-30 mg/kg BID x 21 days
Itraconazole <sup>f</sup> (beads in capsules)	5-10 mg/kg BID in food for 7-21 days
Fluconazole <sup>g</sup> (tablets)	5 mg/kg SID for 7 days
Nystatin <sup>h</sup> (suspension)	100,000 units (1 ml) per 400 gram bird PO BID x 7 days

Ketoconazole is recommended for severe or refractory candidiasis. Although more costly and difficult to administer, it is a very effective systemic antifungal with a high therapeutic index.<sup>5,32,46</sup> Side effects may include vomiting and elevation of liver enzymes.<sup>17</sup> Ketoconazole is normally mixed with a slightly acidic liquid (eg, orange juice, pineapple juice) to facilitate its dilution. *Candida* prefers an alkaline environment and this acidification of the GI tract will have therapeutic value.

Strains of *Candida* spp. resistant to ketoconazole have been reported, and fluconazole has been suggested as a treatment of choice for these strains.<sup>33</sup> Little information is available on the use of this drug in birds; however, reported side effects have been minimal. Itraconazole has also been used to treat candidiasis,<sup>15,20,23</sup> but may offer no real advantage over other azoles. Miconazole has been reported to be effective in treating yeast infections, but few reports exist on its use in companion birds.<sup>54</sup> Azole antifungals may cause depression, anorexia, vomiting and hepatic toxicity.<sup>38</sup>

## Aspergillosis

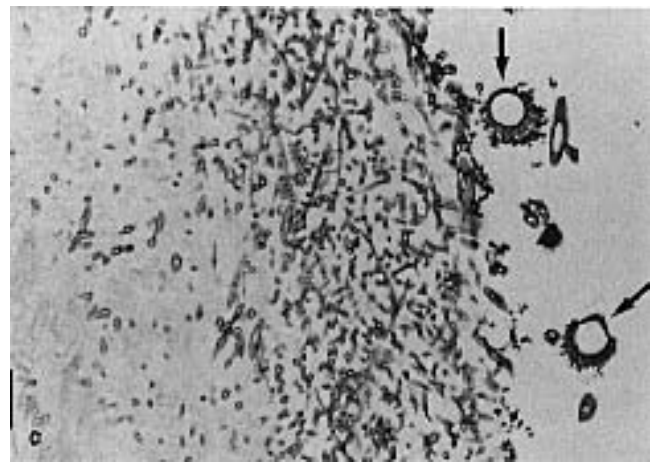
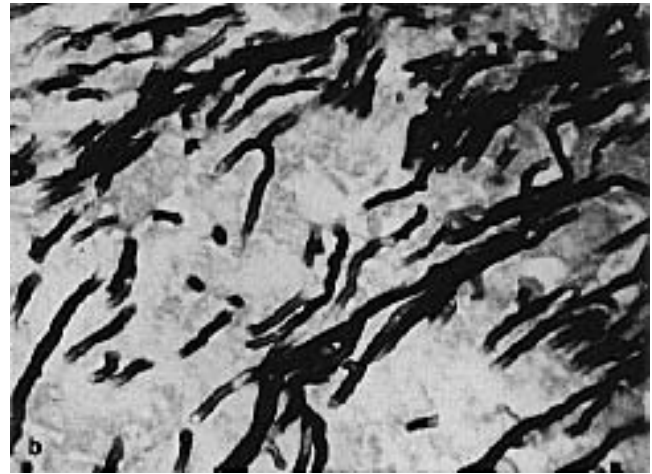
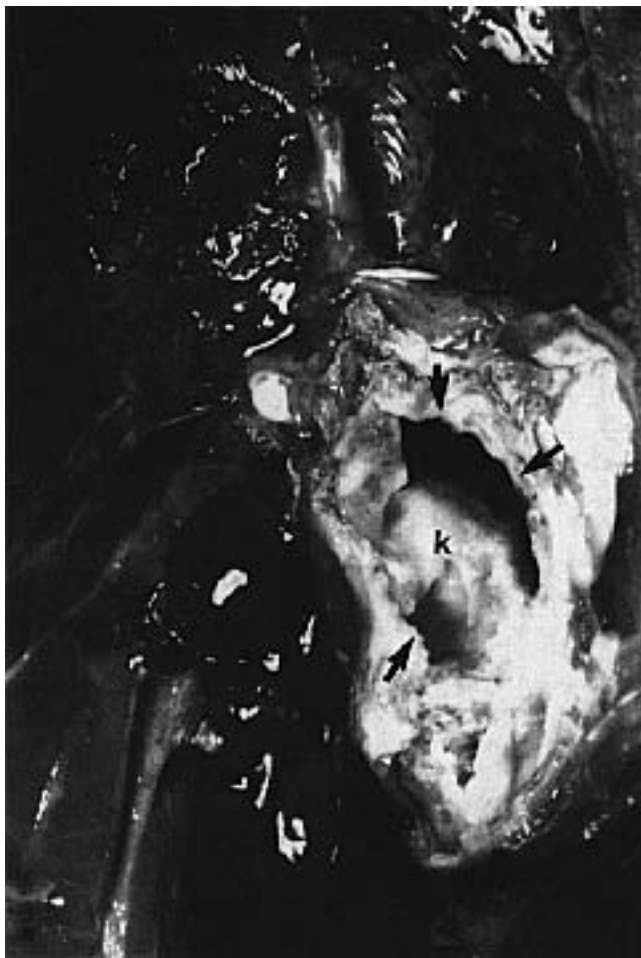Aspergillosis is a disease of economic importance in the poultry industry (brooder pneumonia), and is a frequent cause of respiratory disease in companion, aviary and free-ranging birds. *Aspergillus fumigatus* is the most common etiologic agent, followed in frequency by *A. flavus* and *A. niger*. Aspergillosis may be chronic and insidious, or it may cause peracute death. Established aspergillosis infections are clinically challenging to resolve.

### Transmission and Predisposing Factors

Penguins, birds of paradise, pheasants, waterfowl (especially diving birds and shorebirds), Goshawks and Gyrfalcons are believed to be especially susceptible to *Aspergillus* spp.<sup>15,37,45</sup> Among companion birds, a high prevalence of aspergillosis has been reported

in African Grey Parrots, Blue-fronted Amazon Parrots and mynah birds.<sup>30,45</sup> Aspergillosis is occasionally described in pigeon flocks with one report listing a prevalence of 2.4%.<sup>37</sup>

Gallinaceous birds (particularly quail) often become infected as chicks following inhalation of spores from contaminated brooders.<sup>16</sup> Hand-raised psittacine birds could be infected in a similar manner. Older gallinaceous birds, and presumably aviary birds as well, can be exposed when maintained on moist contaminated bedding. Moldy straw is a particularly common source of numerous fungal pathogens including *Aspergillus* spp. Waterfowl may be infected by feeding on moldy corn or wheat straw.<sup>29</sup> Zoo birds that are contaminated with oil, or birds maintained in damp, poorly ventilated areas are frequently infected.



**FIG 35.2** A mature Black Palm Cockatoo had a history of progressive rear limb ataxia and weight loss. The bird was presented for necropsy. **a)** Gross findings included a proliferative, white, fuzzy mass that was covering a thickened left abdominal air sac. When the ventral border of the mass was removed, the cranial and middle lobes of the left kidney were also found to be involved. **b)** An impression smear from the interior of the mass stained with new methylene blue revealed numerous branching septate hyphae suggestive of *Aspergillus* spp. **c)** Histopathology indicated thickened air sacs with fungal hyphae and fruiting bodies, which are characteristic of *Aspergillus* spp. growth in an oxygen-rich environment (courtesy of Kenneth Latimer, reprinted with permission<sup>18</sup>).

### Pathogenesis and Incubation

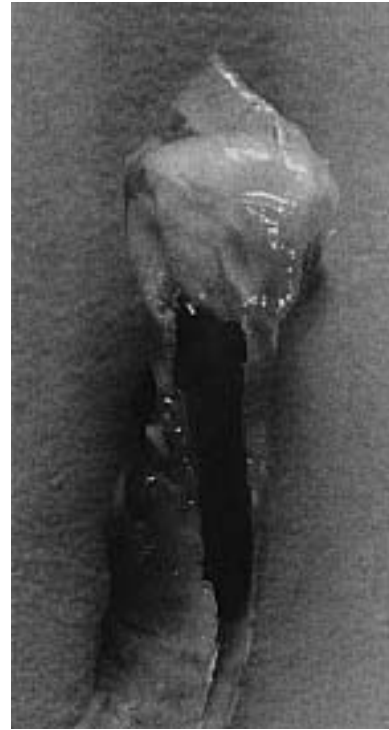*Aspergillus* is ubiquitous, and infections should always be considered to occur secondarily to an immunosuppressive event. It has been suggested that healthy birds exposed to high concentrations of spores are generally resistant to infections, while immunocompromised hosts exposed to small concentrations of spores are frequently infected. Factors that influence the susceptibility of a bird to aspergillosis include shipping, overcrowding, malnutrition, poor ventilation, very young or old age, antibiotic therapy (particularly tetracyclines), corticosteroid administration, respiratory irritants (eg, disinfectant fumes, cigarette smoke, ammonia) or concomitant disease.<sup>5,16,24</sup>

The type of disease induced by aspergillosis is thought to be dependent on the source and number of spores contacted and the general condition of the bird.<sup>6</sup> Healthy birds can generally withstand exposure to a high concentration of spores.

Aspergillosis infections are generally divided into local and systemic diseases. Lesions frequently originate in one system or area (eg, lower respiratory tract) and later advance into adjacent organs and systems as the disease progresses (Figure 35.2). Acute cases occur when spores germinate in a particularly vital area or when multiple lesions germinate at once.

A single air sac lesion may have a protracted course while a single lesion in the trachea or syrinx may quickly prove fatal (see Color 22). The syrinx or tracheal bifurcation is thought to be a common location for aspergillosis colonization because air turbulence patterns may cause the spores to drop out of the air stream at this point in the respiratory system.<sup>49</sup> Alternatively, the narrowing in the respiratory tract at this point may predispose it to blockage with necrotic debris.

There is a small area of stratified squamous epithelium in the syringeal area of some birds that can be modified by hypovitaminosis A. Tissue hypertrophy and hyperkeratosis may occur, allowing colonization by inhaled aspergillosis spores (Figure 35.3). Nasal aspergillosis also occurs in the avian patient.<sup>25,55</sup> Cutaneous, skeletal and gastrointestinal forms have been reported in rare instances.<sup>11,24,26</sup> An ocular form has been described in gallinaceous birds.<sup>6,16</sup> The incubation period associated with aspergillosis varies with the type of exposure. Experimentally infected ostrich chicks died two to eight days following expo-



**FIG 35.3** A ten-year-old Amazon parrot was presented with a three-week history of progressive dyspnea that had advanced to the point of post-exercise collapse. The bird was anesthetized with isoflurane, and an air sac tube was placed in the abdominal air sac. Tracheoscopy revealed a large proliferative white mass in the syrinx. The bird was breathing through a hole in the center of the mass the size of a 20 ga needle. Attempts to remove the mass were unsuccessful. At necropsy, the bird was normal except for the aspergilloma in the syrinx. The air sacs were clear. The bird was on an all-seed diet, which may have resulted in squamous metaplasia in the syrinx and precipitated an infection.

sure to spores (see Color 22). Air sac infections in mature birds may progress for weeks, or can induce granulomas that are present for months.

### Clinical Disease and Pathology

Clinical signs associated with aspergillus infections of the respiratory tract may include dyspnea, depression and emaciation (Table 35.2).<sup>10</sup> Open-mouthed breathing, pronounced excursions of the keel, tail “bobs” and respiratory distress after exercise are typical. Biliverdinuria is common. Wheezing, squeaking or stertor and a voice change are also sometimes present. Posterior paresis and lameness were the presenting signs in a Black Palm Cockatoo with *Aspergillus* spp. air sacculitis that spread to the kidney and pelvic nerve roots.<sup>18</sup> Signs related to the target organ(s) are seen in the less common forms of aspergillosis. Aspergillosis may be associated with ascites caused by peritonitis or cardiopulmonary im-

pairment, usually secondary to aspergillosis-induced thrombi in the pulmonary vessels.

**TABLE 35.2 Clinical Findings in Companion Birds with Aspergillosis\***

Emaciation	64%
Respiratory distress	26%
Neuromuscular disease	18%
Abnormal droppings	11%
Regurgitation	9%
Vocalization changes	7%
Poor appetite	7%
Nasal discharge	4%
Gout	4%
Hemoptysis	2%

\* Adapted from McMillan MC, et al.<sup>30</sup>

In systemic cases in gallinaceous chicks, lesions are typically found in lungs, air sacs, heart muscle, liver and abdominal viscera.<sup>13</sup> Grossly, lesions in all areas are similar. A cream- to yellow-colored granuloma or plaque is present with or without gray or white “cotton-wool” mycelial masses (see Color 22).

Destruction of adjacent tissue, including bone or beak, may be substantial (Figure 35.4). Nasal aspergillosis typically presents as a dry, granulomatous, destructive swelling within one nostril. Histopathological examination of granulomas generally shows a necrotic foci surrounded by macrophages, heterophils and giant cells, sometimes within a connective tissue capsule (Table 35.3). Tracheal or syringeal aspergillosis lesions usually occur as plugs of creamy white necrotic debris at or near the tracheal bifurcation. Ocular aspergillosis in chicks may be recognized as a white exudate within the conjunctival sac.<sup>6</sup>

**TABLE 35.3 Histopathologic Findings in Birds with Aspergillosis**

Granulomatous pneumonia	66%
Fungal air sacculitis	53%
Bronchopneumonia	37%
Tracheobronchial mycetomas	20%
Acute necrosis with thrombosis	17%
Concurrent infection	40%

\* Adapted from McMillan MC, et al.<sup>30</sup>

### Diagnosis and Differential Diagnosis

History, signalment, physical examination findings and hematologic findings (heterophilia and anemia) may be suggestive of an aspergillosis infection. Fungal culture, hematology, serology, cytology, radiology and endoscopy or exploratory surgery are among the methods used to diagnose infections (Table 35.4). It should be noted that culture of *Aspergillus* spp. in the



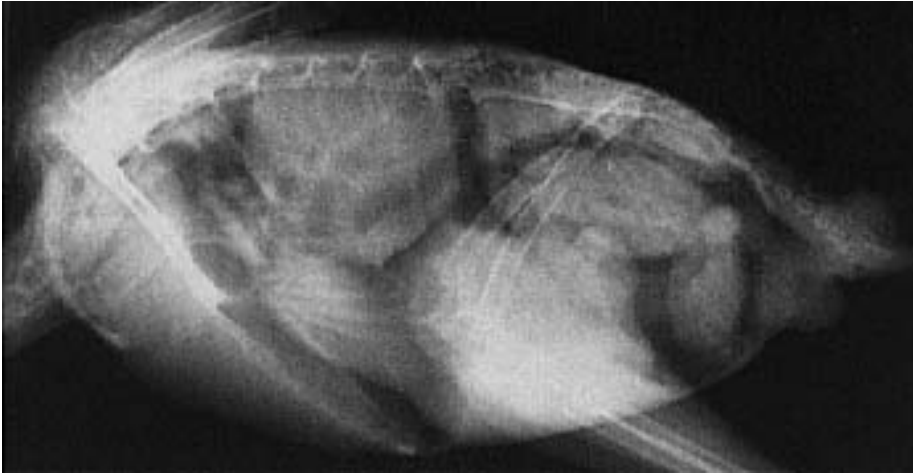**FIG 35.4** A mature African Grey Parrot was presented with an advanced case of nasal aspergillosis. The nostril and operculum had been damaged by pressure necrosis. The extent of damage to the germinative epithelium is demonstrated by a severe defect in the beak. This photograph was taken several weeks after debridement and treatment of the infected tissues with miconazole (courtesy of Louise Bauck).

absence of lesions is not diagnostic, because the organism is ubiquitous in the environment. Radiographic findings can be negative or may show hyperinflation (enlargement) of the abdominal air sacs, focal densities in lungs or air sacs, reduced coelomic cavity details, loss of definition of air sac walls and asymmetrical opacity of abdominal air sacs (Figure 35.5).<sup>30</sup> Cytology of air sac washes or endoscopic-guided biopsy are useful in diagnosing lower respiratory infections.

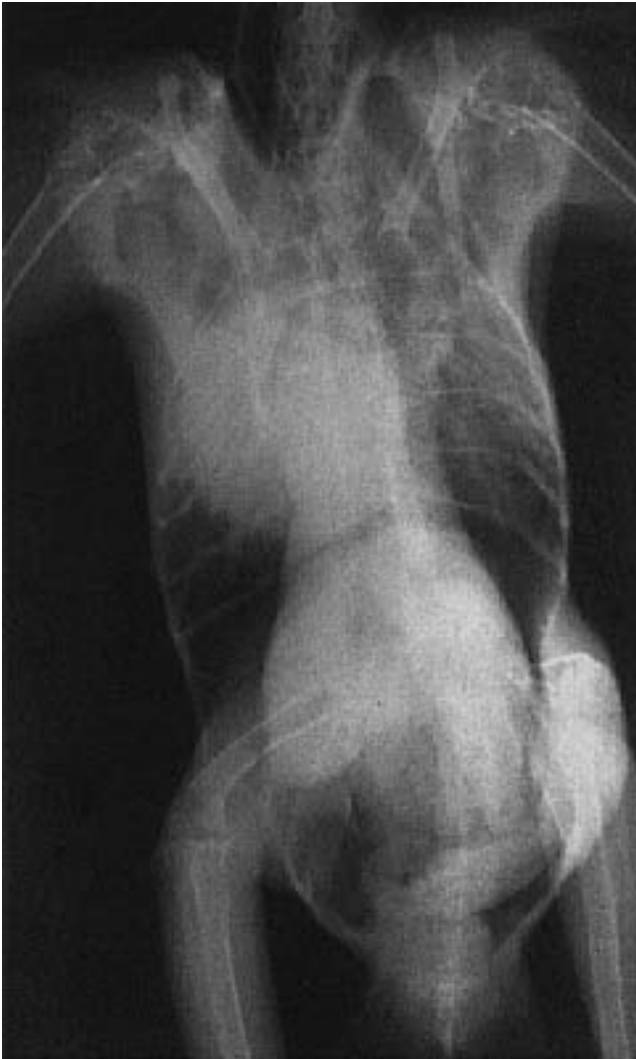For definitive antemortem diagnosis, cytologic samples from granulomas with associated mycelial areas (wet mounts with lactophenol cotton blue, new meth-

**TABLE 35.4 Typical Clinical Pathology Changes with Aspergillosis**

Leukocytosis - heterophilia
Monocytosis
Lymphopenia
Nonregenerative anemia
Hyperproteinemia
Hypergammaglobulinemia



**FIG 35.5** A mature Double Yellow-headed Amazon Parrot was presented with a history of severe dyspnea. Radiographs indicated a large soft tissue mass that was localized to the right lung and cranial thoracic air sac. A slightly oblique, rather than ventrodorsal, radiograph was made to better visualize the thoracic mass. An aspergilloma was diagnosed at necropsy (courtesy of Marjorie McMillan).



ylene blue and culture on Sabouraud dextrose agar or blood agar) may be diagnostic. The presence of branching septate hyphae, sometimes with spores and sporulating areas, is highly suggestive (see Figure 35.2b). Culture may distinguish *Aspergillus* spp. from other fungal organisms such as *Penicillium* spp. and *Mucor* spp. If access to a suggestive lesion is not available, then serology may be helpful. Although not widely available, aspergillosis titers using ELISA systems show promise in diagnosing infections.<sup>3,57</sup> Latex agglutination and complement fixation methods have also been described. Several of these tests are available on a commercial basis for gallina-

ceous birds, and an ELISA test is available in the United States for detecting anti-aspergillus antibodies.<sup>22</sup>

The differential diagnosis for a mature bird with weight loss and severe heterophilia might include chlamydiosis and mycobacteriosis. Neoplastic disease may sometimes cause weight loss and heterophilia. Severe dyspnea can also be caused by increased abdominal pressure (eg, mass, ascites, hepatomegaly), pneumonia and inhaled foreign bodies. Eye lesions, as described in gallinaceous birds, may be caused by hypovitaminosis A.

#### Treatment

Treatment of aspergillosis often depends on the location and extent of the lesion. Resolving advanced cases of aspergillosis is difficult, especially in anatomic areas where surgical removal of affected tissues is not possible. Correction of underlying stress factors is a mandatory component of successful therapy. Surgical debridement of plaques and granulomas should be employed when feasible.<sup>5,29,44</sup> Flushing lesions with amphotericin B or chlorhexidine solutions may be helpful, although caution should be exercised in certain anatomic areas. A severe granulomatous sinusitis occurred in an African Grey Parrot following the accidental use of amphotericin B suspension rather than a solution as a nasal flush.<sup>55</sup>

Intratracheal administration of amphotericin B has been used in treating tracheal and pulmonary asper-

gillosis. The medication is given via the glottis during inspiration and the patient is positioned to distribute the drug to the affected anatomic area.<sup>40,44</sup> Nebulization with antifungals may be helpful in early cases of upper respiratory aspergillosis.<sup>5,48</sup> Topical treatments with amphotericin B or other antifungal creams may be of value in external lesions in combination with systemic therapy (see Figure 35.4).<sup>5,25</sup> Systemic therapy is difficult because amphotericin B must normally be administered intravenously TID for three days. Intraosseous administration should be possible, but has not been documented. Amphotericin B is potentially nephrotoxic.

Flucytosine is also frequently used to treat aspergillosis, especially in combination with amphotericin B (Table 35.5). The advantage to this drug is that it can be administered orally; however, bone marrow toxicity has been reported in some cases. Monitoring for hematologic changes suggestive of bone marrow damage is recommended when this drug is used.

Some of the azole antifungals have good efficacy against aspergillosis in mammals and may be administered orally. Ketoconazole has been used to successfully treat aspergillosis in some avian species. This drug preparation has an advantage over other antifungals in having a wide therapeutic index.<sup>2,26,42,44,47,53</sup>

Current information suggests that itraconazole may have greater efficacy against *Aspergillus* spp. than amphotericin B or any other azole antifungal.<sup>15,20,53,54</sup> Itraconazole is thought to be less toxic than amphotericin B, but its safety in most companion bird species has not been established. Itraconazole has been used in waterfowl, shorebirds, poultry and penguins without serious side effects.<sup>15,54</sup> Anorexia, vomiting and depression have been reported in an African Grey Parrot being treated with itraconazole.<sup>38</sup> Monitoring for anorexia and depression is recommended. Enilconazole also has good efficacy against *Aspergillus* sp., although not as great as itraconazole.<sup>54</sup> Miconazole and parconazole may be less efficacious than other azoles in treating aspergillosis.

**TABLE 35.5 Suggested Concurrent Therapy for Advanced Aspergillosis**

Amphotericin B – IV and/or IT or in the affected air sac – BID for 5 days
Ketoconazole – orally – TID for 10 days
Flucytosine – orally – TID for 20 to 30 days
Kapracidin A – orally – TID for 5 days

Immunization therapy has been suggested to be of value in stimulating host response to *Aspergillus*

spp. although information on the success of this treatment is still limited. Levamisole therapy has been suggested as an immunostimulant, but its efficacy is unknown.<sup>5</sup>

### Control

Prevention of aspergillosis in general is dependent on the reduction of predisposing stress factors. Limiting exposure may be accomplished by reducing contact with organic bedding or nesting material that may be contaminated with mold or spores. Careful cleansing and disinfection of hatching equipment is essential. Feed for companion and aviary birds should always be free of fungal growth in order to limit exposure to fungal pathogens and mycotoxins (see Chapter 37). Vaccination with an autogenous mycotin may be effective in reducing aspergillosis in susceptible species such as captive penguins and waterfowl.<sup>57</sup>

### Cryptococcosis

*Cryptococcus neoformans* is an imperfect, saprophytic yeast that has been reported as a cause of disease in psittacine birds and pigeons.<sup>9,14,43</sup> The transmission and pathogenesis in birds is largely unknown, but it is isolated frequently from the droppings of pigeons. In gallinaceous birds, cryptococcosis has been described as a necrotic granulomatous disease of the intestines, liver, lungs and spleen. In companion birds, a diagnosis of cryptococcosis is usually made at postmortem.

Antemortem diagnosis of cryptococcosis may be challenging. An impression smear of any accessible gelatinous material may reveal the characteristic encapsulated yeast-like organism. A latex agglutination antibody titer may be elevated in an exposed or infected bird.<sup>41</sup>

Central nervous system signs in birds with gelatinous masses should be considered suspicious. A Moluccan Cockatoo with disseminated cryptococcosis was presented for diarrhea and blindness; gelatinous material was present in the long bones, respiratory spaces and abdominal cavity.<sup>14</sup> In another case of cryptococcosis, a Green-winged Macaw was presented for diarrhea and paralysis.<sup>9</sup>

Dyspnea, weight loss and anemia are frequent clinical signs, and heterophilia may or may not be present.<sup>43</sup> The clinician should exercise caution when being exposed to clinical material that may contain *C. neoformans* spores.



The prognosis for disseminated cryptococcosis is poor. Amphotericin B and ketoconazole have been suggested as possible therapies.<sup>43</sup> In humans, amphotericin B, flucytosine and rifampin are sometimes effective. Cryptococcosis is a potentially serious zoonosis and may occur when humans inhale dust from the dried droppings of pigeons, starlings or other avian species.<sup>9,56</sup> Other transmission routes may also be possible. Respiratory signs, encephalitis or meningitis may occur; the outcome is frequently fatal. Treating cryptococcus cases should be carefully considered given the zoonotic potential for this organism.

### ■ Histoplasmosis

Histoplasmosis is similar to cryptococcosis in many ways but is less commonly reported in birds. *Histoplasma capsulatum* is an infectious but not contagious disease of the reticuloendothelial system. *Histoplasma* spp. grow readily in soil and appear as a white-to-brown mold with two types of spores.<sup>6</sup> The organism has been associated with or found in the feces of chickens, blackbirds, pigeons and gulls.<sup>41</sup> This fungus could potentially proliferate in enclosed aviaries with dirt floors. Surveys of aviary soil are needed to determine the incidence of this organism. The transmission and incubation periods are unknown, but in experimental situations, the organism can be recovered from the liver and spleen 7 to 45 days after intravenous inoculation.

Diagnosis of histoplasmosis is based on culture of the organism (mycelial phase may sometimes be recovered on Sabouraud's agar) and histopathology (periodic acid-Schiff, Bauer's and Gridley stains).<sup>6</sup>

*Histoplasma* sp. has zoonotic potential and may cause pneumonitis that progresses to a disseminated disease of the reticuloendothelial system.

## Uncommon Fungal Diseases

Dermatophytosis, mucormycosis, trichosporosis, rhinosporidiosis and penicilliosis have all been documented in avian species. Dermatophyte infections are of some interest to the avian practitioner because of their role in skin and feather abnormalities. While

frequently implicated, fungal infections of the skin in psittacine birds have rarely been documented.

*Trichophyton gallinae* is the principal dermatophyte of gallinaceous species, and is associated with a white crust on the comb and wattles ("fowl favus") (see Color 8). *Trichophyton* sp. has been documented as a cause of dermatologic problems in the duck, pigeon and canary.<sup>5,41,52</sup> Diagnosis of fungal skin infections is usually made with cytologic evaluation of wet mounts or Gram's-stained smears, culture (canine and feline dermatophyte media for in-hospital use may not be suitable) and biopsy (histopathology). Topical treatment with antifungal creams is recommended, with attention to any underlying stress factors. *Trichophyton gallinae* is a zoonotic disease and has been described as a pruritic, scaly lesion of the scalp.<sup>51</sup>

Mucormycosis is a term that includes a variety of fungal pathogens. In birds, disease caused by *Rhizopus* and *Mucor* spp. have been reported. Granulomas of the gut and ventriculus were found in a group of canaries that were being fed sprouted seed; concurrent antibiotic treatment may have been a predisposing factor.<sup>39,53</sup> Infections caused by members of the phycomycetales (zygomycota) can sometimes mimic aspergillosis (eg, tracheal obstruction, mycelial granulomas).

Systemic trichosporosis was reported in a Green-winged Macaw that was presented for weight loss and polyuria. Granulomatous inflammation involving the liver, myocardium and lung was associated with *Trichosporon beigeli*.<sup>50</sup> *Penicillium griseofulvum* is another rare fungal isolate that caused a systemic infection in a group of captive toucanets.<sup>1</sup> Septate, branched mycelia were found in the lungs, air sacs and liver. Conidiophores and conidial chains were present in the air sacs. Nocardiosis (*Nocardia asteroides*) involving the lungs and air sacs of two Pesquet Parrots has been reported.<sup>5</sup>

Rhinosporidiosis seems to be found most frequently in birds living in aquatic habitats. It has been documented in ducks and geese but not in Psittaciformes or Passeriformes. It also occurs in man and the dog, and in most species it can take the form of an erythematous nasal polyp.<sup>10</sup>

A mycetoma caused by *Curvularia geniculata* was reported in a Grand Eclectus Parrot. Mycetomas in man are eruptions of the extremities that usually involve granuloma formation by one of a number of obscure fungal pathogens.

### Products Mentioned in the Text

- a. DiffQuik, Fisher Scientific, Pittsburgh, PA
- b. Sabouraud's agar, Fisher Scientific, Pittsburgh, PA
- c. Fungizone, E.R. Squibb and Sons Inc., Princeton, NJ
- d. Ancobon, Roche Laboratories, Nutley, NJ
- e. Nizoral, Janssen Pharmaceutical Inc., Piscataway, NJ
- f. Itraconazole, Janssen Pharmaceutical Inc., Piscataway, NY
- g. Diflucan, Reorige Division of Phizer Inc., New York, NY
- h. Mycostatin, E.R. Squibb and Sons Inc., Princeton, NJ

### References and Suggested Reading

1. **Aho R, et al:** Avian penicilliosis caused by *Penicillium griseofulvum* in a captive toucanet. *J Vet & Med Mycol* 28(5):349-354, 1990.
2. **Bauk LB:** Treatment of canine nasal aspergillosis with ketoconazole. *Vet Med Sm Anim Clin* 78(11):1713-1715.
3. **Baumgartner R:** Clinical diagnosis of aspergillosis with the aid of serology. *Proc Assoc Avian Vet*, 1988, pp 61-67.
4. **Beemer AM, Kuttin ES, Katz Z:** Epidemic venereal disease due to *Candida albicans* in geese in Israel. *Avian Dis* 17(3):636-649, 1973.
5. **Campbell TW:** Mycotic diseases. In Harrison GJ, Harrison LR (eds): *Clinical Avian Medicine and Surgery*. Philadelphia, WB Saunders Co, 1986, pp 464-472.
6. **Chute HL:** Fungal diseases. In *Disease of Poultry* (8th ed). Hofstead MS (ed), Iowa State University Press, Ames, 1984, pp 309-320.
7. **Clipsham R:** Fungal proventriculitis in macaws. *J Assoc Avian Vet* 3(2):68, 1989.
8. **Clipsham R:** Pediatric management and medicine. *J Assoc Avian Vet* 3(1):10-13, 1989.
9. **Clipsham R, Britt JO:** Disseminated cryptococcosis in a green-winged macaw. *J Am Vet Med Assoc* 183(11):1303-1304, 1983.
10. **Davidson WR, Nettles VF:** Rhinosporidiosis in a wood duck. *J Am Vet Med Assoc* 171(9):989-990, 1977.
11. **Davidson WR, et al:** Feather damage due to mycotic infections in wild turkeys. *J Wildl Dis* 25(4):534-539, 1989.
12. **Degryse AD, VanCutsem J, Fransen J:** Oral treatment with ketoconazole of plantar candidosis in a mute swan. *J Sm Anim Pract* 26(10):619-624, 1985.
13. **Erer H, Sezen IY, Erganis O:** Investigations on aspergillosis in chickens. *Selkuk Universitesi Veteriner Fakultesi Dergisi* 2(1):171-179, 1986.
14. **Fenwick B, Takeshita K, Wong A:** A Moluccan cockatoo with disseminated cryptococcosis. *J Am Vet Med Assoc* 187(11):1210-1212, 1984.
15. **Fransen J, VanCutsem J:** Fungal infections in birds in captivity (synopsis). *AAV Today* 2(1):15, 1988.
16. **Frazer CM, et al (eds):** Diseases of poultry. Merck Veterinary Manual 7th ed. Rahway, Merck & Co, 1991, p 1562.
17. **Goodman G, Widenmeyer JC:** Systemic *Candida parapsilosis* in a 20-year-old Blue-fronted Amazon. *Proc Assoc Avian Vet*, 1986, pp 105-119.
18. **Greenacre CB, Latimer KS, Ritchie BW:** Leg paresis in a black palm cockatoo caused by aspergillosis. *J Zoo & Wildlife Med* 23(1), 1992.
19. **Harrison GJ:** Candida air sacculitis (radiographic self-assessment). *AAV Today* 2(4):202, 1988.
20. **Hines RS, Sharkey P, Friday RB:** Itraconazole treatment of pulmonary, ocular and uropygial aspergillosis and candidiasis in birds. *Proc Am Assoc Zoo Vet*, 1990, pp 322-326.
21. **Hubbard GB, et al:** Fungal infection of ventriculi in captive birds. *J Wildl Dis* 21(1):25-28, 1985.
22. **Jenkins JR:** Aspergillosis. *Proc Assoc Avian Vet*, 1991, pp 328-330.
23. **Joyner KL:** Pediatric therapeutics. *Proc Assoc Avian Vet*, 1991, pp 188-199.
24. **Kaplan W, et al:** Fatal aspergillosis in imported parrots. *Mycopathologica* 56(1):25-29, 1975.
25. **Kaufman GE:** Enilconazole treatment of fungal rhinitis in an African grey parrot. *Proc Am Assoc Zoo Vet/Am Assoc Wildlife Vet*, 1988.
26. **Kallias GV:** The use of ketoconazole in birds. *Proc Assoc Avian Vet*, 1986, pp 103-104.
27. **Lane R:** Use of Gram's stain for bacterial screening. *J Assoc Avian Vet* 4(4):214-217, 1990.
28. **Marius-Jestin V, et al:** Etiology of the venereal disease of the gander. *Recl Med Vet ED Alfort* 163(6,7):645-654, 1987.
29. **McDonald SE, Messenger GA:** Successful treatment of mycotic tracheitis in a raven. *Proc Assoc Avian Vet*, 1984, pp 155-163.
30. **McMillan MC, Petrak ML:** Aspergillosis in pet birds: A review of 45 cases. *Proc Assoc Avian Vet*, 1988, pp 35-45.
31. **Panigrahy B, et al:** Candidiasis in cockatiel nestlings and mucormycosis in a pigeon. *Avian Dis* 23(3):757-760, 1979.
32. **Parrott T:** Flock treatments. *J Assoc Avian Vet* 5(1):47, 1991.
33. **Parrott T:** Clinical treatment regimens with fluconazole. *Proc Assoc Avian Vet*, 1991, pp 15-19.
34. **Patgiri GP:** Systemic mycoses. In Burr EW (ed): *Companion Bird Medicine*. Ames, Iowa State University Press, 1987, pp 102-106.
35. **Perez A:** Canaries: Systemic candidosis. *Veterinaria Argentina* 2(12):186-189, 1985.
36. **Perry RA:** Avian dermatology. In Burr EW (ed): *Companion Bird Medicine*. Ames, Iowa State University Press, 1987, pp 40-50.
37. **Pokras MA:** Captive management of aquatic birds. *AAV Today* 2(1):24-33, 1988.
38. **Quesenberry K, et al:** Roundtable discussion: clinical therapy. *J Assoc Avian Vet* 5(4):186-191, 1992.
39. **Reavill DR, Schmidt RE, Fudge AM:** Avian skin and feather disorders: A retrospective study. *Proc Assoc Avian Vet*, 1990, pp 248-253.
40. **Redig PT:** Mycotic infections of birds of prey. In Fowler ME (ed): *Zoo and Wild Animal Medicine*. Philadelphia, WB Saunders Co, 1978, pp 273-290.
41. **Ritchie BW, Dreesen DW:** Avian zoonoses: Proven and potential diseases, part II. *Comp Cont Ed* 10(6):688-696, 1988.
42. **Ritchie BW:** Avian therapeutics. *Proc Assoc Avian Vet*, 1990, pp 415-430.
43. **Roskopf WJ, Woerpel RW:** Cryptococcosis in a thick-billed parrot. *Proc Assoc Avian Vet*, 1984, pp 281-288.
44. **Roskopf WJ, et al:** Successful treatment of aspergillosis in two psittacine birds. *Proc Assoc Avian Vet*, 1986, pp 119-128.
45. **Roskopf WJ:** Therapeutic agents for raptors. *AAV Today* 1(4):146, 1987.
46. **Roskopf WJ, Woerpel RW:** Psittacine conditions and syndromes. *Proc Assoc Avian Vet*, 1990, pp 432-459.
47. **Sharp NJH, Sullovan M:** Use of ketoconazole in the treatment of canine nasal aspergillosis. *J Am Vet Med Assoc* 194(6):782-786, 1989.
48. **Smith RE:** Avian diseases that antibiotics won't cure. *AAV Today* 1(2):69-70, 1987.
49. **Stroud RK, Duncan RM:** Occlusion of the syrinx as a manifestation of aspergillosis in Canada geese. *J Am Vet Med Assoc* 181(11):1389-1390, 1982.
50. **Taylor M:** Systemic trichosporonosis in a green-winged macaw. *Proc Assoc Avian Vet*, 1988, pp 219-220.
51. **Torres G, Georg IK:** A human case of *Trichophyton gallinae* infection. *AMA Arch of Derm*: 191-197, 1956.
52. **Tudor DC:** Mycotic infections of feathers as a cause of feather pulling in pigeons and psittacine birds. *Vet Med Sm Anim Clin* 78(2):249-253, 1983.
53. **VanCutsem J:** Experimental fungal diseases and treatment (synopsis). *AAV Today* 2(1):15, 1988.
54. **VanCutsem J, Vangerven F, Janssen PA:** The treatment of experimental aspergillosis with enilconazole and itraconazole. *Bull Soc Fr Mycol Med* 18(1):55-60, 1989.
55. **Vandermaast H, Dorrestein GM, Westerhof J:** A fatal treatment of sinusitis in an African grey parrot. *J Assoc Avian Vet* 4(3):189, 1990.
56. **Wolf AM:** Systemic mycoses. *J Am Vet Med Assoc* 194(9):1192-1196, 1989.
57. **Yearout DR:** Prevention and treatment of aspergillosis by vaccination. *Proc Assoc Avian Vet*, 1988, pp 139-143.