

CHAPTER

# 15

## SUPPORTIVE CARE AND EMERGENCY THERAPY

■  
Katherine E. Quesenberry  
Elizabeth V. Hillyer

**K**nowledge of the principles and techniques of supportive care and emergency medicine is necessary for the successful medical management of avian patients. The basic concepts of emergency and supportive care of small animal medicine apply to birds, but modifications must be made to compensate for their unique anatomy and physiology. Supportive care including fluid therapy, nutritional support, and heat and oxygen supplementation is critical to both emergency and maintenance therapy.

Emergencies of many different types are seen in avian medicine. A common emergency is the extremely debilitated, cachectic, chronically ill bird that is too weak to perch or eat. Because certain syndromes are more common in certain species and at certain ages, the signalment of the bird is helpful in establishing a rule-out list. Recently obtained birds frequently present with acute infectious problems, including chlamydiosis and viral diseases.

Neonates that are being hand-fed commonly suffer from management-related problems (eg, crop burns, nutritional deficiencies) and certain fungal, bacterial and viral diseases such as candidiasis, gram-negative ingluvitis and avian polyomavirus. Birds that are long-term companion animals are more likely to have chronic infectious diseases such as aspergillosis, chronic nutritional diseases or toxicities. Egg binding and egg-related peritonitis frequently occur in companion budgerigars and cockatiels. Aviary birds can have a variety of infectious, metabolic, toxic and nutritional problems. Traumatic emergencies are common in all types of birds.

Critically sick or injured birds are often too weak for an extensive examination when first presented. Birds that are on the bottom of the cage and dyspneic need immediate medical attention with an organized, efficient approach to stabilization therapy. Physical examination, diagnostic tests and treatments should be performed in intermittent steps to decrease restraint periods and reduce stress.

## Emergency Stabilization

Although each bird should be evaluated individually, some basic guidelines for emergency diagnostic testing and treatment can be followed. The bird should be observed carefully in its enclosure before handling, to assess the depth and rate of breathing. Birds with airway obstruction or severe respiratory disease are usually extremely dyspneic. Birds that are septicemic, in shock or weak from chronic disease may also have labored breathing. If respiration is rapid or difficult, the bird should be placed immediately in an oxygen cage. This is usually less stressful than using a face mask, especially if the bird is refractory to restraint. While the bird is allowed to stabilize, a complete history can be obtained from the owner, and a diagnostic and therapeutic plan based on the history, clinical signs and the initial physical findings can be formulated.

If the bird can be weighed without undue stress, an accurate pretreatment weight should be obtained. Otherwise, drug dosages are calculated based on an estimate of the body weight for the species (see Chapter 30). The most important treatments must be given first. If the bird shows any signs of stress during restraint, it may be placed back in oxygen or in a quiet enclosure until it is stable. Alternatively, the bird can be given oxygen by face mask while treatments are administered.

Some veterinarians prefer to use isoflurane anesthesia when treating very weak, dyspneic or fractious birds. For gradual induction in critically ill patients, low isoflurane concentrations (0.25%) are slowly increased to 1.5% or 2.5% over two to five minutes. Once the bird is anesthetized, lower maintenance concentrations (0.75% to 2%) can be used. Birds can be maintained with a face mask or intubated.

The use of anesthesia allows several procedures to be performed within a few minutes, including collection of a blood sample, placement of a catheter or air sac tube and radiographs. For each bird, the risk of anesthesia must be considered and weighed against the risks of stress associated with manual restraint. If anesthesia is chosen for restraint, the episode should be of short duration and the bird must be carefully monitored.

Pretreatment blood samples are valuable if appropriate to obtain. If intravenous fluids are given, a sample can be obtained through a butterfly catheter in the jugular vein immediately before fluid administration. The bird should be evaluated for anemia before blood is withdrawn. If the conjunctiva and mucous membranes appear pale, the packed cell volume (PCV) should be determined by taking a small blood sample from a toenail clip. If the PCV is 15% or less, collecting blood for a full biochemistry analysis or complete blood count can be life-threatening. Collecting a pretreatment blood sample is usually too stressful in extremely dyspneic birds unless anesthesia is used for restraint.

While the bird is resting after the initial treatments, necessary diagnostic samples collected during the restraint period (eg, fecal or crop cultures, chlamydia test, blood work) can be evaluated. Radiographs are usually postponed until the bird is stable. If radiographs are essential for establishing a correct diagnosis and initiating treatment, isoflurane anesthesia can be used to ensure that diagnostic radiographs are safely obtained.

### Fluid Replacement Therapy

#### Fluid Requirements

The daily maintenance fluid requirement for raptors and psittacine birds has been estimated at 50 ml/kg/day (5% of the body weight).<sup>42</sup> This estimate is appropriate clinically for most companion and aviary bird species. However, water consumption may vary from 5 to 30% of body weight per day in many free-ranging species. The amount of water needed is generally inversely related to body size<sup>3</sup> and can also vary according to age, reproductive status, dietary intake and the type of foods consumed (Table 15.1).

**TABLE 15.1** Variance in Water Intake

Adult chickens	5.5%	bw/day <sup>15</sup>
Cockatiels	5-8%	bw/day
Growing chickens	18-20%	bw/day
Laying hens	13.6%	bw/day <sup>63</sup>

An estimate of hydration status is based on the clinical signs and history. The turgescence, filling time and luminal volume of the ulnar vein and artery are good indicators of hydration status.<sup>1</sup> A filling time of greater than one to two seconds in the ulnar vein indicates dehydration greater than seven percent. Severely dehydrated birds (ten percent) may have

sunken eyes and tacky mucous membranes. The skin of the eyelids may tent when pinched.

As for mammals, anemia or hypoproteinemia can affect the accuracy of a PCV or total solids in detecting dehydration (Table 15.2).

**TABLE 15.2 Findings with Dehydration**<sup>31,33</sup>

Increased PCV	15 to 30%
Increased total solids	20 to 40%
Increased plasma urea	6.5 to 15.3 x normal

Changes will vary with the degree of dehydration.

Most birds presented as emergencies have a history of inadequate water intake and can be assumed to be at least five percent dehydrated. An estimation of the fluid deficit can be calculated based on body weight:

$$\text{Estimated dehydration (\%)} \times \text{body weight (grams)} = \text{fluid deficit (ml)}^{18}$$

Half of the total fluid deficit is given over the first 12 to 24 hours along with the daily maintenance fluid requirement. The remaining 50% is divided over the following 48 hours with the daily maintenance fluids.

Lactated Ringer's solution (LRS) or a similar balanced isotonic solution warmed to 100.4° to 102.2°F (38° to 39°C) is recommended for fluid replacement and shock therapy. Using warm fluids is particularly important with neonates and with intravenous or intraosseous administration of fluids for hypothermia or shock.<sup>1</sup>

The exact fluid requirements of birds in shock are difficult to determine. In mammals in septic shock, a fluid volume of 0.5 to 1.5 times the estimated blood volume may be needed to correct peripheral vasoconstriction. Thirty minutes after treatment, only 25% of administered isotonic crystalloid fluids remains in the vascular compartment.<sup>21</sup> The remaining 75% redistributes to the interstitial fluid compartment. Consequently, circulatory improvement may be transient, requiring additional fluid therapy to prevent recurrence of hypotension and vasoconstriction.

As illustrated by this example, hemodilution is the primary limitation to crystalloid fluid therapy, making administration of colloids or blood necessary for effective shock therapy. Synthetic colloid solutions (dextran, hetastarch) have not been used to any extent in birds. These solutions contain large molecules that do not cross the endothelium and remain in the intravascular fluid compartment. Colloid solutions draw fluid from the interstitial fluid compartment

into the intravascular space and are more effective blood volume expanders than crystalloids.<sup>1,21</sup> They are particularly useful in restoring circulating blood volume without aggravating hypoproteinemia or causing pulmonary edema in animals with low oncotic pressure and hypoproteinemia.

There is evidence that hemorrhagic shock does not occur in birds.<sup>64</sup> Severe blood loss is tolerated much better in birds than in mammals, especially in flighted birds. This tolerance is the result of an increased rate of absorption of tissue fluids to replace lost blood volume and baroreceptor reflexes, which maintain normal blood pressure. Prostaglandins, which potentiate shock in mammals, have been shown to have no effect in chickens.

### Route of Fluid Therapy

Supplemental fluids can be given orally, subcutaneously, intravenously or by intraosseous cannula (Figure 15.1). Fluids can be given orally for rehydration and maintenance in birds that are mildly dehydrated. Oral rehydration is often used for waterfowl and other large species in which administration of intravenous or subcutaneous fluids is difficult. In pigeons, administration of an oral five percent dextrose solution has been shown to be more effective for rehydration than oral administration of lactated Ringer's solution.<sup>33</sup> This effect may be the result of glucose causing a more rapid uptake of water from the intestinal tract. Gatorade<sup>®</sup> is used by some veterinarians for oral rehydration and fluid maintenance. For effective rehydration, oral fluids need to be readministered within 60 to 90 minutes of the first treatment. Mixing oral fluids with ppsyllium<sup>®</sup> may increase fluid and calcium absorption from the intestinal villi. Oral fluids should not be given to birds that are seizing, laterally recumbent, regurgitating, in shock or have gastrointestinal stasis.

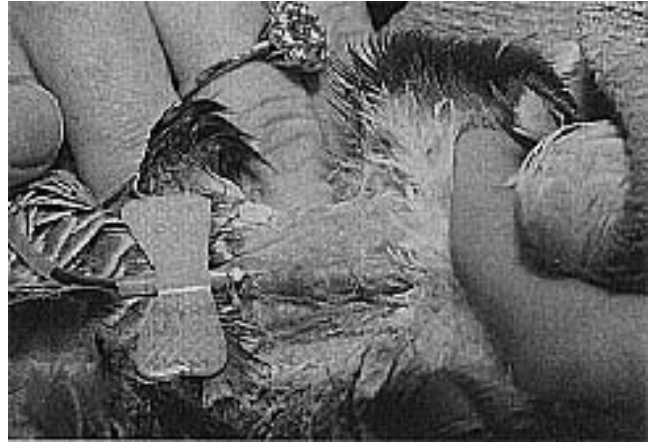
Subcutaneous administration is used primarily for maintenance fluid therapy. The axilla and lateral flank areas are commonly used for injection. The intrascapular area is preferred by some clinicians in young birds that may be difficult to restrain for flank injection. The area around the neck base should be avoided because of the extensive communications of the cervicocephalic air sac system. A small (25 to 27 ga) needle is used to prevent fluids from leaking from the injection site. The total volume of fluids should be given in several sites (5 to 10 ml/kg/site) to prevent disruption of blood flow and subsequent poor absorption.<sup>1</sup> Subcutaneous fluids are less effective than intravenous or intraosseous fluids for shock therapy



**FIG 15.1** Subcutaneous fluids can be administered in the lateral flank, axilla or intrascapular region (shown here) in cases of mild dehydration (five percent) to provide maintenance fluids. The area of the base of the neck should be avoided because of the cervicocephalic air sacs. Subcutaneous fluids are generally ineffective in cases of severe dehydration or shock.

because of peripheral vasoconstriction. Subcutaneous fluids may pool in the ventral abdominal area causing hypoproteinemia, overhydration or poor absorption. If ventral abdominal edema is noted, subcutaneous fluid administration should be decreased or discontinued.

Intravenous fluids are necessary in cases of shock to facilitate rapid rehydration. Intraosseous cannulas or use of the right jugular vein are the best access points to the peripheral circulation. Dyspneic birds and those with distended, fluid-filled crops should be carefully handled to prevent regurgitation and aspiration. Injection of a large fluid volume into the ulnar or metatarsal veins is difficult and frequently results in hematoma formation.



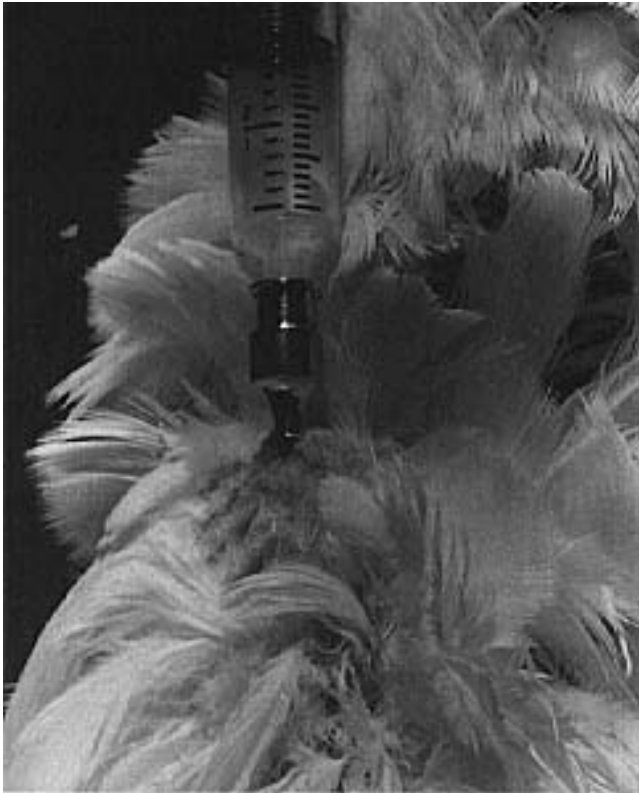**FIG 15.2** IV fluids and drugs can be slowly administered through a butterfly catheter in the right jugular vein. The biggest disadvantage to this technique is that fluids should not be given faster than 10 ml/kg over a five- to seven-minute period necessitating prolonged restraint for fluid administration (courtesy of Kathy Quesenberry).

A butterfly catheter (25 ga) with 3.5-inch tubing is ideal for fluid administration in medium-sized to large birds (Figure 15.2). A 27 ga needle can be used in small birds. The catheter allows pretreatment blood collection and “slow” administration of fluids, antibiotics or other medications with one venipuncture. Drug dosages and fluids should be prepared before the bird is restrained.

The amount of fluid that can be administered at one time depends on the size of the bird. Injections of ten ml/kg given slowly over five to seven minutes are usually well tolerated.<sup>1</sup> The bolus injections can be repeated every three to four hours for the first twelve hours, every eight hours for the next 48 hours, and then BID.<sup>18</sup>

Intravenous catheters (24 ga in medium to large birds) can be placed in the ulnar or medial metatarsal veins of some birds for continuous fluid administration. For placement in the ulnar vein, the catheter is inserted using sterile technique, secured loosely with elastic tape<sup>24</sup> and fixed in place using a tongue depressor that extends 1.5 inches beyond the catheter end. Both the proximal and distal ends of the tongue depressor are then firmly incorporated in a wing wrap to stabilize the catheter.<sup>5</sup> The risk of hematoma formation is probably greater using the ulnar vein than with the metatarsal vein.

Maintenance of an IV catheter can be difficult. Many birds will chew at the catheter, tape or extension set tubing.



**FIG 15.3** A mature Umbrella Cockatoo was presented with a two-day history of vomiting and profuse diarrhea. The bird was estimated to be ten percent dehydrated (reduced ulnar refill time, tacky mucous membranes, dull sunken eyes). PCV=28 and TP=6.8. An intraosseous catheter was placed in the ulna and the bird was given warm LRS using an infusion pump. The clinical response to rehydration was dramatic. The bird had destroyed a plastic cup the day before clinical signs started. Large pieces of plastic were flushed out of the proventriculus by gastric lavage using warm LRS.

An intraosseous cannula can be used for administration of fluids, blood, antimicrobials, parenteral nutritional supplements, colloids, glucose and drugs used for cardiovascular resuscitation in birds.<sup>36</sup> Administration of hypertonic or alkaline solutions can be painful and should be avoided. The advantages of intraosseous cannulas include the ease of placement and maintenance, cannula stability, tolerance by most birds and reduced patient restraint once the cannula is placed. Continuous fluid administration by intraosseous cannula is less stressful than repeated venipunctures.

It has been shown in pigeons that 50% of the fluids administered in the ulna enters the systemic circulation within 30 seconds.<sup>30</sup> Over a two-hour period, the flow into the systemic circulation was almost equivalent to the administration rate.

Intraosseous cannulas can be placed in any bone with a rich marrow cavity.<sup>36</sup> A cannula may be placed in the distal ulna in medium-sized to large birds that will require several days of therapy (Figure 15.3). The proximal tibia is ideal in birds that will require shorter terms of therapy. Pneumatic bones such as the humerus and femur cannot be used. Isoflurane anesthesia is sometimes necessary for cannula placement in fractious birds. In medium-sized or larger birds, an 18 to 22 ga, 1.5 to 2.5 inch spinal needle<sup>v</sup> can be used as the cannula. In smaller birds, a 25 to 30 ga hypodermic needle is used.

For placement in the ulna, the feathers from the distal carpus are removed and the area is aseptically prepared. Using sterile technique, the needle is introduced into the center of the distal end of the ulna parallel to the median plane of the bone (Figure 15.4).<sup>46</sup> The entry site is ventral to the dorsal condyle of the distal ulna (Figure 15.4). The needle is advanced into the medullary cavity by applying pressure with a slight rotating motion. The needle should advance easily with little resistance once the cortex is penetrated. If resistance is encountered, the needle may have entered the lateral cortex. When seated correctly, a small amount of bone marrow can be aspirated through the cannula. This aspirate can be submitted for bone marrow analysis if desired. The

## CLINICAL APPLICATIONS

### Fluid Therapy Considerations

#### Oral Fluids

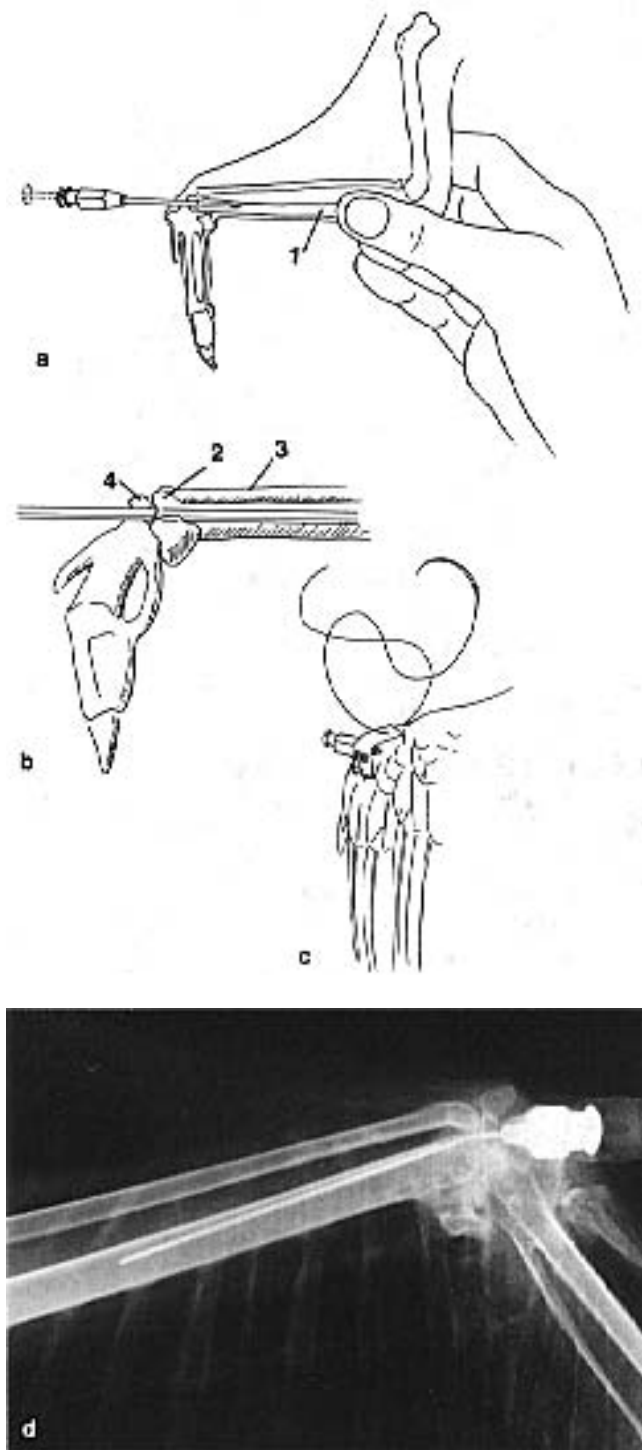
- Only effective with mild dehydration
- 5% dextrose may be better than lactated Ringer's solution
- Contraindicated with GI stasis
- Contraindicated with lateral recumbency
- Contraindicated with seizing and head trauma
- Ineffective for shock

#### Subcutaneous Fluids

- Primarily used for mild dehydration
- Effective for providing maintenance fluids
- Given in axilla or lateral flank
- Divide dose among several sites

#### Intravenous or Intraosseous Fluids

- Rapidly expands circulatory volume
- Rapidly perfuses kidneys
- Indicated in shock
- Indicated with severe dehydration
- Right jugular vein - one time use
- Medial metatarsal vein - one time use
- Tibial intraosseous cannula - one time use



**FIG 15.4** Technique for placing an intraosseous cannula in the distal ulna. If fluid or drug administration will be restricted to a single dose or a short period (eg, surgery), it is easier to place a catheter in the tibia. An intraosseous catheter placed in the ulna is easier to maintain if several days of continuous IV therapy are necessary. **a)** The thumb is placed in the center of the 1) ulna as a guide. **b)** The cannula is inserted slightly ventral to the 2) dorsal condyle of the distal ulna. The 3) radius and 4) radial carpal bone can be used for orientation. **c)** The cannula is sutured in place. **d)** Radiograph of properly inserted cannula.

cannula should be flushed with a small amount of heparinized saline, which should flow without resistance. Initial fluids should be administered slowly to check for subcutaneous swelling, which would indicate improper placement of the cannula. If the cannula is properly placed, fluid can be visualized passing through the ulnar vein. The cannula is secured in place by wrapping a piece of tape around the end and suturing the tape to the skin or by applying a sterile tissue adhesive<sup>b</sup> at the point of insertion (Figure 15.4). A gauze pad with a small amount of antibacterial ointment is placed around the cannula at the insertion site, and a figure-of-eight bandage is used to secure the wing. One to two loops of the extension tube should be incorporated into the bandage to decrease tension on the cannula.

Tibial cannulas are seated in the tibial crest and passed distally, similar to the technique used for obtaining a bone marrow aspirate. A light padded bandage or lateral splint is used to secure the cannula in place (see Figure 39.5).

Fluids are administered through the cannula using an infusion pump, buretrol<sup>c</sup> or Control-a-Flow regulator.<sup>d</sup> Unlike a vein, the marrow cavity cannot expand to accommodate rapid infusions of large fluid volumes. Consequently the rate of infusion into the marrow cavity is limited. The ideal infusion rate to avoid fluid extravasation in birds is unknown. In small mammals, fluids can be given at shock doses (90 ml/kg) at a pressurized flow rate of 2 l/hr.<sup>36</sup> Clinically, infusion rates in birds for shock therapy should probably be much lower. A flow rate of ten ml/kg/hr is suggested for maintenance. Excessively rapid infusion of the fluids may cause signs of discomfort or edema of the soft tissue in the area of the cannula. Fluid extravasation may occur if the infused volume is too large, or if several holes were made in the cortex while attempting to place the cannula.

Intraosseous cannulas are most successful in birds if used during the first 24 to 48 hours for initial rehydration and shock therapy. Cannulas can remain in place for up to 72 hours without complications if placed aseptically and maintained with heparinized flushings every six hours.<sup>36</sup> Clinically, after two to three days of use, many birds exhibit a painful response when fluids are given through an intraosseous cannula. This could result from pain associated with local edema or the extravasation of fluids around the marrow cavity. Some birds will not tolerate the cannula and will bite at the extension tubing or the wrap as their general condition improves.

The use of vascular access devices (VAD) in birds has recently been described.<sup>20</sup> A vascular access device consists of a catheter that is placed within a vessel, and a port that is implanted in the subcutaneous tissue. No portion of the catheter is externally exposed, reducing the incidence of bacterial contamination and infection. A specially designed needle (Huber needle) is used for access to the depot port by skin penetration. Use of a VAD allows repeated blood sampling and drug administration without repeated venipuncture, with minimal stress on the patient. Vascular access ports are used in humans primarily for long-term intravenous chemotherapy and total parenteral nutrition. More recently, vascular access devices have been used in dogs and laboratory animals.<sup>2,37</sup> Potential complications of the vascular access port include thrombosis, sepsis, local infection and drug extravasation.<sup>2</sup>

Vascular access devices have been used experimentally in pigeons and geese and clinically in an auklet.<sup>20</sup> The use of the device in small birds may be limited by the size of the animal and absence of an appreciable subcutaneous space. Other disadvantages of the device in birds include the necessity of surgical placement and removal and the difficulty of venotomy in small avian patients.

The system is usually implanted with the animal under general anesthesia (see Chapter 41). A skin incision is made over the jugular vein. The vein is isolated and occluded cranially for venotomy and insertion of the catheter. The catheter is secured in place in the vein with sutures above and below a retention ring on the catheter. A tunnel is made through the subcutaneous tissue to a site dorsal to the catheter where the port is sutured to the underlying muscle fascia. The extravascular portion of the catheter is left in a short loop to prevent tension during neck movement. The catheter is flushed with heparinized saline at regular intervals to ensure patency.

### Antibiotics

Septicemia and bacteremia should be considered in any bird that is severely depressed. Prophylactic antibiotics are frequently used in birds that are immunocompromised from a noninfectious disease. Antibiotics are not necessary in all emergencies. Birds with simple closed fractures, uncomplicated heavy metal toxicity, hypocalcemia and other noninfectious problems may not require or benefit from the use of antibiotics. However, in many emergency patients the history and clinical signs are vague and inconclu-

sive, and antibiotics may be indicated on a precautionary basis.

Parenteral antibiotics are recommended for the initial treatment of birds that are weak, sick, debilitated or in shock.<sup>45</sup> General peak plasma concentrations following parenteral drug administration vary with the route: IV = seconds; IM = 30 to 60 minutes; oral = 60 to 120 minutes.

Absorption following oral administration may be erratic in birds that are severely dehydrated, have gastrointestinal stasis or are regurgitating. Intravenous administration is recommended if septicemia is a primary concern. Intravenous drugs can be given during the initial fluid bolus or through an indwelling or intraosseous cannula. Intravenous drugs should be given slowly to avoid circulatory shock.

Intramuscular administration of antibiotics is used routinely for maintenance therapy. A small gauge needle (26 to 30 ga) is used to minimize muscle trauma. The pectoral muscles should be used for most injections (see Chapter 17).

The major disadvantage to intramuscular injection is the potential for muscle damage. In a study using hens, eight of thirteen injectable antibiotic preparations caused muscle necrosis, with the most severe damage being induced by tetracyclines and sulfonamides. Muscle damage was a common sequela to IM injections of almost 50 different medications in budgerigars.<sup>13</sup>

Subcutaneous administration of drugs is less traumatic to the muscle and is often used for maintenance therapy. Subcutaneous injections may be preferred in very small or cachectic birds with limited muscle mass and in birds with suspected coagulopathies. Disadvantages of subcutaneous injections include the possibility of leakage from the injection site and poor absorption.

The initial choice of an antibiotic depends on the clinical signs and history of the bird. Birds with suspected gram-negative septicemia should be treated with a bactericidal antibiotic effective against the most common avian pathogens, including *Escherichia coli*, *Enterobacter* spp., *Klebsiella* spp. and *Pseudomonas* spp.<sup>45</sup> Antibiotics commonly used for initial treatment of septicemia include piperacillin, cefotaxime, enrofloxacin, trimethoprim-sulfa, doxycycline and amikacin (see Chapters 17 and 18).

If chlamydiosis is suspected, the bird should be treated with a parenteral doxycycline to rapidly establish therapeutic blood concentrations and stop the shedding of the organism. After initial parenteral therapy (IV doxycycline in the United States,<sup>e</sup> IM doxycycline in the rest of the world<sup>f</sup>), the patient can be switched to oral medication for continued therapy (see Chapter 34).

### Other Drug Therapy

Severe metabolic acidosis is common in mammals that are in shock or that are critically ill. In mammals in hemorrhagic shock, acidosis occurs secondary to inadequate tissue perfusion; however, acidosis has not been shown to occur in chickens following prolonged hemorrhage.<sup>64</sup> Bicarbonate replacement therapy has been recommended in birds if severe metabolic acidosis is suspected, but because it is not usually feasible to measure blood gases in birds, bicarbonate deficit must be estimated.<sup>18</sup> A dose of 1 mEq/kg given IV at 15- to 30-minute intervals to a maximum of 4 mEq has been recommended.<sup>42</sup> In small animals, bicarbonate must be administered slowly IV over 20 minutes or longer.<sup>21</sup> If administered too rapidly or given in excessive amounts, alkalemia, hypercapnia, hypocalcemia, hypernatremia, hyperosmolality, hypokalemia and paradoxical CNS acidosis may occur.<sup>65</sup> The result may be vomiting, hypotension or death.

Stress causes release of catecholamines, which have hyperglycemic effects. Consequently, birds with traumatic wounds or chronic, non-septic diseases may have normal to increased blood glucose concentrations and do not need initial supplemental glucose. Hypoglycemia is most common in sick hand-fed babies, septicemic birds, raptors or extremely cachectic birds in which body stores of glycogen have been depleted. In birds that have been determined to be hypoglycemic, an IV bolus of 50% dextrose at 2 cc/kg body weight can be given with fluids to restore blood glucose concentrations. Glucose can then be added to maintenance fluids in a 2.5% to 10% solution given intravenously or intraosseously. Intramuscular injections of hyperosmotic (75%) dextrose should not be given, because severe muscle irritation and necrosis can result.

Birds that are on poor diets or are chronically ill should receive a parenteral multivitamin on initial hospitalization. Vitamin A and D<sub>3</sub>U should be administered with care in patients on formulated diets to prevent toxicities from over-supplementation. Vita-

min B complex is suggested both initially and on a daily basis in anorectic or anemic birds. Iron dextran therapy is also recommended in anemic birds. Vitamin K<sub>1</sub> will improve clotting time and is important in birds with suspected hepatopathies or birds that may require surgery. Vitamin E and selenium should be considered in patients that have neuromuscular disease. Supplementation of calcium and iodine may be indicated in some cases.

Recently an injectable amino acid supplement<sup>h</sup> has been marketed for use in birds. The product has been recommended for use as an immune stimulant and a nutritional supplement in anorectic and compromised birds. Although no scientific studies have been conducted, some veterinarians report improvement in birds after using this product at recommended doses, and no detrimental side effects have been reported.

### Corticosteroids

The use of corticosteroids in the treatment of shock is controversial. Shock is a very complex disease with many complicating factors, making it difficult to compare treatment results in clinical studies. In humans, there are numerous conflicting studies comparing mortality and reversal of shock in corticosteroid- versus non-corticosteroid-treated groups. Experimentally, pharmacologic doses of steroids have anti-shock effects in laboratory animals. These include improved microcirculation, organelle and cell membrane stabilization, improved cellular metabolism and gluconeogenesis and decreased production of endogenous toxins.<sup>21</sup> Hydrocortisone, prednisolone, methylprednisolone and dexamethasone are recommended in the treatment of hypovolemic and septic shock. There is no definitive evidence of one drug being superior to another.

Complications of steroid use include immunosuppression, adrenal suppression, delayed wound healing and gastrointestinal ulceration and bleeding. Except for immunosuppression, which may occur with one dose of dexamethasone, other negative side effects are primarily associated with chronic therapy using high dosages.

Prednisolone or dexamethasone are used routinely for central nervous system injuries in animals. Methylprednisolone sodium succinate (MPSS) has been shown to improve recovery in humans and cats with spinal cord injuries.<sup>7,8</sup> Dexamethasone was no better than a placebo in improving neurologic signs.<sup>8</sup> The beneficial effects of MPSS are primarily attributed to



the antioxidant effects in protecting cell membranes from lipid peroxidation. It was also found that improvement was strictly dose-dependent. The optimal dose was 30 mg/kg IV in cats and mice. Lower or higher dosages were ineffective or even promoted further lipid peroxidation. In mice, prednisolone sodium succinate was found to be equally efficacious, but half as potent, as MPSS when given five minutes after concussive head injury. Hydrocortisone was ineffective even at high dosages.

There are few studies detailing corticosteroid use in birds. In Red-tailed Hawks and Barred Owls, both intravenous and intramuscular injections of dexamethasone (3 mg/kg) produced peak plasma concentrations within 15 minutes of injection.<sup>9</sup> Intravenous injections resulted in a higher peak concentration. Serum half-life of dexamethasone varied with the species and was found to be 37.5 minutes in Red-tailed Hawks, 53.5 minutes in Barred Owls and 36 minutes in male broiler chickens.<sup>4</sup> Suppression of plasma corticosterone concentrations lasted for 24 hours in owls and for 18 hours in hawks following single-dose administration. Intramuscular injection of dexamethasone sodium phosphate (4 mg/kg) in Red-tailed Hawks was associated with elevations in AST and ALT. Elevations were 3.2 times normal values within 36 hours of single-dose administration.<sup>26</sup> No elevations in AST or ALT were seen following IV administration.

Corticosteroids are used in birds in the treatment of shock, acute trauma and toxicities. Clinically, birds receiving corticosteroids for head trauma and shock therapy seem to improve; however, clinical improvement may result from supportive care and fluid therapy rather than corticosteroid use.

Secondary fungal and bacterial infections are common in birds receiving steroids for longer than one week.<sup>24</sup> These findings suggest that birds are very susceptible to the immunosuppressive effects of corticosteroids; therefore, corticosteroids should be used in birds on an infrequent, short-term basis.

### Nebulization

Nebulization therapy may be beneficial in birds with bacterial or fungal respiratory infections, particularly those limited to the upper respiratory system (see Chapter 22). Air sacculitis is frequently associated with the accumulation of inflammatory cells and pathogenic organisms. The caudal thoracic and abdominal air sacs are more commonly involved, prob-

ably as a result of the directional air flow within the respiratory system.

The air sac wall consists of a thin layer of simple squamous epithelial cells supported by a small amount of connective tissue. Blood supply is extremely limited, and parenteral and oral antimicrobials that depend on the circulatory system for tissue distribution are ineffective in treatment of air sacculitis.<sup>27</sup> In effect, nebulization provides topical, localized treatment of the internal air sacs and is not dependent on absorption (see Chapter 22). Because of the anatomy of the avian respiratory tract and the lack of physical activity in the sick bird, nebulized drugs probably reach only 20% of the lung tissue and the caudal thoracic and abdominal air sacs.<sup>13</sup>

The particle size of nebulized medications must be less than 3  $\mu\text{m}$  to establish local drug levels in the lungs and air sacs.<sup>13</sup> Particles from 3 to 7  $\mu\text{m}$  generally deposit in the trachea and mucosal surface of the nasal cavity.<sup>13,60</sup> Many inexpensive commercial nebulizers do not produce a particle size small enough for penetration of the lower airways. Ultrasonic nebulizers are most effective in producing small particle size and are recommended for use in birds. The tubing and chamber of the nebulizer should be easy to clean after each use, and should be sterilized between birds to avoid introduction of bacterial or fungal organisms with the nebulized solutions.

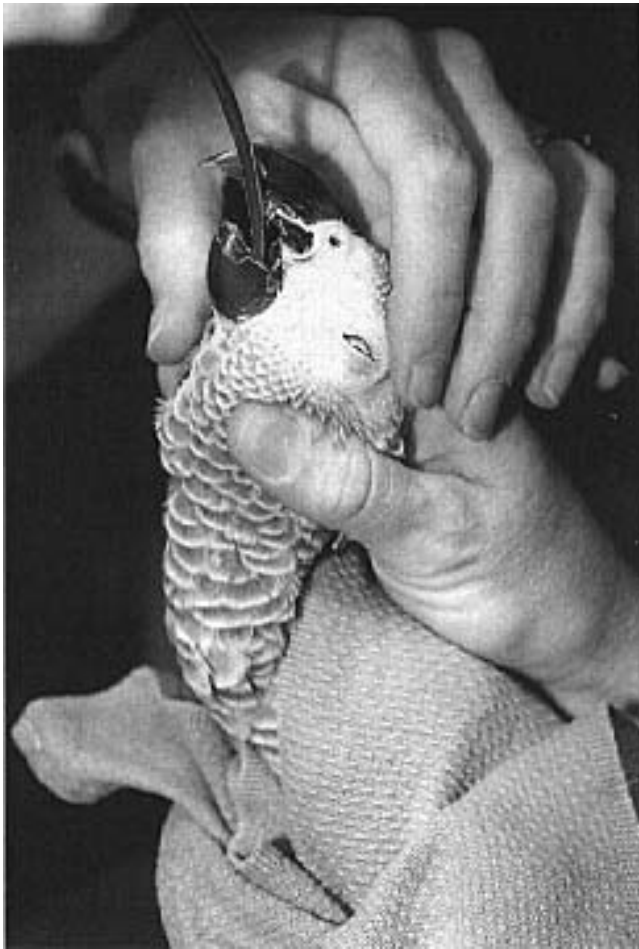In general, most parenteral antibiotics formulated for intravenous use can be used for nebulization. Bactericidal antibiotics appear most successful in nebulization therapy. With air sacculitis caused by an unidentified bacteria, the authors prefer to use cefotaxime (100 mg in saline) or piperacillin (100 mg in saline) for nebulization. The suggested protocol is to nebulize for ten to thirty minutes, two to four times daily for five to seven days.<sup>61</sup> Saline is preferred as the nebulizing fluid. Mucolytic agents should be avoided due to their irritant properties.<sup>65</sup> If amikacin is used, the patient should be carefully monitored for signs of polyuria. The effectiveness of treating mycotic air sacculitis with nebulization is not known.<sup>13</sup> In some cases, medications can be injected directly into the trachea or a diseased air sac.

### ■ Nutritional Support

Nutritional support is mandatory for the successful recovery of an anorectic bird. There are two main routes for providing nutritional support. Enteral feeding uses the digestive tract and is the simplest,

while parenteral feeding bypasses the digestive tract by supplying amino acids, fats and carbohydrates directly into the vascular system. In mammals, enteral feeding has been shown to be comparable to or possibly superior to parenteral feeding.<sup>70</sup> Parenteral nutrition is in its infancy in avian medicine, but may be necessary for birds with gastrointestinal disease.

Enteral nutritional support is generally provided in companion and aviary birds using a tube passed into the crop (Figure 15.5). Necessary equipment includes 10 to 18 ga stainless steel feeding needles with rounded tips, rubber feeding catheters of various diameters, plastic catheter adapters, oral beak specula and regular and catheter-tipped syringes. A “sterile” feeding needle or catheter should be used for each bird to prevent the transmission of pathogenic organisms. Feeding needles and catheters should be



**FIG 15.5** Tube-feeding is frequently necessary as part of the supportive care provided to anorectic patients that do not have gastrointestinal tract disorders that would prohibit oral alimentation (eg, crop stasis, ileus). Note that this African Grey Parrot's head is held upright and the tube is inserted from the left oral commissure (courtesy of Kathy Quesenberry).

cleaned thoroughly and sterilized after each use. Raptors are usually hand-fed pieces of prey.

Parenteral medications and fluids should be administered before gavage feeding. If given afterwards, there is a risk of regurgitation during restraint for the subsequent treatments. Oral medications can often be administered with the enteral feeding formula.

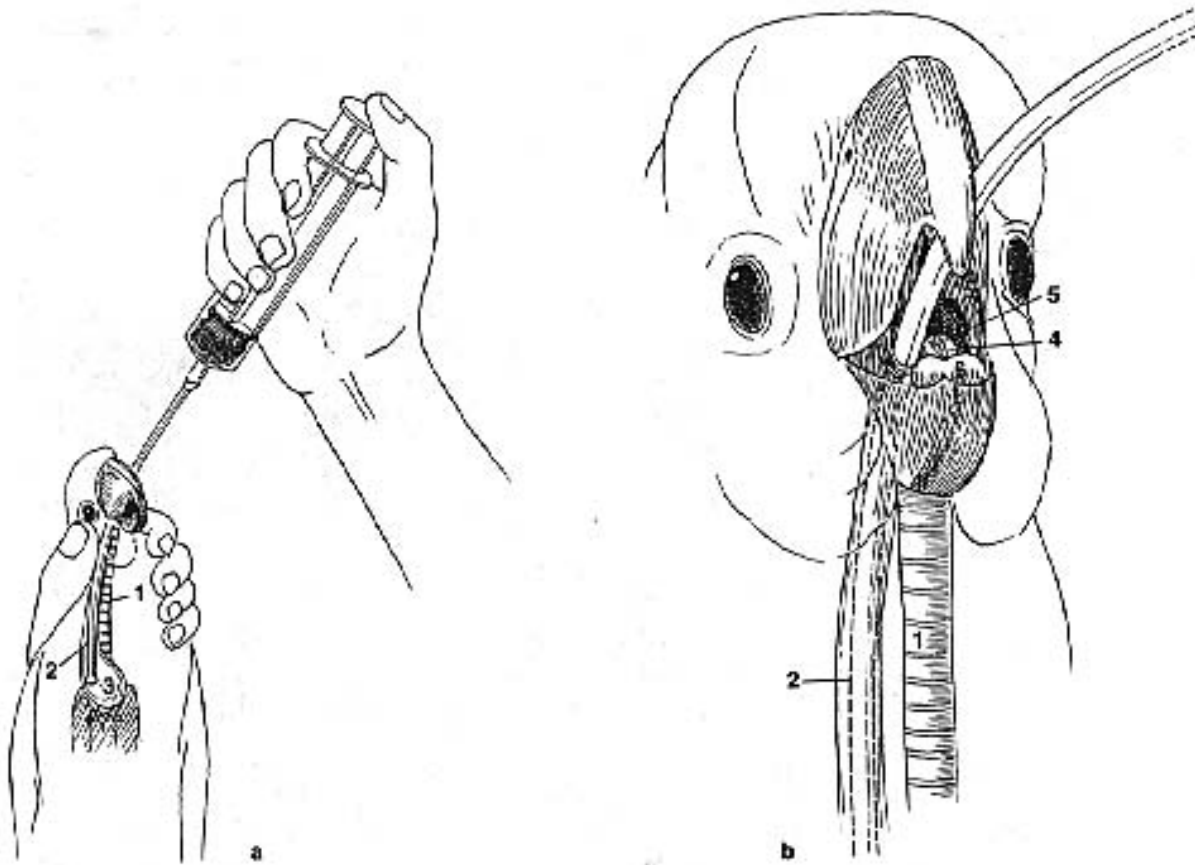
The crop should be palpated before each feeding to determine if residual feeding formula remains. Birds with ingluvitis or gastrointestinal stasis frequently have slow crop emptying times. If residual food remains, the crop should be flushed thoroughly with a warm, dilute chlorhexidine solution. The crop may need flushing for several days before motility returns to normal. “Crop bras” are sometimes used to support slow-moving, pendulous crops and will often improve crop emptying (see Chapter 30).

Tube-feeding is facilitated with the help of an assistant, but it can be done in small birds by one person. The handler holds the bird upright with the body wrapped in a paper or cloth towel (Figure 15.6). An oral speculum can be useful in large birds but is not usually necessary in small birds. A speculum must be used with care to prevent damage to the soft tissues at the lateral beak commissures.

The bird's neck is straightened vertically with the head grasped around the mandibles. An index finger is placed on top of the head to prevent the bird from throwing its head back. The second person then passes the tube into the left oral commissure (Figure 15.6). If the tube is passed directly from the front, the bird will try to chew at the tube. In medium-sized to large birds, the top beak can be pushed slightly to one side with one hand to open the beak for passage of the tube. Alternatively, the upper beak is inserted in the lower beak, preventing the bird from biting on the tube.<sup>34a</sup>

After entering the oral cavity, the tube is passed down the esophagus on the right side of the neck into the crop. Tube placement can be visualized by moistening the feathers on the right lateral neck region. The crop is palpated to check the position of the end of the tube before injecting the feeding formula. The total volume that can be given depends on the size of the bird (Table 15.3). The neck should be kept in full extension during feeding to discourage regurgitation.

After injection of the food, the tube is carefully removed to prevent reflux. The assistant continues to



**FIG 15.6** a) For tube-feeding or crop aspiration, the bird is held in an upright position with the neck in extension. b) The tube is passed through the left side of the oral cavity and down the esophagus in the right side of the pharyngeal cavity. The tip of the tube should be palpated to ensure that it is in the crop before delivering fluids or feeding formula. 1) trachea 2) esophagus 3) crop 4) laryngeal mound 5) rima glottis and 6) tongue.

hold the bird with the neck in extension until the bird is released into its enclosure. If reflux of formula occurs at any time during the tube-feeding process, the bird should be released immediately to allow it to clear the oral cavity on its own. Attempting to swab the oral cavity or turning the bird upside down will cause undue stress and may increase the possibility of aspiration.

**TABLE 15.3** Suggested Volumes and Frequency for Tube Feeding Anorectic Birds

	Volume	Frequency
Finch	0.1 - 0.3 ml	Six times/day
Parakeet	0.5 - 1.0 ml	QID
Cockatiel	1.0 - 2.5 ml	QID
Conure	2.5 - 5.0 ml	QID
Amazon	5.0 - 8.0 ml	TID
Cockatoo	8.0 - 12.0 ml	BID
Macaw	10.0 - 20.0 ml	BID

Most hospitalized birds are tube-fed two to four times daily according to their clinical condition and caloric needs. Neonates and small birds may need to be fed more frequently (see Chapter 30).

If the crop or upper gastrointestinal system is dysfunctional (eg, crop stasis, crop burns, proventricular dilatation or ventricular impaction), a bird can be provided enteral nutrition by injecting food directly into the proventriculus or lower gastrointestinal tract through an esophageal gastric tube (pharyngostomy tube) or duodenal catheter (see Figure 41.10). The first method involves placing a soft feeding tube into the esophagus at the base of the mandible, through the esophageal opening at the right crop base and into the proventriculus. The tube is sutured in place. Cellulitis should be expected to occur at the interface of the tube and esophagus, but generally resolves when the tube is removed.

A second method for supporting enteral alimentation while bypassing the crop is the placement of a duodenal feeding catheter.<sup>17</sup> A small Foley catheter is surgically placed in the proximal duodenum and exited through the lower abdominal wall. The end of the tube is secured to the dorsum or intrascapular area with tape or sutures (see Chapter 41). An easily absorbed liquid diet is infused into the proximal small intestine.<sup>1,41</sup> The volume of liquid formula that can be infused at one time is small, and frequent feedings (as often as every one to two hours) are necessary to meet caloric requirements. Alternatively, food can be infused at a constant rate using an infusion pump. The authors have used this method in young birds for up to six days without complications. Duodenal tubes are not practical for use in small birds due to the difficulty of the surgical procedure and the need for a duodenal tube with a large enough diameter to allow easy infusion of a liquid feeding formula.

#### Total Parenteral Nutrition

Parenteral alimentation involves the intravenous administration of all essential nutrients including amino acids, lipids, carbohydrates, vitamins, electrolytes and minerals. Potential indications for the use of total parenteral nutrition (TPN) in birds include gastrointestinal stasis, regurgitation, some gastrointestinal surgeries, severe head trauma that precludes oral alimentation, malabsorption or maldigestion. In dogs, 50 to 60% of the calories are supplied by a 20% lipid solution, and the remaining calories are supplied by a 50% dextrose solution.<sup>28</sup> Daily protein requirements (1.5-6 gm/kg) are met by using amino acid supplements compounded into the TPN solution.

Difficulties associated with parenteral nutrition in birds include placing and maintaining a catheter, the necessity of multiple intermittent feedings to supply caloric requirements and potential metabolic complications associated with parenteral nutrition<sup>41</sup> (hypophosphatemia, hypo- or hyperkalemia, hyperglycemia and liver function abnormalities). Sepsis or bacteremia can occur from bacterial contamination of the catheter. Continuous infusion is the preferred method for administration of TPN, allowing for rapid dilution of the hypertonic solution, which minimizes irritation to the vascular endothelium.

The intraosseous cannula or a vascular access device can be used for parenteral alimentation.<sup>12</sup> Vascular access devices have been used experimentally for TPN in two geese.<sup>20</sup> The birds received the TPN

formula in four daily infusions of twenty to thirty minutes each using an infusion pump set at 5 ml/min. Both geese showed marked hematologic changes after receiving TPN, including heterophilic leukocytosis; increases in SGPT, AP, cholesterol and CPK; and decreases in glucose, bile acids and triglycerides. One goose died on the second day of TPN. Acute renal ischemia and necrosis were cited as the cause of death. Histopathologic, microbiologic and clinical parameters implicated inflammation and bacteremia secondary to *Staphylococcus aureus* contamination of the VAD. The second goose was maintained on TPN for four days with no clinical abnormalities. Necropsy showed minor changes in the kidneys that were not associated with uric acid elevations.

Total parenteral nutrition administered by VAD was successful when given experimentally in pigeons.<sup>12</sup> The TPN was administered in four daily infusions over a five-day period. Clinical changes were mild including weight loss, regurgitation, transient hyperglycemia, polyuria, glucosuria and tachycardia.

Because the nutritional requirements for avian patients are not known, formulation of TPN diets is primarily extrapolated from mammalian diets and the nutritional requirements of poultry. Enteric liquid diets are estimated to be 90% bioavailable, while TPN solutions are 100% available.

Typically a 10% amino acid solution<sup>i</sup>, a 20% lipid solution<sup>j</sup> and a 50% dextrose solution are used. The amino acid solution provides 100 mg protein/ml, the lipid solution provides 2 kcal/ml, and the dextrose solution, 1.7 kcal/ml. These three solutions can be mixed under clean conditions as a three-in-one TPN solution.<sup>20</sup> A 1000 ml bag of five percent dextrose solution is connected to an IV drip set and aseptically emptied. One day's supply of amino acid solution is injected through the port into the bag. The 50% dextrose solution is then added and mixed by inverting the bag. The lipid solution is added last. It should be added and mixed slowly over a two-minute period. This mixture should be used within 24 hours and should be stored in the refrigerator.<sup>20</sup>

#### Nutritional Requirements

Illness and stress cause a hypermetabolic state in animals and humans. Release of catecholamines, glucagon and glucocorticoids increases the rate of gluconeogenesis and glycogenolysis. When the increase in metabolic rate is coupled with a decreased nutritional intake, fat oxidation occurs at a maximum rate, and body proteins are used as an energy

source.<sup>28</sup> Blood glucose concentrations are increased. Intravenous infusion of isotonic glucose has little sparing effect on body proteins, and may actually be detrimental by increasing the release of insulin.<sup>28</sup> The antilipolytic action of insulin may decrease the use of fat stores and increase body protein breakdown.

Protein demand is high during periods of hypermetabolism. Proteins are necessary for tissue repair, white and red blood cell production, maintenance of blood proteins (albumin, fibrinogen, antibodies) and enzyme production. During periods of high demand, the body uses fatty acids preferentially for energy to spare protein. In the management of human patients, more than 40% of the total kilocalories in many enteral diets are derived from fatty acids.

The size, weight, reproductive status and season all affect the daily caloric needs of birds. The basal metabolic rate (BMR) is the minimum amount of energy necessary for daily maintenance. An estimate of the BMR for birds can be made based on metabolic scaling:<sup>58</sup>

$$\text{BMR} = K(W_{\text{KG}})^{0.75}$$

Passerine birds K = 129  
Non-passerine birds K = 78

The K factor is a theoretical constant for kcal used during 24 hours for various species of birds, mammals and reptiles. The maintenance energy requirement (MER) is the BMR plus the additional energy needed for normal physical activity, digestion and absorption. The MER for adult hospitalized animals is approximately 25 percent above the BMR.<sup>28</sup> In passerine birds, MER varies from 1.3 to 7.2 times the BMR, depending on the energy needed for activity and thermoregulation during different times of the year.<sup>72</sup> With growth, stress or disease, animals are in a hypermetabolic state with daily energy needs that surpass maintenance. The amount of increased demand depends on the type of injury or stress and varies from one to three times the daily maintenance requirement (Table 15.4).

**TABLE 15.4** Adjustments to Maintenance for Stress (as multiples of MER)<sup>41</sup>

Starvation	0.5 - 0.7
Elective Surgery	1.0 - 1.2
Mild Trauma	1.0 - 1.2
Severe Trauma	1.1 - 2.0
Growth	1.5 - 3.0
Sepsis	1.2 - 1.5
Burns	1.2 - 2.0
Head Injuries	1.0 - 2.0

Although not exact, metabolic scaling can be used to estimate the approximate daily caloric needs of birds.

### Enteral Nutritional Formulas

In humans, diets used for enteral nutrition are chosen based on the clinical condition of the patient. For birds, a formula should be used that supplies basic protein, fat and carbohydrates, and is adequate in meeting the energy requirements of the patient.

Commercial enteral nutritional formulas marketed for humans are widely available. These diets are usually liquid formulations sold in 250 ml containers. The diets vary in caloric density, protein, fat and carbohydrate content and osmolality (Table 15.5). Formulas vary from meal replacement formulas, which require some digestion, to monomeric diets, which require little or no digestion. Almost all diets are lactose-free and are approximately 95 percent digestible. These diets have been successfully used for routine nutritional support in sick birds via an enteral route. Knowing the exact caloric density per milliliter is convenient for calculating daily maintenance requirements. Formulas range from less than 1.0 to 2.0 kcal/ml. With a calorie-dense formula (2.0 kcal/ml), the total volume of liquid can be given in two to four feedings per day. Maintaining adequate hydration is important in birds when using calorie-dense formulas. Once opened, enteral formulas can be refrigerated for two to three days. For feedings, the formulas can be heated gently, such as in a syringe under hot running water.

## CLINICAL APPLICATIONS

### Example of Metabolic Scaling to Estimate Approximate Daily Caloric Needs of Birds\*

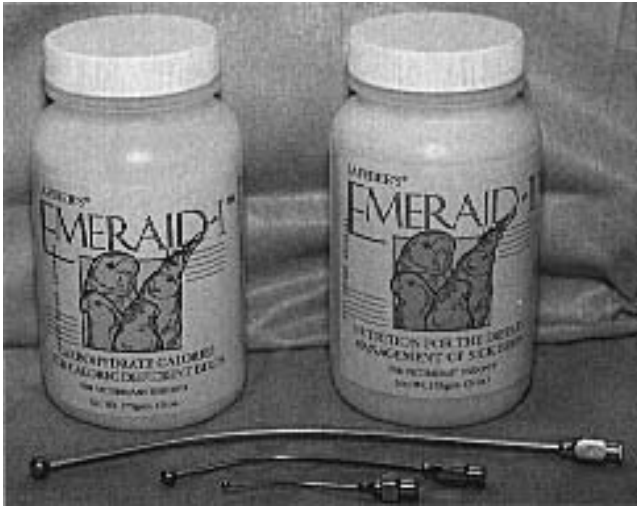An Amazon parrot weighing 350 grams is presented for septicemia secondary to bacterial enteritis. Estimating MER as 1.5 times BMR, the daily caloric needs can be estimated as:

- BMR =  $78(0.35^{0.75})$  or 35 kcal/day
- $1.5 \times 35$  kcal/day = 53 kcal/day approximate MER
- $1.2 \times 53$  kcal/day = 63.6 kcal/day increase for sepsis

If the energy content of the feeding formula is known, the daily calorie needs are divided by the calories per ml of formula to calculate the total volume of formula needed daily. For example, using a formula that is 1.5 kcal/ml, the total volume of formula needed per day for the Amazon is:

- 63.6 kcal/day  $\div$  1.5 kcal/ml = 42.4 ml needed daily

\*See Appendix for instructions on using this formula.



**FIG 15.7** Commercially available enteral nutritional products are superior to homemade formulas because they provide consistent nutritional and caloric content. Feeding needles can be used to deliver these products (courtesy of Kathy Quesenberry).

**TABLE 15.5** Commercial Enteral Products: Nutrients per 100 kcal\* Energy<sup>41</sup>

Product	Protein (g)	Fat (g)	Carbos (g)	kcal/ml
Isocal <sup>k</sup>	3.4	4.4	13.3	1.0
Isocal HCN <sup>k</sup>	3.8	5.1	10.0	2.0
Traumacal <sup>k</sup>	5.5	4.5	9.5	1.5
Pulmocare <sup>l</sup>	4.2	6.1	7.0	1.5
Ensure Plus <sup>l</sup>	3.6	3.5	13.0	1.5

\* kcal = calories

Formula may curdle in the crop of birds with ingluvitis and gastrointestinal stasis, probably because of changes in the pH of the crop. Flushing the crop with warm water while gently massaging the crop will cause the curdled formula to break apart, allowing aspiration and removal. Multiple feedings of small amounts of an isotonic or diluted formula should be given until the crop motility is normal.


Commercial enteral formulas marketed for use in birds are available (Figure 15.7). These diets are either dry powders or liquids. They are consistent in nutritional content, easy to prepare and use and relatively low in cost. In general, these diets are relatively high in carbohydrate content when compared to human products. Some products are low in calorie content. Powdered products can curdle or sludge in the crop, especially if an inadequate amount of water is used for mixing.

Some veterinarians prefer to blend their own feeding formulas. Combinations of monkey chow, baby cereal, strained baby vegetables, vitamin and mineral supplements and water are used. Plant enzymes are sometimes added to improve digestibility (see Chapter 18). Homemade formulas may work but have the disadvantage when compared to commercial products of varying consistency and nutritional and caloric content. Formulas based on baby cereal are usually high in carbohydrates and low in fat and protein. Many homemade formulas are too high in water content and provide insufficient levels of energy. Following the bird's weight on a daily basis (in grams) is the best evaluation of enteral feeding.

### Oxygen Therapy

An oxygen enclosure is highly recommended as standard equipment in an avian practice (Figure 15.8). There are several commercially available enclosures made specifically for use in birds. Most are designed as incubators with controls for heat and monitors for humidity. Human infant incubators with oxygen input ports can be adapted for use in birds. Oxygen levels within the enclosure can be monitored with an oxygen analyzer. Analyzers<sup>m</sup> are available with accuracy to within two percent. Administration of oxygen by face mask is effective for short-term treatment if an oxygen enclosure is not available, or during restraint while treatments or diagnostic tests are performed. If there is upper airway obstruction, oxygen can be infused through an air sac tube.

The actual benefits of oxygen supplementation in birds are unknown. Birds have a unique and efficient



**FIG 15.8** An oxygen enclosure should be standard equipment in any avian hospital (courtesy of Kathy Quesenberry).

respiratory system and may respond to oxygen supplementation differently than do mammals. Clinically, dyspneic birds appear to stabilize when placed in an oxygen enclosure and maintained at 40 to 50% oxygen concentration. Oxygen therapy is potentially toxic in mammals if given for prolonged periods at high concentrations. Oxygen can be supplemented in small animals at levels up to 100% for less than 12 hours without complications.<sup>65</sup> Canaries and budgerigars given continuous supplemental oxygen at concentrations of 82 to 100% and 68 to 93%, respectively, showed signs of lethargy, anorexia, respiratory distress and death after three to eight days.<sup>62</sup> Pathologic changes in the lungs included pulmonary congestion, histiocytic infiltration into the bronchi and deposition of proteinaceous material. Changes were consistent with those seen in mammals with oxygen toxicity.

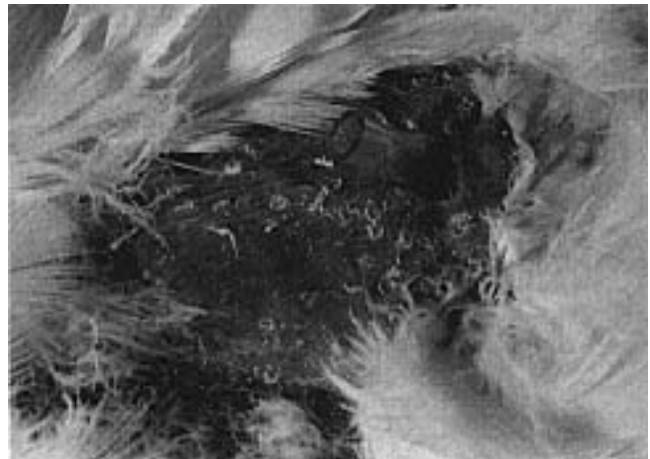Oxygen delivery to the tissues is dependent on adequate perfusion. Birds that are severely anemic or in circulatory shock need adequate volume expansion and red blood cell replacement for improved tissue oxygenation to occur.

#### Air Sac Tube Placement

Placement of an air sac tube is beneficial in birds with tracheal obstructions, or when surgery of the head is necessary. In companion birds the tube is normally placed in the caudal thoracic or abdominal air sac, allowing direct air exchange through the tube into the air sac. Following tube placement, dyspnea stops almost instantaneously in birds with upper airway obstruction. An air sac tube may also improve respiration in birds with air sacculitis, although the improvement in breathing is usually less dramatic (Figure 15.9).

An alternative site for air sac cannulation used in raptors is the interclavicular air sac.<sup>43</sup> In a study with Peking Ducks, there were no changes in heart rate, mean arterial blood pressure, PaO<sub>2</sub> or PaCO<sub>2</sub> when the clavicular air sacs were cannulated (see Chapter 39).<sup>47</sup> There were significant increases in the tidal volume and minute ventilation when compared to control birds. These increases may have resulted from a decrease in effective ventilation or an increase in respiratory dead space.

A shortened endotracheal tube, trimmed rubber feeding tube or plastic tubing from an IV extension set can be used for an air sac tube.<sup>54</sup> The diameter and length of the tube depend on the size of the bird. The tube can be placed in the lateral flank area in the



**FIG 15.9** A Sulphur-crested Cockatoo was presented with an acute onset of severe dyspnea. The bird was in excellent overall condition. The bird was anesthetized with isoflurane and an air sac tube was inserted in the abdominal air sac. The bird began to breathe normally within two to three minutes of inserting the air sac tube. An Ayres T-piece was connected to the air sac tube and the bird was maintained on 1.5% isoflurane delivered into the air sacs. A small plastic ball was identified in the rostral part of the trachea by endoscopy. A needle was passed through the trachea distal to the ball to prevent it from descending further down the trachea. The ball was removed by holding the bird upside down and using suction.

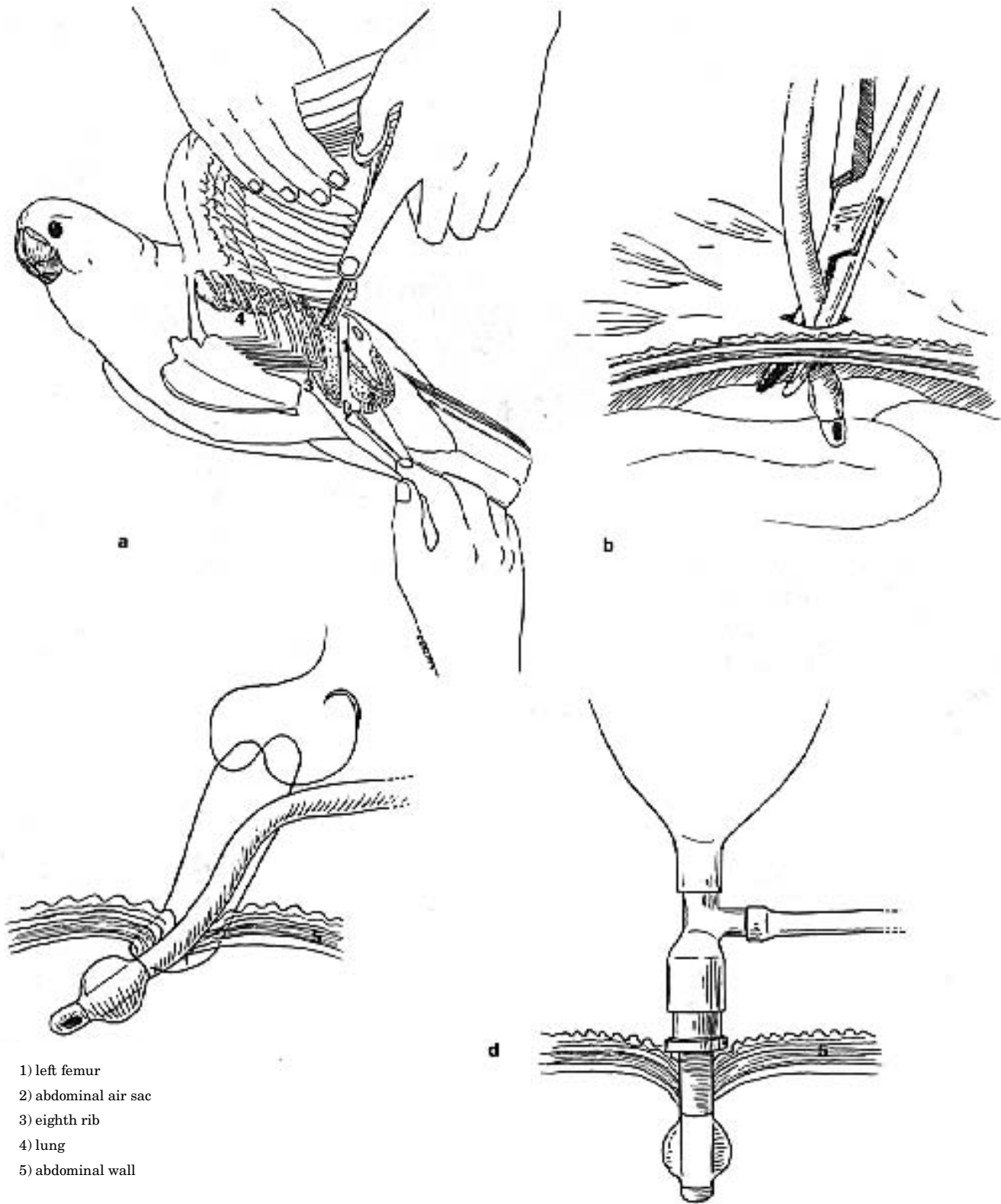
same anatomic location as for lateral laparoscopy, or caudal to the last rib with the femur pulled forward (Figure 15.10). The bird is placed in lateral recumbency, prepped with a surgical scrub and a small incision is made in the skin. Mosquito forceps are used to bluntly penetrate the muscle wall and enter the air sac. The end of the tube is inserted into the air sac between the opened jaws of the mosquito forceps. If the tube is patent, condensation will appear on a glass slide held over the end of the tube. Tape is placed around the tube in a “butterfly” fashion and sutured to the skin, or a fingertrap suture technique is used. If a shortened endotracheal tube is used, the cuff can be slightly inflated just inside the abdominal wall to form a secure seal.

If placed correctly, the bird will immediately begin breathing through the tube. If anesthetized, the bird

#### CLINICAL APPLICATIONS

##### Air sac tubes can be used to:

- Alleviate dyspnea secondary to URD
- Deliver anesthesia for evaluation or surgery of the head or trachea
- Provide an immediate airway following apnea
- Deliver nebulized medications to a specific air sac



**FIG 15.10** Placement of a tube in the abdominal air sac can be used to provide oxygen or isoflurane anesthesia. **a)** The tube is placed by making a small skin incision in the area of the sternal notch. **b)** A pair of hemostats is passed through the body musculature and the air sac tube is inserted between the jaws of the hemostats. **c,d)** A cuffed endotracheal tube can be sutured to the body wall if the tube will remain in place for several days.



will become light unless the end of the tube is occluded or attached to the anesthesia machine. The air sac tube can be left in place for three to five days. The effect of direct exchange of room air into the air sac and the potential for introduction of contaminants and infectious organisms into the cannulated air sac are unknown.

An air sac tube allows many treatment techniques to be performed that would otherwise be impossible in a dyspneic bird. Liquid medications can be instilled directly into the trachea for the treatment of bacterial or fungal tracheitis. The bird can be anesthetized through the tube for surgery or endoscopy of the trachea or head, and the tube can be used for positive pressure ventilation or resuscitation. Birds can be nebulized with the air sac tube in place, possibly increasing the concentration of antimicrobials in the air sacs. If apnea occurs, a needle can be used in place of a tube for providing a rapid source of oxygen.

### Heat

A warm ambient environment is necessary for birds that are debilitated or in shock. Many commercial enclosures and incubators are available with floor or ceiling heating elements, side heating consoles or radiant heat systems. Floor heating elements may occasionally cause hyperthermia when debilitated birds are forced to stand or lie on the enclosure floor or in direct contact with the heating surface. Alternatively, heat can be provided by a hot water bottle or well insulated heating pad (preferably water). Birds receiving supplemental heat from any source other than a commercial incubator should be carefully monitored to prevent burns. Small, heated rooms that hold two to three enclosures allow birds to be treated in a temperature-stable environment, reducing the stress associated with being removed from a warm incubator to a cooler treatment area. It should be noted that none of the commercially available incubators with forced air heating systems can be properly sterilized with any procedure that does not involve the generation of formalin gas.

Enclosures should be equipped with thermometers to monitor ambient temperature. Many commercial enclosures also have humidity sensors. Ambient temperature for adult birds should be 85°F and humidity should be approximately 70%. Unfeathered baby birds less than ten days old need an ambient temperature of 94°F.<sup>25</sup> Older chicks can be maintained at 90°F. Birds in heated enclosures should be monitored

for hyperthermia, which is clinically suggested by panting and holding the wings away from the body.

### Housing

Many sick birds are too weak to perch. These birds should be placed in a smooth-sided enclosure or incubator without perches. Thick paper or non-woven towels can be used on the bottom of the enclosure. Many sick birds will not eat unless food and water are easily accessible. Seeds, fruits and vegetables can be spread around the bird to encourage eating. If the bird is still perching, food and water containers should be placed next to the perches to encourage food consumption. Millet spray is an attractive food item for many smaller species.

Although abrupt diet changes should not be attempted while the bird is sick, offering the bird a balanced diet in addition to any food it is accustomed to eating is appropriate, and may offer therapeutic benefits because of improved nutrient value. Food and water should be removed from the enclosure of birds that are seizing, obtunded or post-anesthetic to decrease the danger of aspiration or drowning.

Birds with leg fractures or paralysis are best maintained in a wire enclosure on thick cage paper or toweling. These birds will grasp the wire siding with their beak to steady themselves. If perches are provided, they should be close to the enclosure floor to prevent injuries.

## Emergency Problems

### Cardiovascular System

#### Bleeding and Anemia

The emergency clinician is often presented with bleeding birds and sick birds that are anemic. Anemia in birds may be caused by blood loss, decreased red blood cell production and increased red blood cell destruction. As in mammals, anemias can be classified as regenerative or non-regenerative.

The most common cause of blood loss in birds is trauma (Figure 15.11). Other causes include gastrointestinal (GI) bleeding, genitourinary bleeding, hemolysis and idiopathic hemorrhage. Hematochezia and melena may occur from enteritis, gastro-

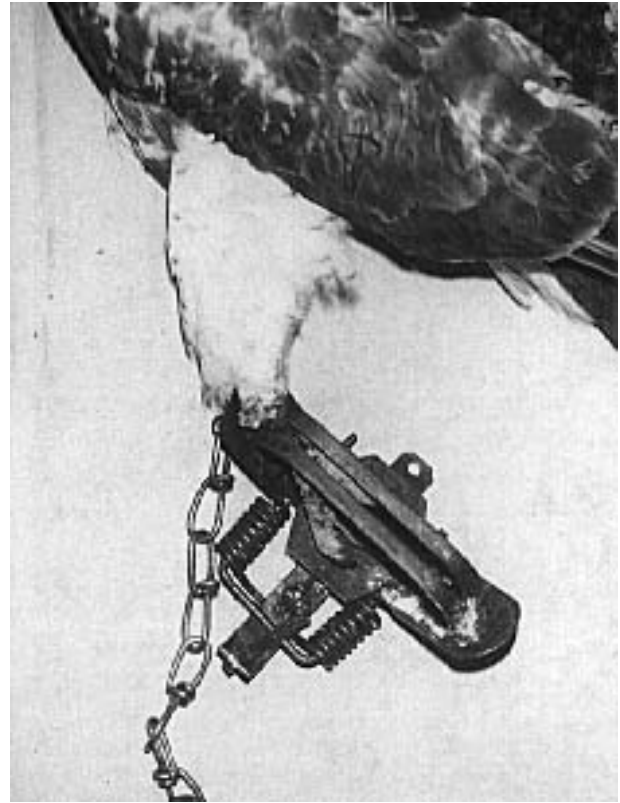
intestinal ulcers, coagulopathies, liver disease and GI foreign bodies. Cloacal bleeding may be caused by cloacal papillomas, cloacitis, egg laying, or cloacal or uterine prolapse. Heavy metal toxicity can cause hemolysis, which may result in dramatic hemoglobinuria in some birds, especially Amazon parrots. Conures may present for a sudden onset of weakness, ataxia, epistaxis, bloody regurgitation, bleeding from the oral cavity, hematochezia, hemorrhagic conjunctivitis or muscle petechiation.

Anemias resulting from decreased red blood cell production are common in birds, possibly because of the relatively short life-span (28 to 45 days) of the avian erythrocyte.<sup>22</sup> “Depression anemias” are usually caused by chronic infectious, toxic or nutritional disease. A rapidly fatal non-regenerative anemia seen in two- to four-month-old African Grey Parrots is suspected to be of viral etiology. Some birds with this problem have been shown to have polyomavirus or PBFV virus antigens in the bone marrow.

Diagnosis of anemia is based on clinical signs and documentation of a decreased PCV. Weakness is the most common clinical sign. Severely anemic birds may have a dull, almost dazed demeanor. Tachypnea and tachycardia may also be present. On physical examination, pallor of mucous membranes is evident in the oral cavity, palpebral conjunctiva and cloaca.

CBC and reticulocyte count, serum or plasma biochemistry analysis, blood heavy metal concentration and whole body radiographs should be considered in cases of anemia of unknown origin. Further testing might include chlamydia screening and a bone marrow aspirate. If an intraosseous cannula will be necessary for stabilizing the patient, a bone marrow sample can be obtained through the cannula at the time of placement. If the mucous membranes are pale, the PCV should be determined before drawing more blood. If the PCV is below 15%, further blood collection is inadvisable. It should be noted that the volume of serum or plasma relative to the volume of whole blood will be increased due to the anemia; the minimum amount of blood necessary to perform the desired diagnostic tests should be drawn.

If the bird is actively bleeding on presentation, localization of hemorrhage and hemostasis are the first priorities. Developing feathers are called “blood feathers” because of the rich vascular supply within the shaft. When one of these feathers is broken, it may continue to bleed until it is removed from its follicle. For removal, the base of the damaged feather



**FIG 15.11** A mature female Red-tailed Hawk was presented after being found in a forest dragging a steel jaw trap. All of the soft tissues surrounding the metatarsus were destroyed. The metatarsus was black. The bird was euthanized. Steel jaw traps are illegal in many states but are still used by poachers and individuals unconcerned with the inhumane destruction of free-ranging animals.

is identified by parting the surrounding feathers. The base is grasped firmly with hemostats, and the feather is removed from its follicle by gently placing opposing pressure on the structure around the feather base (Figure 15.12). If any bleeding occurs from the dermis, it can be controlled by applying pressure to the area or packing the follicle with surgical gel. Chemical or radiosurgical cautery<sup>o</sup> should not be used inside the feather follicle because the subsequent inflammation and tissue damage can cause abnormal feather regrowth, resulting in the formation of feather cysts.

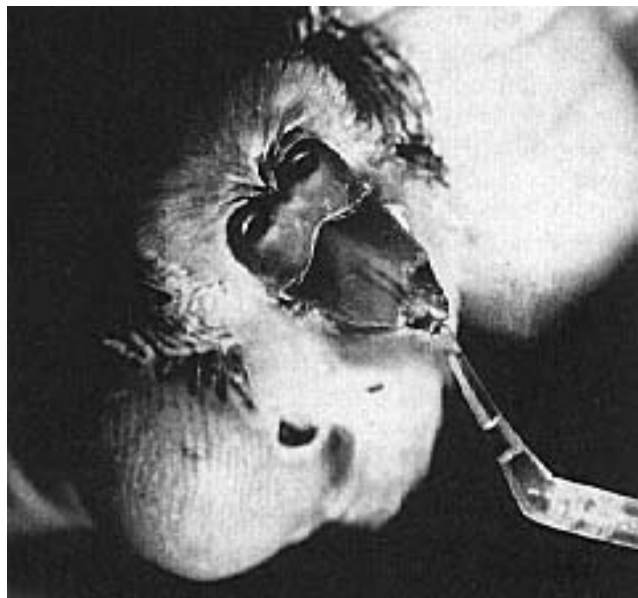
For home first aid, the client can be advised to wash any blood away with hydrogen peroxide, apply cornstarch or flour to the bleeding area and place the bird in a dark area until it can be presented to the clinician for evaluation. Bleeding from a nail can be arrested using ferric subsulfate, silver nitrate or bipolar radiosurgery. Application of bar soap or heat from a red-hot item can also serve as first aid measures.



**FIG 15.12** Primary and secondary pin feathers have a substantial blood supply that arises at the base of the feather shaft where it is attached to the periosteum. Damaged pin feathers can result in substantial blood loss. Correctly removing the feather will allow the nutrient artery to collapse and will stop the bleeding. To remove a pin feather, the base of the feather is grasped with a pair of hemostats as close as possible to the skin edge. The skin is supported by applying gentle, opposing force around the feather

Persistent bleeding from soft tissue wounds is less common. If such bleeding occurs, it can be controlled by applying pressure to the area or through the use of bipolar radiosurgery. Surgical tissue adhesive<sup>b</sup> is often useful (Figure 15.13). Hemorrhage from oral and tongue lacerations may be difficult to control. Complete evaluation and suturing of these lacerations usually require general anesthesia.

The extent of blood loss can be gauged by the history or by the amount of blood present in the carrier. The capacity of birds to tolerate acute blood loss is often underestimated. In general, flighted birds tolerate blood loss better than mammals and non-flighted birds. Blood volume in birds averages ten percent of body weight. A healthy bird can lose as much as 30% of blood volume (about 3 ml/100 grams of body weight) with minimal clinical problems.<sup>44</sup> Because it



**FIG 15.13** Careful application of tissue adhesives can be used to control bleeding of the beak or nails. Glue applied to the beak must not be allowed to run into the mouth or onto the eyelids.

takes roughly 24 hours following hemorrhage for the PCV to equilibrate, measurement of the PCV two days after the onset of blood loss is most useful as a diagnostic and prognostic indicator.

Nonspecific treatment for blood loss includes volume replacement by subcutaneous or intravenous fluids, and the administration of iron dextran and B vitamins (see Chapter 18). The need for hospitalization and further supportive care depends on physical examination findings. Birds that are weak and in shock will require more aggressive therapy. Birds on an all-seed diet can be assumed to be nutritionally deficient and will benefit from an injection of vitamin K<sub>1</sub>.

In birds with idiopathic hemorrhage, such as in conure bleeding syndrome, injectable vitamin K<sub>1</sub>, vitamin D<sub>3</sub>, calcium and antibiotics are indicated. The etiology of conure bleeding syndrome is unknown, but it is possible that a dietary lack of vitamin K, calcium and other nutrients may alter normal clotting mechanisms.<sup>51,55</sup> If hemoglobinuria is present, treatment should be initiated with calcium disodium edetate (CaEDTA) for possible heavy metal toxicity (see Chapter 37). If clinical signs are being caused by heavy metal toxicity, there will usually be clinical improvement within six hours of initiating CaEDTA therapy.

The benefits of blood transfusions in birds are controversial. In pigeons that lost 70% of blood volume, it

was determined that fluid replacement with LRS was more effective in resolving anemia than iron dextran, homologous blood transfusions or heterologous blood transfusions. All study birds had a normal PCV within six days following acute blood loss. Heterologous transfusions from chickens were not an effective treatment, but the authors concluded that a homologous blood transfusion might be useful in birds with a PCV <20%.<sup>6</sup> A similar controlled study is needed to evaluate blood transfusions in psittacine birds. Until a controlled study is performed, it is probably valid to assume that homologous blood transfusions are preferable to heterologous, and that in most instances, a blood transfusion will not greatly increase the survival rate in acute blood loss. However, in the authors' experience, even heterologous blood transfusions appear to be clinically beneficial to birds suffering from chronic anemia. The goal of the transfusion is to stabilize the patient while diagnostic tests can be used to determine the etiologic agent of the anemia. A transfusion volume of roughly 10 to 20% of calculated blood volume is ideal. A rough cross-match can be performed by mixing red blood cells from the donor with serum from the recipient; the absence of gross agglutination or hemolysis suggests compatibility.

### Shock

The state of shock is difficult to determine in the avian patient. Clinical signs include weakness, pallor and poor perfusion of peripheral vessels. Vascular perfusion can be estimated by occluding the ulnar vein proximally on the medial surface of the wing and evaluating turgescence and filling time.<sup>1</sup> Decreased turgor and a filling time greater than 0.5 seconds are indications of reduced circulatory volume. Septic shock is a possibility in debilitated birds, and is clinically recognized as severe depression, particularly in birds with known exposure to infectious diseases.

Therapy for shock includes administration of fluids to expand the circulating blood volume and rapidly acting corticosteroids. If possible, corticosteroids and fluids should be administered intravenously or intraosseously. Intramuscular corticosteroids and subcutaneous fluids are beneficial but take more time to enter the circulation. In cases of shock, a state of metabolic acidosis may be present, and bicarbonate replacement therapy should be considered. Parenteral bacteriocidal antibiotics are given if bacterial infections are suspected.

### Cardiac Failure

The field of avian cardiology is in its infancy, and cardiac failure is rarely diagnosed antemortem. Suspicious clinical signs include weakness, anorexia, tachypnea, dyspnea, coughing and abdominal distension due to hepatomegaly and ascites. The diagnosis is suggested by finding an arrhythmia or murmur on auscultation, and by radiographic changes including cardiomegaly, hepatomegaly and ascites (Figure 15.14). A single IM dose of furosemide, low-dose subcutaneous fluids and an oxygen-rich environment are indicated. Electrocardiography and ultrasonography are used to confirm cardiac disease and guide the selection of other cardiac medications (see Chapter 27).<sup>35,48</sup>

### Cardiopulmonary Resuscitation (CPR)

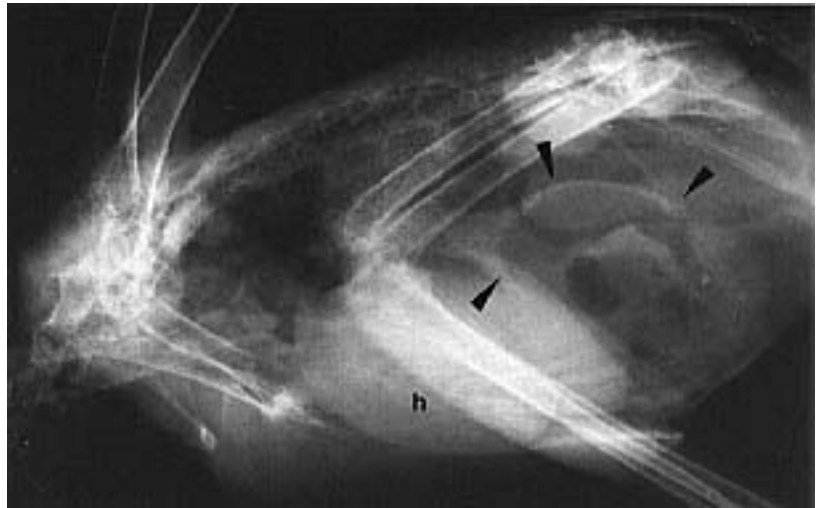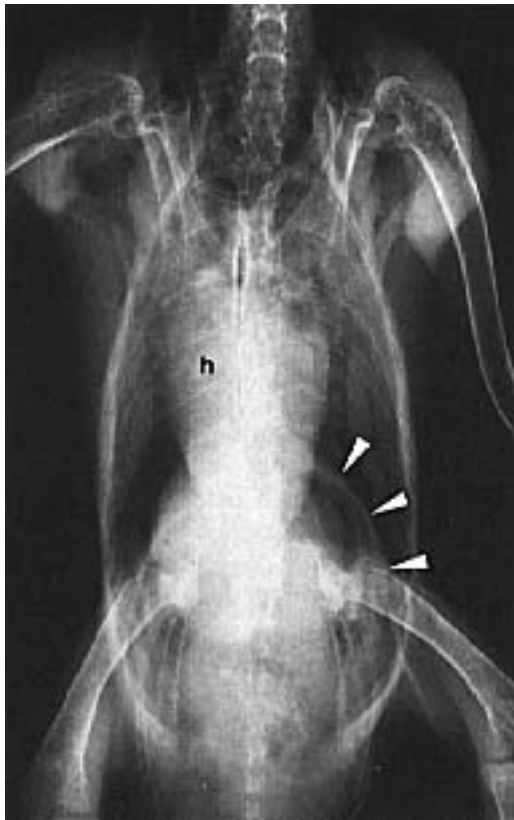
Avian CPR follows the same "ABC's" as mammalian CPR: Airway, Breathing and Circulation. In a bird that has stopped breathing, an airway must be established by placing an endotracheal or air sac tube. To avoid the danger of zoonotic disease, it is preferable to ventilate the bird in this fashion; alternatively, mouth-to-mouth respirations can be given by cupping the mouth over the bird's nares and beak opening. Positive pressure ventilation should occur once every four to five seconds. Once ventilation has been started, the heart beat or peripheral pulse should be determined. If neither is present, the heart should be massaged by firm and rapid compression of the sternum. Epinephrine and doxapram are given as necessary. The intratracheal, intracardiac or intraosseous routes (even spray into the thoracic cavity if open) for emergency drug administration should be considered when peripheral vascular access is not possible.<sup>24</sup>

Cardiopulmonary resuscitation should always be attempted in previously healthy birds that have collapsed; however, CPR is rarely successful in birds that are debilitated from long-standing, chronic disease.

## Gastrointestinal System

### Crop Burns and Injuries

Thermal burns of the crop are seen in hand-fed neonates, particularly psittacine birds. The most common cause is the occurrence of "hot spots" in poorly mixed microwaved formulas. Birds will accept the overheated formula without showing discontent. A few hours after feeding, an erythematous area of skin is evident overlying the crop, generally on the right ventral portion. If the bird has feathers in this area, the burn is often not noted unless the crop and skin



**FIG 15.14** A one-year-old Umbrella Cockatoo was presented for emaciation (409 g) and depression. The bird had severed an electric cord the day before presentation and was having problems swallowing. Physical examination findings included harsh respiratory sounds (lung area) and dull “sunken” eyes. Abnormal clinical pathology findings included PCV=30, LDH=1400 and AST=850. Radiographic lesions included cardiomegaly (h), gaseous distension of the gastrointestinal tract (ileus) and enlarged radiodense kidneys. Note the gaseous distension of the proventriculus (arrows). The enlarged radiodense kidneys are suggestive of severe dehydration (consistent with physical examination findings), but microcardia is more characteristic of dehydration than cardiomegaly. The bird did not respond to emergency therapy. Histopathology findings included severe hepatocellular necrosis and pulmonary hemorrhage.

necrose, leaving a fistula from which formula drains out onto the breast feathers (see Color 30).

The presence of a fistula is alarming to most owners; however, it is a true emergency only if the fistula is so large that all formula drains out of the crop, leaving the bird in danger of dehydration and starvation. The frequency of feedings may have to be increased in the interim in order to replace the formula lost through the fistula. If the burn is discovered soon after it occurs, the crop area should be monitored daily. The use of anti-inflammatories (eg, corticosteroids) represents more of a risk than a benefit in young birds (see Chapter 41).<sup>24</sup> Some periesophageal burns, lacerations and other injuries may not result in fistula formation and are recognized clinically as crop stasis. In some cases, the feeding instrument may have punctured the crop, and the food is deposited between the skin and the crop wall. This is a true emergency because the bird can suddenly become toxic, exhibit massive edema and die.

#### **Gastrointestinal Stasis**

Gastrointestinal stasis is a common problem in pediatric medicine. Multiple factors that may affect GI motility in young birds include infectious disease, poor sanitation, low environmental temperature, low

formula temperature and low humidity. Physical obstructions are usually caused by foreign body ingestion (bedding is a common culprit) or accidental ingestion of a feeding tube. Causes of GI stasis in adult birds include gastroenteritis (leading to ileus), neuropathic gastric dilatation, heavy metal toxicity and obstruction (see Chapter 19).

Delayed crop emptying is the most common presenting sign of GI stasis. Regurgitation or vomiting may occur also. Fecal output is reduced. If allowed to persist, the bird becomes dehydrated, loses weight and may become septic. Chronic cases in debilitated birds can be difficult to manage and treat effectively, and the client should be advised that therapy may be lengthy and that the prognosis is poor.

Physical examination begins with an assessment of hydration status and thorough palpation of the crop for the presence of foreign bodies or inspissated food material. Some crop foreign bodies, particularly linear ones, can be removed by carefully manipulating them back up the cranial esophagus and into the oropharynx, where they are visualized and grasped with forceps. Removal of other foreign objects and inspissated food material is most easily accomplished via ingluviotomy (see Figure 41.13). The bird is anes-

thetized with isoflurane and intubated to reduce the danger of aspiration. A small incision is made over the left lateral pendulous crop to ensure that the incision is not damaged should the bird require tube-feeding. The incision is closed in two layers using a 6-0 absorbable suture. Postoperative feedings should be small and frequent, beginning with clear liquids and gradually increasing the strength and amount of formula over the next 24 to 48 hours until a normal feeding schedule has been resumed.

If a crop foreign body cannot be palpated, food and water should be withheld until the crop is empty or the crop can be drained by the clinician. Usually it is difficult to empty the crop via gavage tube because crop contents tend to become thickened when the crop is static. Some clinicians hold the bird upside down and express the crop contents.<sup>50</sup> The authors believe that this technique in unanesthetized patients puts the bird in risk of aspiration, and that even when used in anesthetized patients, a finger should be placed over the choanal slit during the procedure to prevent reflux from entering the nasal passages. Another technique is percutaneous aspiration of the crop using an 18 to 22 ga needle.<sup>24</sup> Flushing the crop with 0.05% chlorhexidine solution is often beneficial. This can be done two to four times daily if the bird can tolerate the handling. After flushing, a small amount of LRS, followed in three hours with dilute formula or Isocal,<sup>k</sup> should be administered by gavage tube.

Radiographs and a barium series are indicated if impaction or extraluminal obstruction is suspected, particularly in adult birds. Before the series is begun, the crop contents should be removed and the anesthetized bird should be held upright until the esophagus can be packed with moist gauze. A finger placed over the cranial esophagus will help prevent reflux from entering the pharyngeal area.

A minimum database should include cytology of the crop contents and fecal wet mounts (see Chapter 10). Samples can be collected by crop lavage or by passing a flexible swab directly into the crop. Culture and sensitivity of the crop contents and feces are indicated if bacterial infection is suspected. An in-house blood glucose determination is important if the bird is weak.

In birds with GI stasis, restoring and maintaining hydration with subcutaneous, intravenous or introsseous fluids is important, and should be considered prior to performing surgery or other stressful proce-

dures. Parenteral antibiotics and metoclopramide<sup>an</sup> are often indicated (see Chapter 18). Oral medications are mostly ineffective because of slow passage into the intestinal tract. Oral aminoglycosides, however, may be beneficial in cases of bacterial overgrowth because they act locally with minimal absorption or side-effects. Parenteral feeding or placement of a duodenal feeding tube should be considered in critically ill birds (see Chapter 41).

Budgerigars with goiter often present with crop stasis and a history of regurgitation due to pressure of the enlarged thyroid glands on the caudal esophagus. These birds may also have a squeaky voice or an audible click with each respiration; tachypnea and tail-bob may be present. Diagnosis of goiter is based on clinical signs and history of an iodine-deficient diet. These birds should be hospitalized for parenteral fluids, steroids, antibiotics and iodine therapy. In mild cases, crop motility may be restored without the need for emptying and flushing the crop by gavage tube. Occasionally a bird may not respond to standard therapy, and thyroid gland neoplasia should be considered in these cases.

### Regurgitation and Vomiting

The distinction between regurgitation and vomiting in birds is often difficult to make clinically and, for the purposes of this section, the term regurgitation will be used.

Regurgitation to a "mate" (often the owner) or mirror is a normal part of breeding behavior; this is seen most commonly in budgerigars and cockatiels but can occur in any psittacine bird. A clinical history that includes intermittent regurgitation when the bird is being handled or talked to will help differentiate this normal behavior from a pathologic problem. Pathologic regurgitation in birds is caused by primary GI problems, metabolic problems and toxicities that induce nausea. Primary GI problems include infection (bacterial, viral, fungal and parasitic) and both intraluminal and extraluminal obstruction. Metabolic problems include hepatic and renal disease (see Chapter 19). Toxins that may cause vomiting include ingestion of some plants, pesticides and heavy metals such as lead or zinc. Some birds will regurgitate from stress or from motion sickness (such as during a car trip). Iatrogenic regurgitation may occur when the crop is over-distended with gavage formula and during recovery from chemical sedation or anesthesia.

Birds that are regurgitating will make a head-bobbing and neck-stretching type of motion. If the owner

does not observe or recognize this characteristic motion, a sign of regurgitation is finding food caked on the head feathers, giving the bird a spiky, “punk-hairedo” appearance (see Figure 19.7). A bird will often shake its head when regurgitating, depositing the regurgitus about the face and head. The bird should be evaluated for hydration, and the crop and abdomen should be palpated for distension or the presence of a foreign body or a mass. Goiter is the most common pathologic cause of regurgitation in budgerigars over two years of age. Bloody regurgitation may be seen in conure bleeding syndrome.

Initial diagnostic testing should include swabbing or flushing the crop for a wet mount, cytology, Gram’s stain and culture. Fecal examination by wet mount and Gram’s stain is often informative also. Other diagnostic tests to consider include a CBC, biochemistry profile and blood heavy metal concentration. Whole body radiographs, a routine barium series, or a double contrast study of the upper GI tract may be useful (see Chapter 12).

Initial stabilization of the regurgitating patient involves parenteral fluid therapy, removal of foreign bodies or toxins, specific toxin antidotes and appropriate antimicrobials if bacterial or fungal infections are suspected. Flushing the crop with 0.05% chlorhexidine reduces local bacterial levels in cases of ingluvitis.

### Severe Diarrhea, Hematochezia and Melena

Diarrhea in birds is clinically recognized by unformed feces, often in association with an increase in the fluid portion of the dropping (see Color 8). Stools may “normally” be loose from stress, excitement, over-consumption of dairy products and ingestion of foods with a high water content (vegetables and fruits). Pathologic diarrhea usually results from bacterial, viral, fungal, chlamydial or parasitic gastroenteritis. The presence of a foreign body in the GI tract can also cause diarrhea. Pancreatic or liver disease and ingestion of some toxins may cause diarrhea. The differential diagnosis list for the emergency patient with diarrhea includes gram-negative enteritis, hep-atopathy, chlamydial infection and heavy metal toxicity.

Physical examination of the bird with diarrhea should begin with careful evaluation of the hydration status and gross evaluation of droppings for evidence of blood, mucus, undigested food, plant material or gravel. Melena may be noted with problems of the upper GI tract (enteritis, foreign bodies, parasites,

ulcers). Hematochezia may be present with disease of the colon or cloaca. Cytology or a dip stick for fecal occult blood should always be used to document GI bleeding before aggressive and unnecessary therapy is instigated. The cloacal mucosa can be examined by prolapsing it gently with a well lubricated cotton swab (Figure 15.15). The presence of yellow or green urates suggests involvement of the liver. Brown, pink, red or rust-colored urates are seen most commonly with acute heavy metal toxicity, particularly in Amazon parrots (see Color 8). Birds consuming heavily pigmented fruits (eg, blueberries, blackberries) may have dark feces that mimics melena or hematochezia (see Color 8).

The database for diarrhea includes fecal examination by wet mount, Gram’s stain and culture. Cytology for *Giardia* sp., *Trichomonas* sp. or other protozoa should be considered. Other valuable diagnostic tests include a CBC, biochemistry profile, radiographs, blood heavy metal concentration and screening for chlamydia.

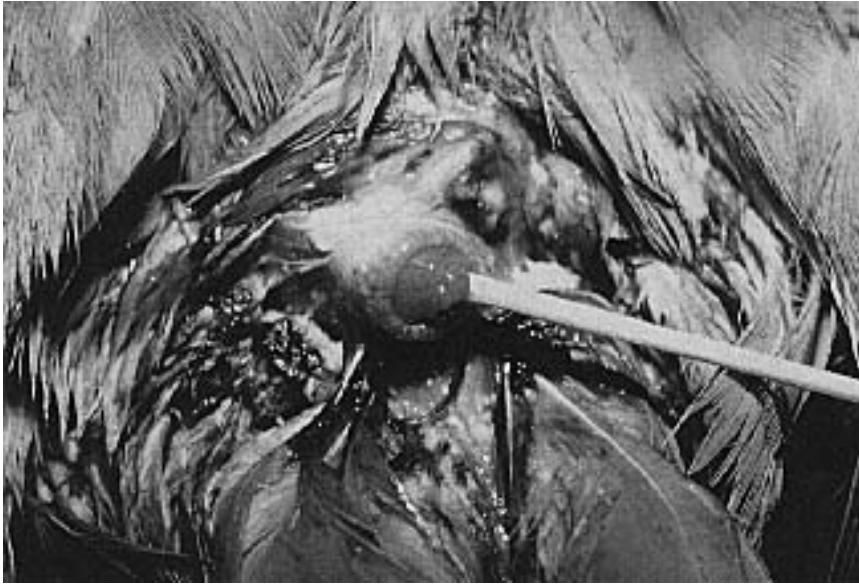Parenteral fluids should be administered to meet maintenance levels and replace estimated fluid volume lost to diarrhea. Debilitated birds may benefit from intravenous or intraosseous fluids and one dose of rapidly acting corticosteroids. Parenteral administration of a bacteriocidal antibiotic with a broad gram-negative spectrum is indicated because bacterial enteritis is common with diarrhea either as a primary cause or as a secondary problem.

### Cloacal Prolapse

Prolapse of the cloacal mucosa is associated with masses within the cloaca, neurogenic problems or conditions causing tenesmus (eg, enteritis, cloacitis or egg-binding). Idiopathic prolapses are seen also.

A prolapsed cloaca may not be immediately apparent to the owner unless the bird is seen self-traumatizing the area or there is blood on the droppings. The history should include questions about diarrhea, straining or previous egg laying. Abdominal palpation for a mass and checking for prolapse of the ureters or uterus should be a priority during the physical examination. Cloacal tumors, such as adenocarcinomas, tend to be single and discrete. An irregular, “raspberry-like” appearance of the mucosa suggests cloacal papillomatosis (see Color 19).

Diagnostics and treatment are best performed with the bird relaxed under isoflurane anesthesia. Fecal retention is a problem with long-standing prolapses and with neurogenic etiologies (see Color 19). Man-



**FIG 15.15** A mature Amazon parrot was presented with chronic diarrhea. On physical examination, an accumulation of excrement was noted in the pericloacal area and on the tail feathers. The cloacal mucosa was examined using a moistened cotton-tipped applicator. A tentative diagnosis of papillomatosis was made by identifying small, pink nodules on the cloacal mucosa (courtesy of Elizabeth Hillyer).

ual massage of the caudal abdominal and cloacal regions promotes fecal evacuation. Parenteral fluid therapy and treatment for septic shock should be used in these cases.

A complete examination of the cloacal area must be performed. In larger birds, a vaginal speculum and strong light source permit examination deep into the cloacal region. Diagnostic tests to consider include fecal wet mount, Gram's stain, culture and radiographs. If cloacal papillomatosis is suspected, tissue excision with biopsy is necessary to confirm the diagnosis. A prolapsed cloaca caused by papillomas does not require a purse-string suture preoperatively. In fact, purse-string sutures in birds with cloacal papillomas may result in blockage of the cloacal opening and are thus contraindicated. Solitary tumors should be biopsied by excision if possible.

Prolapsed mucosa should be protected from damage and desiccation. The tissues should be flushed with saline and covered with a sterile lubricating jelly or ointment. The need for a retention suture will vary depending on the individual bird and the clinician's preferences. Retention sutures may complicate the prolapse by exacerbating straining and should be avoided if at all possible. If a retention suture is placed, it must not interfere with evacuation of the cloaca.<sup>24</sup> A cloacapexy may be necessary in some birds

that chronically prolapse (see Chapter 41). It is important to treat any possible underlying cause of prolapse such as hypocalcemia or other nutritional or metabolic problems.

### Liver Disease

As in mammals, liver disease is often difficult to diagnose and characterize in birds (see Chapter 20). Clinical signs of hepatitis are often nonspecific, including lethargy, inappetence, polyuria, polydipsia, diarrhea and ascites. Birds with ascites are often tachypneic or dyspneic. The presence of yellow or green urates is an indicator of probable liver disease (see Color 8). On physical examination, an enlarged liver may be palpable or, particularly in passerine birds, may be visible through the skin.

The basic database for suspected hepatitis includes a complete blood count, serum biochemistry profile, bile acids, fecal Gram's stain, fecal culture, cytology of the abdominal fluid, whole body radiographs and chlamydial testing.

While laboratory tests are pending, treatment for suspected liver disease includes basic supportive care, broad-spectrum antibiotics, oral lactulose and at least one dose of parenteral vitamin K<sub>1</sub>. Doxycycline is the drug of choice for chlamydiosis. Metronidazole, cephalosporins and the penicillins are the antibacterials of choice for small mammal hepatic infections. Investigations to determine the best antibiotics for avian hepatitis have not been performed.

### Pancreatic Disease

Primary pancreatitis is seldom diagnosed in birds, but is occasionally found at necropsy.<sup>17a</sup> Bacterial, viral and chlamydial infections of other organs may spread to the pancreas causing secondary problems. Acute pancreatic necrosis in an Umbrella Cockatoo<sup>38</sup> and pancreatic atrophy in a Blue and Gold Macaw<sup>40</sup> have been described. The underlying cause was not found in these two birds; however, it was speculated that obesity and a high-fat diet contributed to disease in the cockatoo.

Clinical signs of pancreatitis may include inappetence, lethargy, weight loss, polyuria, polydipsia, ab-



dominal distension and abdominal pain. Pancreatic exocrine insufficiency results in polyphagia, weight loss and bulky, pale droppings (see Color 8).

A CBC and a biochemical profile that includes amylase and lipase levels are indicated. In cases of acute pancreatitis, a radiograph may demonstrate a hazy or fluid-filled abdomen. Initial treatment should include aggressive parenteral fluid therapy and broad-spectrum antibiotics. One dose of rapidly acting corticosteroid may be beneficial in some birds. Plant enzymes (rather than canine pancreatic enzymes) can be added to the tube-feeding formula to help with digestion (see Chapter 18). Vitamin E and selenium should also be given, and the bird tested for zinc toxicosis.

## ■ Urogenital System

### Egg Binding

Egg binding is most common in hens that are on a poor diet, are first-time egg layers or are prolific layers. Problems are most common and most severe in smaller species such as cockatiels, budgerigars and finches. Egg-laying is metabolically demanding, requiring large expenditures of protein, calcium and fat. Lack of sufficient dietary calcium, protein and trace minerals such as vitamin E and selenium will predispose to egg binding by resulting in soft-shelled eggs and uterine atony. Hypovitaminosis A is often a contributing factor due to alteration of mucosal integrity.

Clinical signs of egg binding include lethargy, inappetence, abdominal straining and remaining fluffed on the bottom of the enclosure. Owners often report "diarrhea." Droppings often tend to be large and wet due to cloacal relaxation associated with egg laying. In some birds there is a lack of droppings due to the egg's interfering with normal defecation. The owner should be questioned about previous egg laying activity and for clues that would suggest nesting behavior (eg, paper-shredding, hiding under papers or in dark places and nest building).

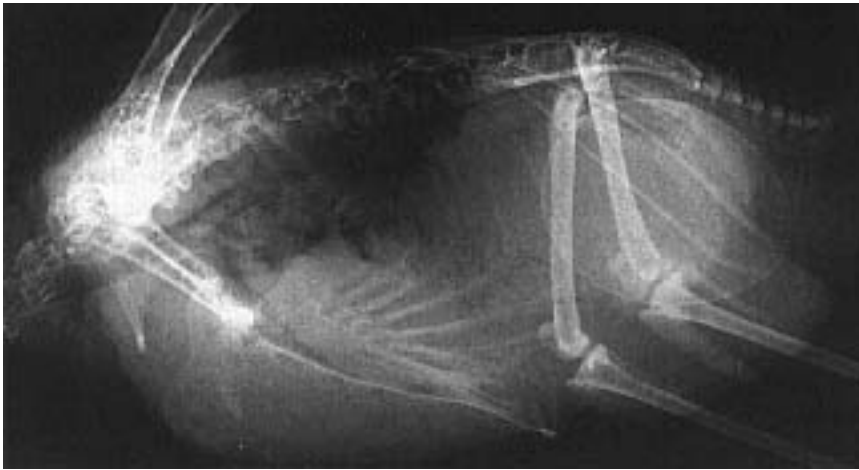
On physical examination, the hen may appear weak and quiet. Tachypnea is common. Unilateral or, less commonly, bilateral leg lameness or paresis occurs if the egg is pressing on the ischiatic nerve as it runs through the pelvic region. In most cases an egg is palpable in the abdomen. If the egg is poorly calcified, it may not be palpable but the abdominal region will be moderately swollen and soft. The cloacal region is often swollen also. Whole body radiographs can be

used to confirm the diagnosis. Medullary bone formation, also termed hyperostosis or osteomyeloclerosis, occurs under the influence of female reproductive hormones and is seen especially in the femur, tibiotarsus, radius and ulna (see Figure 12.65).

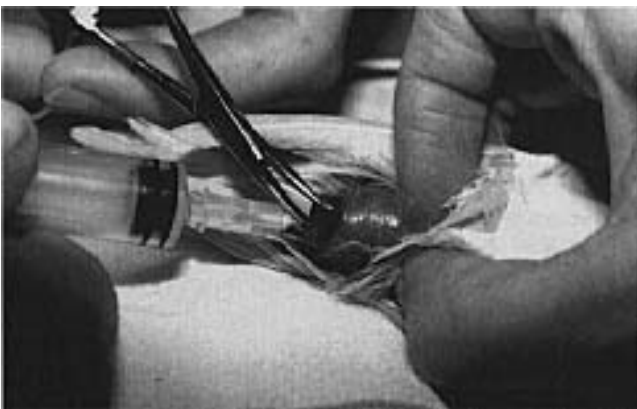
Occasionally, the presence of an egg with a non-calcified shell may be difficult to distinguish radiographically from egg-related peritonitis or an abdominal mass. In this case, a repeat radiograph approximately one hour after the administration of barium may aid in localizing internal structures. An alternative is to administer supportive care, calcium, vitamins and antibiotics, and then to repeat the radiograph one to two days later, assuming that an egg would have calcified or passed in that time period. Uterine rupture is possible, and will negate this last assumption (see Chapter 41).

Conservative medical treatment for egg binding is often successful and should always be given a chance to work before more aggressive therapy is instigated. Decisions regarding therapy should be based on the bird's clinical condition, but in most cases, it is best to allow up to 24 hours of medical therapy before initiating more aggressive steps. Even with paresis of a leg, it is best to attempt medical therapy first because the paresis usually resolves once the egg is passed. Small birds such as finches may require earlier intervention.<sup>19</sup> The real emergency associated with a retained egg is that it may place excessive pressure on internal pelvic structures, such as the caudal poles of the kidneys, where ischemic renal necrosis may occur (Figure 15.16). In contrast, some birds are not clinically ill from egg binding. An example is an egg-bound budgerigar that the authors treated medically for six months because the owners refused surgery.

Medical therapy for egg binding includes fluids, lubricating the cloaca, supplemental heat and parenteral calcium, vitamin A and vitamin D<sub>3</sub>. If the bird is anorectic, oral dextrose or a small gavage feeding may be given, and the bird should be placed in a warm, moist environment such as an incubator containing wet towels. (An old-fashioned, sometimes successful, therapy for egg binding is to submerge the caudal portion of the bird in a bowl of warm water for five to ten minutes!) After one or two doses of calcium, an injection of oxytocin may promote egg passage. Prostaglandin may be more effective in facilitating the passage of an egg than oxytocin (see Chapter 29).



**FIG 15.16** An adult Amazon parrot was presented with an acute onset of lethargy and mild dyspnea. Abnormal clinical pathology changes included WBC=22,400, Ca=28.5 and LDH=750. A hard mass, suspected to be an egg, was palpable in the caudal abdomen. Radiographs indicated a calcified egg in the caudal abdomen and hyperostosis. The high Ca level, elevated LDH activity and hyperostosis in the femur are all common with egg laying. This bird delivered a normal egg the day after evaluation.



**FIG 15.17** A cockatiel hen was presented for depression, straining to defecate and rear limb ataxia. A firm mass was palpable in the caudal abdomen and an egg could be visualized through the urodeum using a small otoscope cone. The bird was given five percent dextrose SC, calcium and oxytocin IM and the cloaca was lubricated with a water-soluble jelly. The bird was placed in a warm incubator. One hour later, the bird was re-evaluated and had not improved. The egg was gently pinched into the cloaca, the egg contents were removed with a needle and syringe, and the egg was collapsed. The fragments of the egg were removed with hemostats. The bird was given SC fluids and corticosteroids and placed back in the incubator. The bird had returned to normal and was eating within three hours (courtesy of Kathy Quesenberry).

If the egg has not passed in 24 hours, or if the bird appears to be weakening, two nonsurgical techniques can be considered. The first works best if the egg is low in the abdomen. With the bird under isoflurane anesthesia to achieve full relaxation, the egg may be manually pushed caudally so its tip is visible through the uterine opening into the cloaca (see Chapter 29).

An 18 to 22 ga needle is inserted into the egg, the egg contents are withdrawn, the egg is carefully imploded and the egg shell fragments are withdrawn using a small hemostat (Figure 15.17). Generally, the hen will pass any remaining egg shell fragments within several days.

The second technique is transabdominal aspiration of egg contents using a large gauge needle (see Chapter 29). The egg is manipulated to the ventral body wall and the egg contents are removed with a syringe. The egg is then gently imploded, relieving pressure on pelvic structures. Supportive care and calcium are continued until the bird delivers the egg shell on its own. Some clinicians flush the uterus for several days to prevent feces from contaminating the traumatized uterus. The positive or negative effects of this procedure have not been studied. The disadvantage of this technique is that occasionally a hen does not pass the egg shell fragments, necessitating a hysterectomy.

Surgical removal of the egg via laparotomy is necessary if the uterus is ruptured, if an egg cannot pass due to adhesions or other causes, or if there are multiple eggs (see Chapter 41).

### Uterine Prolapse

Uterine prolapse containing an egg is common, particularly in budgerigars. Occasionally the uterus will prolapse without the egg. Both conditions probably result from constant straining coupled with muscle weakness due to nutritional deficiencies or physical exhaustion.

The bird is anesthetized with isoflurane to allow careful examination of the prolapsed tissue. While the bird is anesthetized, SC or IV fluids, parenteral calcium, vitamins A and D<sub>3</sub> and a broad-spectrum bacteriocidal antibiotic are administered. One dose of a rapidly acting corticosteroid is appropriate if the bird appears to be in shock. The ureters, rectum and cloaca will sometimes prolapse with the uterus. The prolapsed tissue should be flushed with sterile saline and replaced with a lubricated blunt probang, sterile swab or other sterile, blunt instrument (see Color 29).

Oxytocin or prostaglandin (see Chapter 29) applied directly to the uterus will help reduce swelling and

control bleeding. If an egg is in the prolapsed tissue, the open end of the prolapse should be identified and the egg contents aspirated with a needle to gently collapse the egg. The egg is usually tightly adhered to the fine, transparent uterine tissue, which should be liberally moistened with warm sterile saline. A moist, sterile swab will help gently peel the uterine tissue from the egg without tearing. The prolapsed tissue should be flushed again and replaced as described. The need for a retention suture in the cloaca is based on clinical judgment.

The prognosis for recovery depends on the extent of tissue trauma. In the authors' experience, many hens respond well to therapy even if the replaced uterine tissue appears severely desiccated or inflamed. Antibiotic therapy for five to seven days is recommended. Any remaining necrotic areas should be exteriorized and amputated. The necrotic areas are sutured with 4-0 or 5-0 absorbable suture material, being careful to avoid the ureters.<sup>19</sup> Most birds will temporarily cease egg laying after the trauma and illness associated with uterine prolapse. After the bird is stable, a hysterectomy may be necessary to prevent future egg-related problems.

#### **Egg-related Peritonitis**

Egg-related peritonitis is thought to occur because of a failure of the ovum to enter the infundibulum. The peritonitis that occurs is usually sterile, but may be complicated by secondary bacterial infection. The condition is seen most commonly in cockatiels, lovebirds and budgerigars, but can occur in any hen.

The history usually includes a gradual onset of lethargy, weakness, inappetence, tachypnea and dyspnea. Nesting or egg-laying behavior often precedes the onset of illness. Occasionally, a bird will show no clinical signs other than tachypnea or dyspnea related to fluid accumulation in the abdomen. The clinical presentation of egg-related peritonitis varies with the species. Ascites is most common in cockatiels.

On physical examination, the bird is found to have a fluid-filled, distended abdomen. If the bird is dyspneic, it should be placed in an oxygen-rich environment prior to diagnostics and treatment. Abdominocentesis is performed with a 23 or 25 ga butterfly catheter or an appropriately sized needle and syringe (see Chapter 10). Only a sufficient volume of fluid to relieve the dyspnea should be removed. The needle is passed into the abdomen just below the end of the keel. Care should be exercised to prevent laceration

of the liver if hepatomegaly is suspected. Fluid drainage can be attempted from several sites, choosing avascular areas of skin. Fluid may range from yellow to rust-colored and may be clear or cloudy. More than one abdominocentesis may be necessary. Some veterinarians prefer to place a Penrose drain to allow a continuous port for fluid removal.<sup>19</sup>

Fluid analysis and cytology, a CBC and whole body radiographs should be performed. Radiographic changes are characterized by a fluid-filled abdomen with loss of detail. Increased ossification in the long bones suggests that calcium is being stored for impending ovulation. Parenteral fluids, a broad-spectrum antibiotic and an anti-inflammatory dose of corticosteroid should be administered. Although corticosteroids should be used with caution in birds, low-dose corticosteroid therapy for two to five days in conjunction with antibiotics appears to be beneficial in birds with egg-related peritonitis. A course of medroxyprogesterone acetate is a common companion therapy to steroids (see Chapter 29). A laparotomy and abdominal lavage may be necessary in birds with severe or non-responsive egg-related peritonitis (see Chapter 41).

#### **Renal Failure**

Renal failure is uncommonly diagnosed in avian medicine (see Chapter 21). Possible causes include some toxicities, ureteral obstruction and trauma (such as occurs with egg binding) and bacterial, viral, fungal or parasitic infections.

Clinical signs include polyuria, polydipsia, inappetence, depression and dehydration. Uric acid deposits may be visible on joint surfaces. The basic database consists of a CBC, biochemistry analysis, urinalysis, fecal Gram's stain and fecal culture.<sup>52</sup> Radiographs are useful to evaluate the size and density of the renal shadows. Uric acid deposits are radiolucent but renal mineralization will be visible on radiographs.

Emergency treatment consists of subcutaneous or intravenous fluids, antibiotics and a multi vitamin injection. The latter would be contraindicated if hypervitaminosis is suspected (eg, vitamin D toxicosis in macaws).

### **Respiratory System**

#### **Dyspnea**

Dyspnea in birds is characterized by open-mouthed breathing, prominent abdominal excursions and tail-bobbing with respiration. Causes of dyspnea can be

divided into two categories: primary respiratory and extra-respiratory disease. Primary respiratory disease occurs in the trachea, lungs or air sacs and may be caused by viral, bacterial, fungal, parasitic, chlamydial and mycoplasmal infections, inhaled toxins or foreign body aspiration. Extra-respiratory diseases can cause dyspnea by interfering with normal air flow patterns through the respiratory tree or by limiting expansion of the lungs and air sacs. This category includes thyroid enlargement, abdominal masses, abdominal fluid and oral masses such as papillomas. Birds with severe rhinitis, impacted nares, choanal atresia or sinusitis may also show open-mouth breathing and a tail-bob because they cannot breathe through the nares. Anemia may also induce dyspnea (see Chapter 22).

A thorough history should include questions regarding the possibility of exposure to other birds or to air-borne toxins, the possibility of foreign body aspiration and recent evidence of crop stasis or ileus, which may lead to aspiration. Before a dyspneic bird is handled, it should be carefully observed for conjunctivitis, swollen sinuses, nasal discharge and respiratory sounds. Budgerigars with goiter may have a high-pitched voice or a squeak with each respiration. These birds are also prone to crop-emptying problems and may have a dilated crop. Birds with infectious respiratory conditions often have conjunctivitis, swollen sinuses or nasal discharge. Mynah birds and toucans may develop cardiomyopathy or iron-storage hepatopathy, resulting in ascites and dyspnea. Egg binding or egg-related peritonitis should be considered as a cause of dyspnea if the bird has a history of egg laying. The bird should be placed in an oxygen-rich environment while diagnostic and treatment plans are being formulated.

Some birds may benefit from immediate placement of an air sac tube (see Figure 15.10) while diagnostic tests are performed. If a bacterial pneumonia or air sacculitis is likely, antibiotics may be administered by nebulization in order to minimize handling. Alternatively, the bird may be anesthetized with isoflurane to collect diagnostic samples and initiate therapy. Initial diagnostic tests should include radiographs, CBC, biochemistry profile, abdominal fluid analysis (if present) and tracheal wash. Birds with ascites or egg-related peritonitis will often improve once the abdominal fluid is removed. Early in the course of therapy, enough fluid should be withdrawn to relieve dyspnea and provide a diagnostic sample. In theory, sudden withdrawal of too much fluid can cause hypovolemia and shock;<sup>11,19</sup> however,

in practice, the authors have not experienced this problem. A 23 to 25 ga butterfly catheter or fine-gauge needle and syringe are used to aspirate from several sites through areas of avascular skin.

A tracheal wash should be performed just before the bird recovers from anesthesia. A sterile catheter or tube is passed into the tracheal opening. With the bird held parallel to the floor, sterile saline (up to 10ml/kg) is infused into the trachea and immediately aspirated. Cytology and bacterial and fungal culture can be used to evaluate the aspirated material.

General supportive care, including fluid therapy, heat, vitamins and nutritional support, is administered according to the patient's ability to withstand handling. Specific therapy is given according to the differential diagnosis (see Chapter 22).

### Acute Dyspnea

Acute onset of dyspnea in a previously healthy bird is usually due to one of three causes: 1) inhalation of a toxin, 2) plugging of the trachea by dislocation of an infectious plaque from the choana or tracheal bifurcation or 3) inhalation of a foreign body such as seed or bedding material. Inhalation of small seeds by cockatiels is common.

When a blockage of the upper respiratory tract is suspected, an air sac tube will provide immediate relief of dyspnea. The bird can be anesthetized by administering isoflurane through the air sac tube, making it possible to examine the trachea endoscopically. In smaller birds, transillumination of the trachea may be used to identify tracheal foreign bodies. Radiographs often demonstrate the site of obstruction and will also allow for evaluation of the lungs and air sacs. Removal of a tracheal foreign body is accomplished using suction or a biopsy forceps. In some cases it may be necessary to perform a tracheotomy by incising between tracheal rings just distal to the foreign material. The foreign body is retrieved with biopsy forceps or pushed up and out of the trachea using a blunt probang.<sup>19</sup>

### Air Sac Rupture

Rupture of an air sac often results in a balloon-like deformity of the skin (see Figure 22.12). While the clinical appearance is quite alarming to owners, the problem is rarely a true emergency. Rupture of a cervicocephalic air sac in small birds is most common. The rupture is usually acute, but gradual onset is seen also. Most birds are reported to be otherwise normal and the cause of the rupture is not identified.

On physical examination, a soft, air-filled swelling is palpable. The swelling will involve the head and neck region when the cervicocephalic air sacs are involved. A small needle and syringe can be used to aspirate some air and confirm the diagnosis. A medical workup should be considered if the bird is showing clinical signs of illness, particularly those associated with respiratory disease.

Initial treatment for air sac rupture involves making a percutaneous fistula to allow for continued drainage of air. This relieves pressure on the site of rupture to allow for healing. A rapid, simple technique is to use a hand-held ophthalmic cautery<sup>o</sup> to make a one to two centimeter opening in an avascular area of skin over the swelling, causing rapid deflation. Occasionally the swelling may recur when the fistula closes and the technique must be repeated, making a larger fistula. Surgical repair may be necessary in some birds if initial treatment fails (see Chapter 41).

## Neurologic System

### Head Trauma

Companion birds are often presented with head trauma caused from flying into ceiling fans, mirrors, windows and walls. Free-ranging birds may be injured by colliding with buildings, windows or automobiles.

Birds frequently recover from seemingly severe head trauma. Examination should include visual assessment for alertness and neurologic signs, an evaluation for shock, and examination of the cranium, eyes, nares and ears for evidence of fractures, hemorrhage or bruising. If the trauma is recent, treatment consists of IV or IM rapidly acting corticosteroid and placement of the bird in a dark environment maintained at a comfortable (cool) temperature. A warm environment may potentiate intracranial vasodilation. If the bird is in shock, IV fluids are given at one-half to two-thirds of the normal volume to avoid overhydration and cerebral edema. The use of diuretics is controversial in mammals with head trauma,<sup>59</sup> but mannitol or furosemide may be beneficial if the bird does not respond to initial therapy. Short-term monitoring consists of neurologic evaluation and measurement of blood glucose.

Birds may be presented with severe neurologic abnormalities from head trauma that occurred several days earlier. If the trauma occurred over 24 hours previously, an empirical course of antibiotics and short-term corticosteroids can be attempted, but this

is usually ineffective. Neurologic impairment may be permanent if the injury is several days old and no improvement is noted following 48 hours of therapy. Long-term corticosteroid therapy should be avoided in such birds.<sup>24</sup>

### Seizures

Although the study of avian neurology is in its infancy, most seizure disorders in birds can be managed effectively, even if the exact cause is not determined. Avian seizures have not been classified according to the criteria used in mammals; however, several different types of seizure activity are seen clinically. Mild seizures are characterized by a short period of disorientation with ataxia and inability to perch. Generalized seizures are characterized by a loss of consciousness, vocalizing, wing flapping and paddling. Partial seizures are characterized by persistent twitching or motor activity of the head or one of the extremities. They can be continuous and chronic, and frequently go unrecognized by the owner because they are less dramatic than generalized seizures.

Causes of seizures in birds include primary central nervous system (CNS) disease resulting from trauma, hyperthermia, vascular accidents, infection or neoplasia, and metabolic problems such as hypocalcemia, hypoglycemia, hepatoencephalopathy, toxin exposure and fat emboli. Idiopathic epilepsy, a diagnosis of exclusion, has been reported in Peach-faced Lovebirds, Red-lored Amazon Parrots, Double Yellow-headed Amazon Parrots and mynah birds.<sup>53,55,56,68</sup> A syndrome of hypocalcemia causing weakness and seizures occurs in African Grey Parrots.<sup>55</sup> Cockatiels and lovebirds may show neurologic signs with an undiagnosed, fear-induced mild flapping of the wings, or occasionally with chlamydiosis. Egg-laying birds often have severe lipemia and may develop fat emboli with resultant neurologic abnormalities including seizures and paralysis. Hypoglycemic seizures occur most commonly in raptors and neonates of other species.

The history should include questions regarding diet, egg laying and possible toxin exposure. Owners rarely can verify heavy metal exposure although it is common in psittacine birds due to their propensity for chewing on toys and household objects. Even toys manufactured expressly for birds should not be assumed to be safe.<sup>67</sup> If the bird is not actively seizing, a full physical and neurologic examination including a CBC, biochemical analysis and blood metal concentration should constitute the minimum database in most cases (see Chapter 37). Radiographs are

useful to evaluate bone quality and screen for metallic particles in the gastrointestinal tract. If the bird is weak or actively seizing, an in-house blood glucose test should be performed. Abnormal values are less than 50% of the published normal reference interval for the species (see Appendix).<sup>44</sup>

While laboratory results are pending, treatment for birds not actively seizing consists of general supportive care. If the bird is seizing on presentation, the first goal of therapy is to stop the seizure activity with IM or IV diazepam. Intravenous phenobarbital should be underdosed and used with caution in birds.<sup>19</sup> If lead or zinc poisoning is a possibility, treatment with CaEDTA should begin immediately. Hyperthermia should be evaluated and treated, and hypoglycemia should be corrected with IV dextrose. Suspected chlamydiosis or other infectious diseases should be treated accordingly.

Seizure activity associated with hypocalcemia is most common in African Grey Parrots and young birds on a poor diet. The African Grey hypocalcemic syndrome is thought to occur because of a lack of compensatory mechanisms to maintain serum calcium levels.<sup>55</sup> The syndrome may actually represent a deficiency of vitamin D<sub>3</sub>; however marginal dietary calcium levels seem to play a role.<sup>68</sup> These birds can have a serum calcium concentration as low as 2.5 mg/ml. Radiographically, the skeletal mineralization appears normal, indicating an inability to mobilize skeletal calcium. Other species that develop hypocalcemia will show decreased bone density, folding fractures and pathologic fractures. Treatment for hypocalcemia consists of parenteral calcium, vitamin D<sub>3</sub> and supportive care.

### Coma

Coma can result from head trauma, toxin ingestion, hyperthermia, CNS infection or neoplasia, cerebral ischemia due to a vascular accident, or severe metabolic disease such as hepatic encephalopathy or uric acidemia. The history should include questions related to the onset of clinical signs and possible trauma, toxin ingestion or inhalation (carbon monoxide) and exposure to viruses or parasites (eg, *Sarcocystis* spp., *Baylisascaris* sp.).

Ensuring a patient's airway and adequate ventilation are of primary importance. Establishing an airway with a tracheal or air sac tube and placing the bird in an oxygen-rich environment or applying positive-pressure ventilation may be necessary. The bird should be given dextrose IV if an in-house test indi-

cates hypoglycemia. Emergency treatment consists of IV fluids (low dose if cerebral edema is a possibility), parenteral corticosteroids and treatment for hyperthermia as necessary. The use of IV diuretics such as mannitol or furosemide should be considered in birds with head trauma and hyperthermia. Bacteriocidal antibiotics or doxycycline for chlamydiosis may be indicated in some patients. The bird should be placed in a dark, cool environment after treatment to discourage cerebral vasodilation and edema.

The prognosis for recovery depends on the patient's progress during the first two days of therapy. Supportive care should include lubrication of the eyes and frequent turning of the recumbent bird as necessary.

### Paralysis of Acute Onset

Paresis or paralysis of one or both legs is seen more commonly than problems with the wings. Possible causes of leg paresis include soft tissue trauma, fractures, osteoporosis, neural infections or vertebral trauma or neoplasia. Fractured leg bones are usually associated with reversible paresis of the foot and toes. Another cause of unilateral or, less commonly, bilateral leg paresis is pressure on the pelvic portion of the ischiatic nerve caused by egg binding or renal or gonadal tumors (see Color 25). Paresis of a wing is indicated by a wing droop. This is most commonly caused by soft tissue or bony trauma. Occasionally lead or other heavy metal toxicity will cause peripheral neuropathy resulting in wing or leg paresis.

A neurologic examination of affected birds should include assessment of cloacal tone, grasping strength of the feet and ability to move the tail (see Chapter 28). Muscles may undergo atrophy in the affected limb. The feathers should be parted with alcohol in order to examine the skin for evidence of bruising or wounds. This technique is useful for detection of fractures. The skin overlying the skull and spine should also be examined.

In many cases, the cause of the paresis or paralysis is evident on physical examination but radiographs may be useful to detect or assess intra-abdominal masses, metallic densities in the GI tract, coxofemoral luxations, or fractures of the spine, long bones or shoulder girdle. If heavy metal poisoning is a possibility, blood levels of lead or zinc can be determined.

Treatment is tailored to the specific condition. Egg binding and fractures are managed routinely. Paretic toes must be taped in the proper perching position to avoid knuckling and resultant damage to the top of the foot. One to three days of corticosteroid therapy

may be indicated in cases of head or vertebral trauma. In general, birds have a good capacity for return to function after the cause of the paresis or paralysis is resolved. An Amazon parrot with a pelvic plexus avulsion, incurred when its foot was trapped between the cage bars, had no perceptible sensation or function of the leg or foot. Treatment consisted of one dose of rapidly acting corticosteroid and seven days of a broad-spectrum antibiotic. A gradual return of sensation began around one month and the bird was back to normal at three months. It is impossible to predict the possibility of recovery with most avian neurologic injuries.

### Chronic Disease With Acute Presentation

Birds are able to hide subtle signs of disease from owners until illness is advanced. The most common avian emergency presented to avian clinicians is a chronically ill bird that has decompensated to the point where the owner finally becomes aware of the illness. These birds are usually debilitated, dehydrated and cachectic. It is important with these patients to minimize stress (eg, loud noises, bright lights and excess handling). These birds generally require therapy for severe dehydration and cachexia. Emaciated birds are frequently anemic. Some birds begin to eat on their own within a short time after the initiation of therapy. Birds that refuse to eat should receive an easily digestible enteral preparation such as Isocal-HCN.<sup>k</sup>

Occasionally a cachectic bird will be presented that is alert and relatively active with a good appetite. The owner may not be aware of the weight loss and may have brought the bird in for another problem. This is a common presentation in birds with tuberculosis and some neoplasias. Although the bird may appear strong, its body fat and glycogen stores are depleted and it may decompensate as easily as birds that appear weaker. Prognosis for cachectic birds is grave.

## Physical Injury

### Animal Bites

Birds that have been attacked by a mammal or another bird are often presented for emergency evaluation. Bite-induced injuries are typically of the crushing and tearing type, often necessitating surgical repair or debridement of damaged tissue (see Chapter 16). Mammal bites are usually from a pet dog or cat. These are true emergencies and require immediate attention due to the pathogenic oral bacteria that are introduced deep into bite wounds. Cat attacks, in particular, are especially dangerous because many

cats carry *Pasteurella multocida* on the gingival tissue and teeth.

Shock therapy is instituted if necessary. For a carnivore bite, treatment with a bacteriocidal antibiotic should begin immediately. Penicillins are the antibiotics of choice for cat bites because of their efficacy against *P. multocida*. All wounds must be flushed with copious volumes of warm sterile saline or 0.05% chlorhexidine. If they are difficult to find, small amounts of alcohol may be used to part the feathers, keeping in mind that there are usually two wounds, one from either jaw, associated with a bite. Puncture wounds must be left open for drainage, but large gaping lacerations may require partial closure.

### Burns

The most common burns in birds occur on the legs and feet. These result when free-flighted birds land in hot cooking oil, hot water or on a hot surface. Burns to the oral mucosa and tongue may occur when birds bite on electric cords (see Color 24).

The treatment for burns involves basic supportive care, topical therapy and prevention of secondary infection while the wounds are healing. Secondary invaders are typically *Staphylococcus intermedius*, streptococci, coliforms and *Pseudomonas* spp. Systemic antibiotics and corticosteroids should be avoided during initial therapy because their use may predispose the patient to immunosuppression and nosocomial infection.<sup>57</sup>

Diligent topical therapy is the key to burn management. The burned areas should be flushed with copious amounts of cool water or saline. Feathers surrounding the wounds should be removed to allow for aeration. Water-soluble, topical antibacterial creams such as silver sulfadiazine<sup>x</sup> should be used instead of greasy or oily medications. If the wound is not infected (Gram's stain of cleansed wound negative for organisms), a hydroactive dressing<sup>p</sup> is beneficial to prevent water loss and promote granulation tissue (see Chapter 16). Wounds should be flushed twice daily and debrided once a day.

Gram's staining and culture and sensitivity of burned tissue may be indicated to monitor for infection. Systemic antibiotic therapy is initiated based on positive culture results. In humans, early surgical closure of burn wounds is beneficial. Perioperative antibiotic therapy may prevent surgically induced bacteremia or endotoxemia.<sup>57</sup>

### Glue Traps

Free-flighted companion birds can become caught in glue traps intended for rodents. Trapped birds usually struggle, entangling many contour and primary feathers in the glue. Unless the bird can be removed from the trap with relative ease, the client should be instructed to bring the bird to the hospital still attached to the glue device.

Removing a bird from the glue entails gentle restraint of the body while freeing one extremity at a time. Feathers may be cut or gently removed. Shock therapy and supportive care should be given as needed. To prevent ingestion, the glue remaining on the bird must be removed before preening activity is allowed. Ether, acetone and water are ineffective. A commercial automobile protectant<sup>a</sup> is nontoxic and can be rubbed gently on affected feathers to remove the glue. This material can be rinsed away with warm water. These agents should be used with caution because some products contain lead (see Chapter 37).

## Exposure

### Oil

The avian veterinarian may be called on to treat free-ranging birds caught in an oil spill, companion birds that have flown into household oils, or birds whose owners have applied greasy, over-the-counter medications as topical mite or wound therapies (see Color 24). Large quantities of oil on the feathers disrupt normal thermoregulatory mechanisms and may result in hypothermia and coma (Figure 15.18). Oil-contaminated birds may also suffer from blockage of the nares and conjunctivitis. Systemic toxicity and GI upset may occur if the oil is ingested during preening.

The goals of treating oil-soaked birds are to reverse shock, prevent or treat hypothermia, provide basic supportive care and remove the oil from the feathers, nares and oral cavity. The bird is wrapped in a towel or thermal blanket to conserve body heat, and shock therapy is initiated if needed. The eyes are lubricated and oil is removed from the nares and oral cavity with a swab. Depending on the bird's tolerance for restraint, it may be necessary to alternate rest periods in a dark, heated environment (95°F) with warm baths (100 to 105°F) to remove the oil. A commercial dish-washing detergent<sup>r</sup> is a safe and effective solvent and is used in decreasing concentrations in sequential baths with thorough warm water rinses in between.<sup>71</sup> When the feathers are clean, the bird is dried with a blow-dryer and placed in a warm environment.



**FIG 15.18** The most life-threatening concern with an oil-contaminated bird is hypothermia. Oil should be removed from the nostrils and oral cavity with cotton-tipped applicators and from the feathers with repeated baths in warm dish-washing detergent (courtesy of J Assoc Avian Vet).

### Hyperthermia

Panting and holding the wings away from the body indicate hyperthermia in birds. Birds do not have sweat glands and do not dissipate heat efficiently. If allowed to progress, hyperthermia results in ataxia, seizures and coma.

The first goal of emergency therapy is to reduce body temperature by placing the feet and legs in cool water and wetting the feathers down to the skin with water or alcohol. If the bird is severely overheated, cool water can be infused into the cloaca, taking care not to induce hypothermia by overzealous cooling. Flunixin meglumine may be used to reduce hyperthermia rapidly and safely. A bird in shock should be given low doses of IV or SC fluids, and one dose of rapidly acting corticosteroid. Mannitol or furosemide may help control cerebral edema.

### Frostbite

Frostbite injuries in birds generally occur on the feet and toes, but may also occur around large metal identification bands that are exposed to freezing temperatures. If the injury is recent, the frozen tissues appear pale, dry and avascular, sometimes with a swollen area proximally. If left untreated, the frozen tissue will become necrotic with an erythematous line of demarcation separating it from viable tissue. Ascending infections and gangrene do not appear to be complications of frostbite in birds.

Treatment of a recent frostbite injury involves gradual warming of the extremity by placing the affected tissue in circulating water baths and increasing the water temperature over a 20- to 30-minute period. If



**QUICK REFERENCE FOR EMERGENCY TREATMENT****ANIMAL BITES**

Parenteral penicillin ASAP  
Clean wounds

**BLOOD LOSS/ANEMIA**

Stop bleeding  
Volume replacement  
(IV or IO fluids)  
Iron dextran  
B vitamins  
Vitamin K<sub>1</sub>  
Blood transfusion  
(PCV <20%)

**BURNS**

Gently remove feathers  
Clean wounds  
Antimicrobial creams  
Hydroactive dressing if not  
infected

**CACHEXIA**

Fluids - IV or IO  
5% dextrose IV or IO  
Oral or parenteral alimentation

**COMA**

Ensure patent airway  
Oxygen-rich environment  
Low dose fluids if dehydrated  
Single-dose corticosteroids  
Mannitol or furosemide

**CPR**

Establish airway - air sac tube  
Ventilate every 4 to 5 secs  
Rapidly press on cranial  
sternum  
Epinephrine and doxapram IC,  
IO, IT

**DIARRHEA**

Fluids (IV, IO)  
Bactericidal antibiotics  
Shock therapy if necessary

**DYSPNEA**

URD - air sac tube  
Oxygen-rich enclosure  
Removal of some ascitic fluid  
Remove tracheal foreign  
bodies (suction or surgery)

**EGG BINDING**

Medical therapy initially:  
Subcutaneous fluids  
Lubricate cloaca  
Prostaglandin  
Parenteral calcium and  
oxytocin  
Dextrose  
oral (50%)  
SC (5%)  
Vitamins A and D<sub>3</sub>  
Supplemental heat

If medical therapy fails:  
Assisted cloacal delivery  
Percutaneous ovoidectomy  
Ventral laparotomy

**FROSTBITE**

Gradual warming in water  
bath  
Increase temperature

**HEAD TRAUMA**

Corticosteroids - IV, IO  
Dark, cool environment  
Minimal fluids - correct shock  
only

**HYPERTHERMIA**

Wet with cool water  
Flunixin meglumine  
Mannitol  
Single dose corticosteroids  
Dry and keep at 85°F

**LIVER DISEASE**

Fluids (IV, IO)  
Lactulose  
Vitamin K<sub>1</sub>  
Doxycycline - if suspect  
chlamydia  
Parenteral penicillin -  
if suspect bacteria

**OIL**

Shock therapy  
Prevent hypothermia  
Bathing in warm detergent

**PANCREATITIS**

Fluids (IO)  
Bactericidal antibiotics  
Single-dose corticosteroids  
NPO if possible

**PROLAPSED CLOACA**

Keep tissues moist and clean  
Replace cleansed tissue  
Correct underlying urogenital  
or GI problem  
Retention suture if necessary

**PROLAPSED UTERUS**

Clean with sterile saline  
Topical oxytocin or prosta-  
glandin to reduce swelling  
Lubricate with water-soluble  
gel  
Replace with blunt probang  
Retention suture if necessary

**REGURGITATION**

Fluids (IV, IO)  
Remove foreign bodies or  
toxins  
Gastric lavage  
Specific toxin antidotes  
Appropriate antimicrobials

**SEIZURES**

Diazepam - IV or IM  
Supportive care  
African Grey Parrots - calcium  
and vitamin D<sub>3</sub>  
Raptors and neonates -  
glucose if needed

**SHOCK**

Fluids (IV or IO)  
Corticosteroids (IV or IO)  
Bicarbonate if acidotic  
Bactericidal antibiotics if septic

**SUPPORTIVE CARE**

Fluids  
Heat  
Vitamin/mineral supplements  
Nutritional support

**TOXINS**

Treat for shock  
Remove ingested foreign  
bodies  
Oxygen for inhaled toxins  
Specific antidotes (see  
Chapter 37)

the tissue becomes necrotic, it can be surgically amputated at a later date (see Chapter 41).

**General Emergency Principles of Toxin Exposure**

Toxicity problems in companion birds are extremely common, with heavy metal poisoning leading the list.<sup>24</sup> Toxins that may enter by the alimentary route include lead, zinc and other heavy metals, various plants, rodenticides and some foods like chocolate (see Chapter 37). Birds are also very sensitive to aerosolized toxins, which include overheated polytetrafluoroethylene (Teflon or other non-stick coatings), tobacco smoke, hair spray, pesticides, paint fumes, naphthalene, ammonia and carbon monoxide. Leaded fumes or dust can cause lead toxicity by inhalation in mammals. Iatrogenic drug toxicities may occur due to species or individual differences in drug metabolism or errors in administration or dosing.

Ingestion of prey animals or contaminated water may expose free-ranging birds to potential toxins, the most common being organophosphates, botulism toxin and lead.<sup>39</sup>

Clinical signs of toxicity vary widely and may include depression, anorexia, diarrhea, regurgitation, dyspnea and neurologic signs including ataxia, seizures, head tilt and peripheral neuropathy. Amazon parrots may have hemoglobinuria with acute lead toxicity. Occasionally a bird will be exposed deliberately or allowed unrestricted access to substances such as chocolate, alcohol or marijuana. Careful and specific questioning is usually necessary to delineate potential toxin exposure.

The first step in treatment of any toxin exposure is to stabilize the patient as necessary with shock and anticonvulsant therapy. If a known toxin was recently ingested, a crop lavage is the quickest method of removal. An ingluvotomy may be necessary to remove solid toxins (see Chapter 41). If more than one-half hour has passed since ingestion, a poison control center should be contacted (see Chapter 37).

Most often, an exposure to a specific toxin cannot be identified. A CBC and biochemistry analysis, blood lead and zinc concentration and radiographs are indicated. Nonspecific treatment for suspected toxicosis includes decreasing further absorption of the toxin from the GI tract, hastening elimination of the toxin and providing supportive care. If heavy metal toxicity is a possibility, treatment with Ca EDTA should be initiated.

**TABLE 15.6 Suggested Equipment for Avian Emergency Practice (items not commonly found in a standard small animal practice)**

- Incubator with temperature control, temperature and humidity sensors, oxygen port
- Nebulizer (ultrasonic)
- Anesthesia machine with isoflurane
- Bipolar radiosurgical unit
- Hand-held ophthalmic cautery devices
- 5-0 and 6-0 absorbable and nonabsorbable suture material
- Endotracheal tubes (2.0 and larger)
- Pre-sterilized air sac tubes of different sizes (shortened endotracheal tubes, red rubber tubes, others)
- 18 to 22 ga spinal needles (for use as intraosseous cannulas)
- 24 ga short, indwelling catheters
- 25 ga butterfly catheters with 3.5 inch tubing
- Buretrol or Control-a-Flow extension sets
- Low-dose insulin syringes (for accurate measuring down to 0.01 cc)
- Leg band cutters
- Metal feeding needles
- Various sizes of red rubber tubes (for crop and GI lavage)
- Catheter-tipped syringes
- Catheter-tip adapters
- Enteral feeding formula
- Seeds, spray millet, other foods for inpatients

If the ingested toxin is still in the GI tract, lavage is performed with saline or activated charcoal. Crop, proventricular and ventricular lavage are best performed with the bird intubated and under isoflurane anesthesia. A tube is passed into the proventriculus per os or a small crop incision is made and a red rubber tube is passed distally. The bird can be held with the head tilted down, and foreign objects and toxins can be retrieved by flushing.<sup>67</sup> The administration of activated charcoal helps to bind toxins and decrease GI absorption.

Saline and osmotic cathartics are used to speed elimination of toxins. Saline cathartics (eg, sodium sulfate [Glauber's salt]) will precipitate heavy metal in the GI tract, decreasing absorption. Psyllium is an osmotic cathartic.<sup>29</sup> For specific toxin therapies see Chapter 37.

#### Products Mentioned in Text

- a. Metamucil, Proctor and Gamble, Cincinnati, OH
- b. Nexaband, Tri-point Medical, Raleigh, NC
- c. Buretrol Add-On Set, Baxter Healthcare Corp, Deerfield, IL
- d. Baxter Healthcare Corp, Deerfield, IL
- e. Vibramycin Hyclate Intravenous, Roerig Division, Pfizer, Inc, New York, NY
- f. Vibravenös, Pfizer, Inc, Zurich; London, Ontario
- g. Boehringer Mannheim Corp, Indianapolis, IN
- h. PEP-E, Phylomed, Plantation, FL
- i. Animosyn II, Abbott laboratories, North Chicago, IL
- j. Liposyn II, Abbott Laboratories, North Chicago, IL
- k. Mead Johnson Nutritionals, Evansville, IN
- l. Ross Laboratories, Columbus, OH
- m. OXA-10 oxygen analyzer, Avtech Systems, San Diego, CA
- n. Reglan, AH Robins, Cherry Hill, NJ
- o. Storz Sure-Temp Surgical Cautery, Storz Instrument Co., St. Louis, MO
- p. DuoDerm hydro-active dressing, Convatec, Squibb, Canada
- q. Armor All Protectant, Armor All Products Corp., Irvine, CA
- r. Dawn dish detergent, Proctor and Gamble, Cincinnati, OH
- s. Lipomul, The Upjohn Company, Kalamazoo, MI
- t. Leadcheck Swabs, Hybrivet Systems, Framingham, MA
- u. Injacom-100, La Roche, Nutley, NJ
- v. Spinal needles, Baxter, Valencia, CA
- w. Gatorade, Gatorade Co., Chicago, IL
- x. Silvadene, Marion Labs Inc., Kansas City, MO

#### References and Suggested Reading

1. **Abou-Madi N, Kollias GV:** Avian fluid therapy. *In* Kirk RW, Bonagura JD (eds): Current Veterinary Therapy XI. Philadelphia, WB Saunders Co, 1992, pp 1154-1159.
2. **Bagley RS, Flanders JA:** The use of totally implantable vascular access systems. *Comp Cont Pract Vet* 12(1):22-27, 1990.
3. **Bartholomew GA, Cade TJ:** The water economy of land birds. *Auk* 80:504-539, 1963.
4. **Birkenkott GP, Wiggins ME:** Determination of dexamethasone and corticosterone half-lives in male broilers. *Poult Sci* 63:1064-1068, 1984.
5. **Bond M:** IME: Intravenous catheter placement. *J Assoc Avian Vet* 6(1):40, 1992.
6. **Bos JH, et al:** Treatment of anemic birds with iron dextran therapy: Homologous and heterologous blood transfusions. *Proc Assoc Avian Vet*, 1990, pp 221-225.
7. **Bracken JM, et al:** A randomized controlled trial of methylprednisolone or naloxone in the treatment of acute spinal cord injury. *New Engl J Med* 58:1405-1411, 1990.
8. **Brown SA, Hall ED:** Role of oxygen-derived free radicals in the pathogenesis of shock and trauma, with focus on central nervous system injuries. *J Am Vet Med Assoc* 200(12):1849-1858, 1992.
9. **Burns RB, Baker B, Birrenkott GP:** Half-life of dexamethazone and its effect on plasma corticosterone in raptors. *Proc Joint Conf Am Assoc Zoo Vet & Am Assoc Wildlife Vet*, 1988, pp 12-13.
10. **Coles BH:** Cloacal prolapse: A recurrent emergency for the practitioner. *Proc Euro Assoc Avian Vet*, 1991, pp 323-331.
11. **Campbell TW:** Cytology of abdominal effusions. *In* Avian Hematology and Cytology. Ames, Iowa State University Press, 1988, pp 41-44.
12. **Degernes LA, et al:** Preliminary report on the use of total parenteral nutrition in birds. *Proc Assoc Avian Vet*, 1992, pp 19-20.
13. **Dorrestein GM:** The pharmacokinetics of avian therapeutics. *Vet Clin No Am Sm Anim Pract* 21(6):1241-1264, 1991.
14. **Duke GE:** Alimentary canal: Anatomy, regulation of feeding and motility. *In* Sturkie PD (ed): Avian Physiology. New York, Springer-Verlag, 1986, pp 289-302.
15. **Dunston WA, Buss EG:** Abnormal water balance in a mutant strain of chickens. *Science* 161:167.
16. **Flammer K:** Psittacine antimicrobial pharmacokinetics: An introduction to enrofloxacin. *Proc Assoc Avian Vet*, 1989, pp 1-2.
17. **Goring RL, et al:** Needle catheter duodenostomy: A technique for duodenal alimentation of birds. *J Am Vet Med Assoc* 189:1017-1019, 1986.
- 17a. **Graham DL, Heyer GW:** Diseases of the exocrine pancreas in pet, exotic and wild birds: A pathologist's perspective. *Proc Assoc Avian Vet*, 1992, pp 190-193.
18. **Harrison GJ:** What to do until a diagnosis is made. *In* Harrison GJ, Harrison LR (eds): Clinical Avian Medicine and Surgery. Philadelphia, WB Saunders Co, 1986, pp 356-361.
19. **Harrison GJ, et al:** Symptomatic therapy and emergency medicine. *In* Harrison GJ, Harrison LR (eds): Clinical Avian Medicine and Surgery. Philadelphia, WB Saunders Co, 1986, pp 362-375.

20. **Harvey-Clark C:** Clinical and research use of implantable vascular access ports in avian species. *Proc Assoc Avian Vet*, 1990, pp 191-209.
21. **Haskins SC:** Management of septic shock. *J Am Vet Med Assoc* 200(12):1915-1924, 1992.
22. **Hoefler H:** Transfusions in exotic species. *Prob Vet Med* 4:625-635, 1992.
23. **In my experience,** roundtable discussion: Clinical therapy. *J Assoc Avian Vet* 5(4):186-191, 1991.
24. **In my experience,** roundtable discussion: Emergency medicine. *J Assoc Avian Vet* 6(1):10-15, 1992.
25. **Joyner KL:** Avicultural emergency medicine. *Proc 60th World Vet Conf*, 1988, pp 390-398.
26. **Kaufman GE, Paul-Murphy JR, Finnegan M:** Preliminary evaluation of the effects of dexamethasone on serum hepatic enzymes, glucose and total protein in red-tailed hawks. *Proc Assoc Avian Vet*, 1988, pp 14-20.
27. **King AS, McLelland J:** Respiratory system. *In Birds: Their Structure and Function*. London, Baillière Tindall, 1984, pp 110-144.
28. **Labato MA:** Nutritional management of the critical care patient. *In Kirk RW, Bonagura JD (eds): Current Veterinary Therapy XI*, WB Saunders Co, 1992, pp 117-124.
29. **LaBonde J:** Avian toxicology. *Vet Clin No Amer Sm An Prac* 21(6):1329-1342, 1991.
30. **Lamberski N, Daniel GB:** Fluid dynamics of intraosseous fluid administration in birds. *J Zoo Wildlife Med* 23(1):47-54, 1992.
31. **Lumeij JT:** Plasma urea, creatinine and uric acid concentrations in response to dehydration in racing pigeons. *Avian Pathol* 16:377-382, 1987.
32. **Lumeij JT, de Bruijne JJ:** Evaluation of the refractometric method for the determination of total protein in avian plasma or serum. *Avian Pathol* 14:441-444, 1985.
33. **Martin HD, Kollias GV:** Evaluation of water deprivation and fluid therapy in pigeons. *J Zoo Wildlife Med* 20(2):173-177, 1989.
34. **Mautino M:** Avian lead intoxication. *Proc Assoc Avian Vet*, 1990, pp 245-247.
- 34a. **McCluggage DM:** Basic techniques in avian medicine. *Proc Mid-Atlantic States Vet Conf*, 1992.
35. **Miller MS:** Avian cardiology. *Proc Assoc Avian Vet*, 1986, pp 87-102.
36. **Otto CM, Crowe DT:** Intraosseous resuscitation techniques and applications. *In Kirk RW, Bonagura JD (eds): Current Veterinary Therapy XI*, Philadelphia, WB Saunders Co, 1992, pp 107-112.
37. **Perry-Clark LM, Meunier LD:** Vascular access ports for chronic serial infusion and blood sampling in New Zealand white rabbits. *Lab An Sci* 41(5):495-497, 1991.
38. **Phalen DN:** Acute pancreatic necrosis in an umbrella cockatoo. *Proc Assoc Avian Vet*, 1988, pp 203-205.
39. **Poppenga RH:** Common toxicosis of waterfowl, loons and raptors. *In Kirk RW, Bonagura JD (eds): Current Veterinary Therapy XI*, Philadelphia, WB Saunders Co, 1992, pp 183-188.
40. **Quesenberry KE, Liu S:** Pancreatic atrophy in a blue and gold macaw. *J Am Vet Med Assoc* 189(9):1107-1108, 1986.
41. **Quesenberry KE:** Avian nutritional support. *In Kirk RW, Bonagura JD (eds): Current Veterinary Therapy XI*, Philadelphia, WB Saunders Co, 1992, pp 1160-1162.
42. **Redig PT:** Fluid therapy and acid base balance in the critically ill avian patient. *Proc Assoc Avian Vet*, 1984, pp 59-73.
43. **Redig PT:** Management of medical emergencies in raptors. *In Kirk RW, Bonagura JD (eds): Current Veterinary Therapy XI*, Philadelphia, WB Saunders Co, 1992, pp 1134-1138.
44. **Ritchie BW:** Emergency care of avian patients. *Vet Med Report* 2:230-245, 1990.
45. **Ritchie BW:** Avian therapeutics. *In: Introduction to Avian Medicine and Surgery*. Assoc Avian Vet, 1991, pp T2:1-18.
46. **Ritchie BW, et al:** A technique of intraosseous cannulation for intravenous therapy in birds. *Comp Cont Ed Pract Vet* 12(1):55-59, 1990.
47. **Rode JA, Bartholow S, Ludders JW:** Ventilation through an air sac cannula during tracheal obstruction in ducks. *J Assoc Avian Vet* 4(2):98-102, 1990.
48. **Rosenthal KR:** Congestive heart failure due to mitral regurgitation in an Indian Hill mynah bird. *Proc Assoc Avian Vet*, 1992 pp 171-173.
49. **Roskopf WJ:** Iron storage disease in an umbrella cockatoo. *Proc Assoc Avian Vet*, 1992, pp 98-107.
50. **Roskopf WJ, et al:** Pet avian emergency care. *Proc Assoc Avian Vet*, 1991, pp 341-356.
51. **Roskopf WJ, Woerpel RW:** Erythremic myelosis in conures: The hemorrhagic conure syndrome. *Proc Assoc Avian Vet*, 1984, pp 213-229.
52. **Roskopf WJ, Woerpel RW:** Kidney disease in a military macaw, a yellow-naped Amazon parrot and an umbrella cockatoo. *Proc Assoc Avian Vet*, 1988, pp 207-218.
53. **Roskopf WJ, Woerpel RW:** Epilepsy in peach-faced and pied peach-faced lovebirds. *Proc Assoc Avian Vet*, 1988, pp 225-229.
54. **Roskopf WJ, Woerpel RW:** Abdominal air sac breathing tube placement in psittacine birds and raptors, its use as an emergency airway in cases of tracheal obstruction. *Proc Assoc Avian Vet*, 1990, pp 215-217.
55. **Roskopf WJ, Woerpel RW:** Psittacine conditions and syndromes. *Proc Assoc Avian Vet*, 1990, pp 432-459.
56. **Roskopf WJ, Woerpel RW, Lane R:** Epilepsy in red-lore amazons. *Proc Assoc Avian Vet*, 1985, pp 141-145.
57. **Saxon WD, Kirby R:** Treatment of acute burn injury and smoke inhalation. *In Kirk RW, Bonagura JD (eds): Current Veterinary Therapy XI*, Philadelphia, WB Saunders Co, 1992, pp 146-154.
58. **Sedgwick C, Pokras M, Kaufman G:** Metabolic scaling: Using estimated energy costs to extrapolate drug doses between different species and different individuals of diverse body sizes. *Proc Am Assoc Zoo Vet*, 1990, pp 249-254.
59. **Shores A:** Craniocerebral trauma. *In Kirk RW, Bonagura JD (eds): Current Veterinary Therapy X*, Philadelphia, WB Saunders Co., 1989, pp 847-853.
60. **Spink RR:** Nebulization therapy in cage-bird medicine. *Vet Med Sm An Clin* 75:791-795, 1980.
61. **Spink RR:** Aerosol therapy. *In Harrison GJ, Harrison LR (eds): Clinical Avian Medicine and Surgery*. Philadelphia, WB Saunders Co, 1986, pp 376-379.
62. **Stauber E, et al:** Effects of increased concentration of inspired oxygen. *Proc Euro Assoc Avian Vet*, 1991, pp 105-114.
63. **Sturkie PD:** Avian Physiology. Ithaca, Cornell University Press, 1965.
64. **Sturkie PD:** Body fluids: Blood. *In Sturkie PD (ed): Avian Physiology*, New York, Springer-Verlag, 1986, pp 102-121.
65. **Tams TR:** Pneumonia. *In Kirk RW (ed): Current Veterinary Therapy X*, Philadelphia, WB Saunders Co, 1989, pp 376-384.
66. **Van Pelt D, Wingfield WE:** Controversial issues in drug treatment during cardiopulmonary resuscitation. *J Am Vet Med Assoc* 200(12):1938-1944, 1992.
67. **Van Sant F:** Zinc toxicosis in a hyacinth macaw. *Proc Assoc Avian Vet*, 1991, pp 255-259.
68. **Walsh MT:** Seizuring in pet birds. *Proc Assoc Avian Vet*, 1985, pp 121-128.
69. **Wells RE, Slocombe RF, Trapp AL:** Acute toxicosis in budgerigars caused by pyrolysis products from heated polytetrafluoroethylene. *Clinical study*. *Am J Vet Res* 43:1238-1242, 1982.
70. **Weeren FR, Muir WW:** Clinical aspects of septic shock and comprehensive approaches to treatment in dogs and cats. *J Am Vet Med Assoc* 200(12):1859-1869, 1992.
71. **White J:** Protocol for the rehabilitation of oil-affected waterbirds. *Proc Assoc Avian Vet*, 1990, pp 153-163.
72. **Whitton GC:** Energy metabolism. *In Sturkie PD (ed): Avian Physiology*. New York, Springer-Verlag, 1986, pp 253-268.