

**A**vian practitioners with a general understanding of Anseriformes are needed to care for valuable private waterfowl breeding facilities as well as backyard waterfowl. Waterfowl have generally been treated on a flock rather than an individual basis; however, a flock approach to rare birds, pets or small collections is usually not accepted by the client. Waterfowl aviaries are frequently plagued by problems associated with overstocking, poor management practices, and pathogen-contaminated ground or water.<sup>37,51,39,108</sup>

Veterinarians who plan to treat free-ranging or captive Anseriformes in the United States should be aware of pertinent federal and state laws. The Migratory Bird Treaty Act involves the US, Mexico, Canada and Japan, and provides federal protection for all free-ranging birds in the US except for resident exotic species such as the English sparrow, starling, feral pigeon and resident game birds such as pheasant, grouse and quail. It is unlawful for anyone to kill, capture, collect, process, buy, sell, trade, ship, import or export any migratory birds, eggs, nests or part thereof without first obtaining an appropriate federal permit. These regulations do not necessarily apply to waterfowl species not indigenous to North America. Most states also have their own regulations.

The state requirements for interstate shipment of Anseriformes vary. Some states require testing for *Salmonella* sp., avian influenza, exotic Newcastle disease virus and duck plague virus before an import permit is issued. The state veterinarian's office in the destination state should be contacted to determine specific requirements.

CHAPTER

46

ANSERIFORMES

John H. Olsen

## Biology

### Family and Subfamily Characteristics

Anseriformes have nostrils that connect with one another and a lower mandible with a long process at the angle. The sternum has two indentations or foramina at the rear. Two pairs of muscles are located between the sternum and the trachea. The neck is extended in flight. There are 10 to 11 primaries, the fifth secondary is absent and there are 12 to 24 tail feathers. Down feathers are numerous in the fully developed plumage. The unspotted eggs are light in color. The young are nidifugous, have a dense, downy plumage and are tended for a long time by one or both parents (except in parasitic species that lay eggs in the nests of other birds). The flamingos and the Ciconiiformes (herons, bitterns) are the nearest relatives of the Anseriformes (Figure 46.1).<sup>37</sup>

The Anhimidae are goose-sized birds of fowl-like appearance, with thick, long legs and unwebbed feet. They weigh two to three kilograms.<sup>37</sup> The bill is game bird-like with a downward hook and has none of the filtering fringes (lamellae) common in ducks. Flight feathers are molted gradually so that, like the Magpie Goose, but unlike most waterfowl, they do not pass through an annual flightless period.<sup>39</sup>

The family Anatidae has three subfamilies. Subfamily Anseranatinae contains the Magpie Goose. This bird differs from the rest of the family. The feet are slightly webbed with an unusually long hind toe adapted for semiterrestrial life. The trachea is elongated in adults of both sexes, and in adult males may reach 150 cm long. The trachea is not convoluted inside the sternum as it is in some

swans (Figure 46.2); in contrast, the trachea penetrates the area between the breast muscles and the skin in a manner comparable to that in certain species of Cracidae. The elongated trachea probably functions as an effective resonator producing low-frequency sounds.<sup>51</sup>

Breeding birds often form trios consisting of a male and two females that lay their eggs in a single nest. All the birds share incubation responsibility. Magpie Geese are the only waterfowl species to provide food

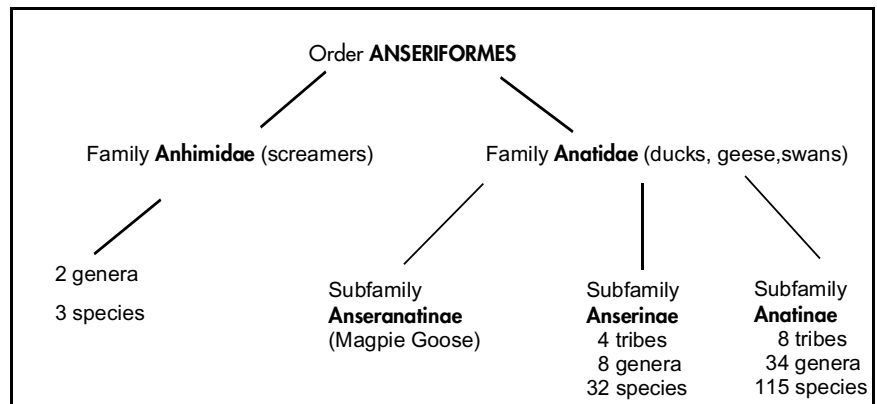


FIG 46.1 The order Anseriformes.

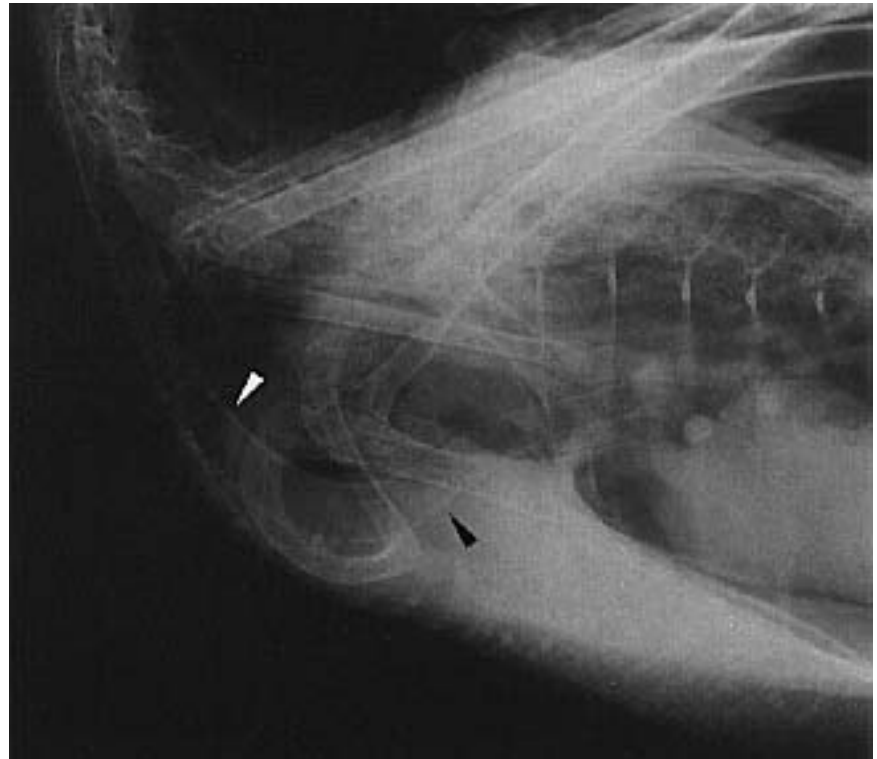


FIG 46.2 The structure of the trachea and syrinx varies among Anseriformes. A syringeal bulla may be present on the left side of the syrinx in male ducks (see Figure 12.16). In this goose, the trachea can be seen to be more elongated (arrows) than in companion birds, and the sternum is broad and less convex than in many avian species.

to their young. The adults deposit proper foodstuffs in front of their downy chicks.<sup>51</sup>

The subfamily Anserinae includes Whistling Ducks, swans, true geese, Cape Barren Geese and Freckled Ducks. These species undergo a complete annual molt following the breeding season. The flight feathers are shed almost simultaneously so the birds are unable to fly for a period of about three to six weeks. The front toes are fully webbed except in two semiterrestrial species of geese. In all species, the plumage is monomorphic and all species lack iridescent coloration, even on the wings.<sup>51</sup>

Subfamily Anatinae includes Sheldgeese, Shelducks and all the typical ducks. Most of the members of this subfamily molt the body feathers twice each year. Consequently, the breeding (nuptial) and non-breeding (winter or eclipse) plumage are distinct. In some species the breeding plumage of the male closely resembles that of the female, but more often, the genders have dimorphic plumage. There is frequently a gender difference in calls as a result of a difference in the structure of the syrinx and sometimes the trachea. The front surface of the lower tarsus has a linearly arranged (scutellated) scale pattern not seen in the other subfamilies. Iridescent coloration is frequently present in the plumage, particularly among males. The male of sexually dimorphic species is typically larger, more brilliantly patterned and more aggressive. The plumage of juveniles and the non-breeding males generally resembles that of the adult female. The patterns of the downy young are often quite contrasting and distinctive, and usually include spotting and striping on the head and back. Males of this subfamily do not assist in incubation but, depending on the tribe, participate in brooding the chicks.<sup>51</sup>

### ■ Diversity of Anseriformes

Waterfowl species range in size from the diminutive Pygmy Goose (300 g) to the Trumpeter Swan (13.6 kg), which has a wing spread approaching 2.5 m (Table 46.1). Normal body weight can vary tremendously with the season.

Although Anseriformes generally surface feed, they may also graze or feed by diving. Some species are omnivorous while others are strictly herbivorous. For example, the Ruddy Shelduck has been observed eating carrion, whereas the algae-eating Pink-eared Duck of Australia has a highly specialized bill for filter feeding.<sup>108</sup>

A few species are widely distributed, such as the Northern Pintail, which is found over nearly the entire northern hemisphere. The Madagascar White-eye, on the other hand, occurs on only a few island lakes. Ducks are usually sexually dimorphic (exceptions: Pekin, Muscovy, American Black and Mexican). Swans and geese are usually sexually monomorphic (exceptions: Magellan and Kelp geese).<sup>56</sup>

Most waterfowl are excellent swimmers, with webbed front toes and short legs. The short femurs, long tibiotarsal bones and extremely short tarsometatarsus bones are adapted for powerful swimming and account for the poor ambulatory abilities and characteristic waddling gait when Anseriformes attempt to walk. The normal speed of swimming for waterfowl is about two to three miles per hour.<sup>108</sup> Most diving ducks stay within 10 to 20 feet of the surface. The Oldsquaw and King Eider are reported to dive at least 180 feet.<sup>108</sup>

Waterfowl are thickly feathered and have compact waterproof plumage and a dense coat of insulating down. A Whistling Swan may have 25,000 feathers, a Green Wing Teal, about 11,500. They have a highly developed uropygial (oil) gland. Frequent preening and oiling is imperative to keep feathers in prime condition so that chilling and sinking do not occur. Waterfowl are generally powerful fliers that cruise with their necks and legs extended. The wing beat of swans is approximately 160 per minute, while some ducks may exceed 300 wing beats per minute. The Canvasback Duck, one of the fastest waterfowl, has been clocked at 70 mph in flight, but normally cruises at 25 to 35 mph. During migration, waterfowl often cruise at 1000- to 3000-foot elevations, but may go as high as 20,000 feet or more.<sup>108</sup>

Ducks have anatomic variations in the syrinx that should not be misinterpreted as pathologic lesions. In most ducks, only the male has a left-sided enlargement of the syrinx (syringeal bulla) (see Figure 12.16). This structure may be responsible for courtship vocalizations. Vocalizations are also used as communication for defense, warning, recognition and flocking signals.<sup>84,108</sup> A syringeal bulla is not present in geese and swans. In swans the trachea is elongated and in the Trumpeter Swan it extends into the sternum, turns on itself and reenters the syrinx (see Figure 12.17).

Many waterfowl species roost on shore where they typically sleep while standing on one leg with the head turned back and the bill inserted into the scapu-

TABLE 46.1 Anseriformes: Body Weight, Eggs/Nest and Incubation Data<sup>8,41,108</sup>

Common Name	Body Weight (grams)		Average Eggs/Nest	Average Incubation in Days
	Male	Female		
<b>SUBFAMILY ANSERANATINAE</b>				
<b>Tribe Anseranatini</b>				
Magpie Goose	2766	2071	8-9	28*
<b>SUBFAMILY ANSERINAE</b>				
<b>Tribe Dendrocygnini</b>				
Spotted Whistling Ducks	800	800	11	30-31*
Eyton's (Plumed) Whistling Duck	788	792	8-14	28-30*
East Indian Wandering Whistling Duck			6-8	28-30*
Fulvous Whistling Duck	675	690	8-16	24-26*
Cuban (Black-billed) Whistling Duck	1150	1150	8-12	30*
Javan (Lesser) Whistling Duck	450-600	450-600	8-10	27-28*
White-faced Whistling Duck	686	662	6-12	26-28*
Northern Black-bellied (Red-billed) Whistling Duck	816	839	12-16	28-31*
<b>Tribe Anserini (Swans and True Geese)</b>				
Coscoroba Swan	4600	3800	4-7	35
Black Swan	6270	5100	4-10	35-40*
Mute Swan	12200	8900	4-8	35-40
Black-necked Swan	5400	4000	4-8	36
Whistling Swan	7100	6200	3-5	30-32
Whooper Swan	10800	8100	4-6	31-40
Swan Goose	3500	2850-3450	5-8	28
Western (Yellow-billed) Bean Goose	3198	2843	4-6	27-29*
Pink-footed Goose	2620	2352	3-5	26-27
European White-fronted Goose	2290	2042	5-6	27-28
Lesser White-fronted Goose	1440-2300	1300-2100	3-8	25
Western Greylag Goose	3531	3105	5-6	24-30
Bar-Headed Goose	2000-3000	2000-3000	4-6	27
Lesser Snow (Blue) Goose	2744	2517	4-5	22-23
Ross's Goose	1315	1224	3-5	20-22
Emperor Goose	2812	2766	4-6	24-25
Nene (Hawaiian) Goose	2212	1923	3-5	29
Atlantic Canada Goose	3809	3310	4-6	28
Barnacle Goose	1672	1499	4-6	24-25
Russian (Dark-bellied) Brant	1410	1410	3-5	22-26
Red-breasted Goose	1315-1625	1150	3-7	23-25
<b>SUB-FAMILY ANATINAE</b>				
<b>Tribe Tadornini (Shelducks and Sheldgeese)</b>				
Crested Shelduck	Unknown	Unknown	Unknown	Unknown
Ruddy Shelduck	1200-1640	950-1500	8-12	27-29
Cape Shelduck	1785	1417	6-13	30
Australian Shelduck	1559	1291	10-14	30-32
New Zealand (Paradise) Shelduck		1260-1340	5-11	30
European (Common) Shelduck	980-1450	801-1250	7-12	28-30
Moluccan (Black-backed) Radjah Shelduck	750	839	6-12	30*
Egyptian Goose	1900-2550	1500-1800	6-12	30
Orinoco Goose		1250	6-8	30
Abyssinian Blue-Winged Goose		1520	4-9	30-34
Andean Goose	2730-3640	Same	5-10	30
Lesser (Upland) Magellan Goose	2834	2721-3200	5-8	30

\*Both parents incubate, others, female only.

## CHAPTER 46 ANSERIFORMES

Common Name	Body Weight (grams)		Average Eggs/Nest	Average Incubation in Days
	Male	Female		
Patagonian (Lesser) Kelp Goose	2607	2607	3-7	30
Ashy-Headed Goose	2267	2200	4-6	30
Ruddy-Headed Goose	2000	2000	5-8	30
Cape Barren (Cereopsis) Goose	5290	3770	3-6	35
Flying Steamer Duck	3073	2616	5-9	30-40
Magellanic Flightless Steamer Duck	6039	4111	5-8	30-40
Falkland Flightless Steamer Duck	4303-4420	3400	5-8	28-40
Patagonian Crested Duck	1070-1180	900	5-8	30
<b>Tribe Anatini (Dabbling Ducks)</b>				
Blue (Mountain) Duck	887	750	4-8	31-32
Salvadori's Duck	462	469	3-4	28*
South African Black Duck		952-1077	4-8	28
European (Eurasian) Wigeon	720	640	7-11	23-25
American (Baldpate) Wigeon	770	680	7-9	24-25
Chiloe Wigeon	939	828	5-8	26
Falcated Duck	713	585	6-9	24-25
Gadwall (Gray Duck)	990	850	8-12	26
Baikal Teal	437	431	6-9	25
European Green-winged Teal	329	319	8-10	21-23
Chilean Speckled Teal	429	394	5-8	24
Cape Teal	419	380	7-8	25-26
Madagascar (Bernier's) Teal			2-4; 8-10	Unknown
East Indian Grey Teal	507	474	4-14	24-25
Chestnut Teal	595	539	9-10	28
New Zealand Brown Teal	665	600	5-7	27-30
Northern Mallard	1261	1084	8-12	23-29
Hawaiian Duck (Koloa)	670	573	6-13	26-28
Laysan Teal		450	4-8	26
North American Black Duck	1330	1160	6-12	26-28
Meller's Duck			8-10	27-29
South African Yellow-billed Duck	954-844	817-677	4-10	27
Indian Spotbill	1230-1500	790-1360	7-9	28
New Zealand Grey Duck	765-1275	623-1275	5-13	28
Philippine Duck	906	779	8-14	25-26
Bronze-winged (Spectacled) Duck	1130	990	4-6	30
Northern Pintail	850	759	8-10	21-26
Chilean (Brown) Pintail	776	705	4-10	26
Lesser (Northern White-cheeked)	474-533	505-633	6-10	25
Red-billed Pintail	617	566	5-12	25-27
Northern Silver (Versicolor) Teal	422	373	7-10	25-26
Hottentot Teal	224-253	224-253	6-8	24-27
Garganey	240-542	220-445	8-11	22-23
Prairie Blue-winged Teal	360	332	10-12	21-24
Northern Cinnamon Teal	408	362	6-14	24-25
Argentine Red Shoveler	608	523	5-8	25
Cape (South African) Shoveler	688	597	5-12	26-28
Australian Shoveler	667	665	9-12	24-28
Northern (Common) Shoveler	410-1100	420-763	7-14	23-28
Pink-eared (Zebra) Duck	404	344	3-11	27
Marbled Teal	240-600	250-550	10-11	25
Freckled (Monkey) Duck	969	842	5-10	26-28

table continued on next page

Common Name	Body Weight (grams)		Average Eggs/Nest	Average Incubation in Days
	Male	Female		
Ringed Teal	190-360	197-310	6-12	26-28
Pink-headed Duck	935	840	5-10	Unknown
Chilean Torrent Duck	440	315-340	3-4	43-44
<b>Tribe Somaterinii (Eiders)</b>				
European Eider	2253	2127	3-6	25-30
King Eider	1830	1750	3-6	22-24
Spectacled (Fischer's) Eider	1630	1630	4-6	24
Steller's Eider	860	860	7-8	22-24
<b>Tribe Aythyini (Pochards)</b>				
Red-Crested Pochard	1135	967	6-12	26-28
South American (Southern) Pochard	600-977	533-1000		
Rosy-Billed (Rosybill) Pochard	1181	1154	8-12	25-28
Canvasback	1252	1154	8-10	24-25
European (Eurasian) Pochard	998	947	6-9	23-29
Redhead	1080	1030	7-8	24
Ring-necked Duck	790	690	8-12	26-27
Australian White-eye (Hardhead)	902	838	9-12	25
Baer's Pochard (Siberian White-eye)	880	680	6-9	27
Ferruginous White-eye	583	520	7-11	25-27
Madagascar White-eye			5-6	26-28
Tufted Duck	1116	1050	6-14	23-25
New Zealand Scaup (Black Teal)	695	610	5-8	27-30
European Greater Scaup	1250	900-1200	8-10	24-28
Lesser Scaup	850	800	8-10	23-25
<b>Tribe Cairinini (Perching Ducks)</b>				
Lesser Brazilian Teal	380-480	350-390	6-8	25
Maned Goose (Australian Wood Duck)	815	800	8-11	28
Mandarin Duck	440-550	440-550	9-12	28-30
North American Wood Duck (Carolina Duck)	680	539	10-15	28-30
African Pygmy Goose	285	260	6-12	23-26
Indian Pygmy Goose (Cotton Teal)	403	380		
Green Pygmy Goose	310	304	8-12	22-24
Hartlaub's Duck	800-940	800-940	9	32
White-Winged Wood Duck	2495-3855	1925-3050	6-13	33-35
Muscovy Duck	2000-4000	1100-1500	8-15	35
Old World Comb Duck	1300-2610	870-2325	8-12	30
(Gambian) Spur-winged Goose	5400-6800	4000-5400	6-15	30-32
<b>Tribe Merginina (Sea Ducks)</b>				
Labrador Duck	864	482		
Atlantic Harlequin Duck	680	540	4-8	28-29
Oldsquaw (Long-tailed) Duck	800	650	6-7	24-26
European Black Scoter	1108	1006	6-9	27-28
Surf Scoter	1000	900	5-7	27-28
European White-winged (Velvet) Scoter	1727	1492-1658	9-10	26-27
Bufflehead	450	330	8-9	30
Barrow's Goldeneye	1110	800	9-11	32
European Goldeneye	990-1158	710-799	9-11	27-32
Smew	540-935	515-650	6-9	28
Hooded Merganser	680	540	9-11	32-33
Brazilian Merganser				

Common Name	Body Weight (grams)		Average Eggs/Nest	Average Incubation in Days
	Male	Female		
Common Red-breasted Merganser	1133-1209	907-959	9-10	32
Auckland Islands Merganser				
Chinese (Scaley-sided) Merganser			8-12	
Eurasian Goosander	1670	1535	9-10	32-35
<b>Tribe Oxyurini (Stiff-tailed Ducks)</b>				
Black-headed Duck	513	565	2	20-25
Masked Duck	406	339	4-6	28
North American Ruddy Duck	550	500	6-9	23-24
White-headed Duck	737	593	6-8	23
Maccoa Duck	450-700	450-700	4-8	24-27
Argentine Ruddy (Blue-billed) Duck	610	560	3-5	23-28
Australian Blue-billed Duck	812	852	5-6	26-28
Musk Duck	2398	1551	1-3	Unknown
African White-backed Duck	650-790	625-765	5-7	29-33

lar feathers. Other species seldom come ashore, preferring to sleep on the water.<sup>108</sup>

Young Anseriformes easily imprint on humans or other species of birds. Pair formation may be difficult in imprinted birds. Homosexual and interspecific pairs are common under captive conditions. Some geese (*Cereopsis* and Egyptian) may be very aggressive and should not be maintained where they can injure animals or children. Imprinted geese and swans of all species can be dangerous to children.

### Physiology

Pulse and respiration rates differ so widely in normal Anseriformes that they have limited value as indicators of disease. In the domestic Pekin Duck the heart rate (HR) varies from 180 to 230 bpm and the respiration rate (RR) from 30 to 95 bpm. Daytime body temperature (BT) is 41°C.<sup>44</sup> In the goose, RR is 13 to 40 bpm and BT is 40.5°C.<sup>111</sup> The values in Table 46.2 illustrate some consistency within these species.

The heart rate slows dramatically when a bird dives and there is an increased use of oxygen in the blood. Heat loss occurs through panting or through the webs of the feet. Anseriformes will try to prevent heat loss through the feet by squatting down on them in cold weather.<sup>44</sup>

Anseriformes from tropical countries (eg, Whistling Ducks) are prone to frostbite and subsequent gangrene of the toes. These species should be housed indoors during freezing conditions. Otherwise, wa-

terfowl are remarkably tolerant of adverse climatic conditions, especially if open water is available for swimming. They can be maintained successfully in most regions of the world.<sup>44</sup>

The growth rate in Anseriformes is usually faster than that of gallinaceous birds. Species from extreme latitudes grow faster than those from low latitudes. Growth rate and egg production appear to be related to day length during the breeding period.<sup>56</sup>

Anseriformes are often long-lived. In captivity, ducks often live 10 to 12 years, and geese and swans commonly live for 25 years or more.<sup>44</sup> Mortality rates in free-ranging birds are high. Smaller duck species survive two to three or possibly up to six breeding seasons. In the first year of life 60 to 70% of the annual hatch die, and 90 to 95% die before three years of age. Some free-ranging ducks are known to survive 16 years and geese, 18 years (Table 46.3).<sup>108,111</sup>

Evaluating blood parameters is a useful diagnostic tool in Anseriformes. Limited data are available on many species, but there is considerable data on Mallard Ducks. Selected serum constituents and hematologic parameters were analyzed<sup>a</sup> from Mallard Ducks of both sexes during several stages of reproduction: pre-egg laying, egg laying, incubating, molting and post-reproductive (see Appendix).<sup>22,23</sup> Similar assays were also conducted on ducklings, 5 to 58 days of age. These findings indicated that clinical chemistry values must be evaluated with respect to sex, age and reproductive status of the birds. Lactate dehydrogenase (LDH), cholinesterase (CHE), alanine aminotransferase (ALT), aspartate aminotrans-



**TABLE 46.2** Compilation of Normal Parameters in Pekin and Muscovy Ducks

Parameter	Pekin Duck <sup>35,67,90</sup>	Muscovy Duck <sup>55</sup>
Cloacal Temperature (°C)	40.5 - 41.6	39.1 - 41.1
Heart Rate (bpm)	150 - 250	
Respiratory Rate (bpm)	13 - 23	
Mean Arterial Blood Pressure (mmHg)	111 - 142.5	
PaO <sub>2</sub> (mmHg)	73 - 109.1	80 - 83
PaCO <sub>2</sub> (mmHg)	28.9 - 43	32 - 39
HCO <sub>3</sub> (mEq/l)	19.6 - 24.8	
Blood pH	7.36 - 7.48	7.48 - 7.53
Tidal volume (ml)	40 - 58	
Minute ventilation (l/min)	0.67 - 0.97	

ferase (AST), creatinine (CRN) and direct bilirubin (BIDI) were the only parameters that did not vary with the reproductive status of the bird. All assays except albumin (ALB), glucose (GLU), calcium (CA) and magnesium (MG) showed age-related changes (see Appendix).<sup>23</sup>

For nonreproductive birds, GLU was the only assay where values differed between males and females. Hens and drakes in pre-egg laying condition had significantly different concentrations of ALB, gamma-glutamyl transferase (GGT), CA, phosphorus (PHOS) and MG. Laying hens differed from drakes in the ALB, amylase (AMY), GGT, CA, PHOS, MG, uric acid (UA) and total bilirubin (BITO) assays. Incubating birds had sex-related differences in ALB, AMY and PHOS concentrations. In molting birds, only AMY differed between the genders.

Egg-laying activity significantly influenced serum enzyme activity and chemistry concentrations, causing increased values in 12 of the 17 assays. Egg-laying hens had a ten-fold increase in GGT during the reproductive periods. AMY doubled during egg laying while other constituents increased by a statistically significant, although lesser, amount. Values of 12 of the assays in samples from the drakes also differed by reproductive condition. GGT activity in molting males was twice their nonreproductive values (see Appendix).<sup>23</sup>

Differential white blood cell counts were also recorded in these test birds. Gender or reproductive state of the adult birds did not significantly change (P) the cell ratio. Non-laying and laying birds had a similar number of thrombocytes, which were significantly greater than thrombocyte counts of incubating, molting or post-reproductive birds. Young birds

**TABLE 46.3** Longevity of Selected Waterfowl<sup>37,39,51,52,108</sup>

Species	Years
Whistling Duck	15
Redhead	16.5
Common Goldeneye	17
Canvasback	19
European Pochard	20
Common Mallard	20
Northern Green-winged Teal	20
Egyptian Goose	25
Greylag Goose	26
Magpie Goose	26
Trumpeter Swan	32.5
Canada Goose	33

had a decrease of the percent lymphocytes from 50 to greater than 60 days of age and a concomitant, compensating increase in percent heterophils. Thrombocyte numbers increased from 5 days of age to a peak at 18 days of age, after which they did not vary significantly.<sup>22</sup>

## Husbandry Practices

### Hospitalization

Anseriformes are relatively easy to restrain. Their primary defenses include scratching with sharp toenails, pinching with their bills, striking with their wings or poking at eyes. A dry, warm enclosure with good footing is suitable for brief hospitalization. When confined, waterfowl sometimes stress, so a quiet, dimly lighted enclosure may be preferable. If longer hospitalization is necessary, an enclosure with an accessible pool and padded flooring<sup>b</sup> is necessary to prevent leg and foot problems. Hard surfaces (concrete) may damage the plantar foot surfaces, eventually promoting bumblefoot. Chain-link enclosures should be protected with burlap or other similar materials to prevent birds from abrading their wings, heads or eyes.

### Housing

Waterfowl are commonly kept as pairs in small, planted, open pens with a small pool or stream, or in large, open, mixed-species groups with a large pond. Most Anseriformes should have an area for swimming to maintain long-term overall health. Open enclosures allow various free-ranging birds to com-



pete for feed and nesting sites and potentially to introduce infectious diseases (Figure 46.3). Pests and predators (rats, snakes, otters, raccoons, bobcats, opossums, hawks, owls and eagles) may also complicate waterfowl maintenance in large open exhibits. Burying the fence line will discourage some predators from digging under the fence, and electric fencing will discourage terrestrial predators. Some aviculturists use small aviary mesh to cover pens to reduce access by free-ranging birds, pests and predators.



**FIG 46.3** While aesthetically pleasing, open enclosures create management problems with respect to free-ranging birds, rodents and predators. A portion of the pond should be protected from the sun, which was accomplished in this enclosure using shade cloth. The pool has gently sloping sides and can be easily drained for cleaning (1994 Busch Gardens Tampa. All rights reserved.).

Covered enclosures allow birds to be full-flighted (most are typically pinioned or wing-clipped to prevent escape from open enclosures). Wing clipping is accomplished by cutting the flight feathers from one wing with a pair of scissors or shears. This procedure impedes flight until the next molt. The feathers should be trimmed at the level of the rachis, not at the level of the hollow calamus. This will reduce the chances of water entering the feather shaft, resulting in algae growth and folliculitis. Pinioning is the amputation of the distal portion of the wing, permanently handicapping a bird's flight abilities.

Large ponds should have islands to provide nesting areas and privacy for the birds. Some birds will nest on small floating platforms. Grazing species, such as geese, require more land area than do diving ducks. Small ducks can be maintained in small planted pens with an elevated cement water container that holds three to five gallons.

A high water flow rate or filtration is important for maintaining clean water and reducing the incidence of disease. Cold water is better for ponds than warm water. Generally, a depth of two feet is adequate for most Anseriformes, although swans and some diving ducks require three to four feet of water.<sup>108</sup> Many waterfowl species require standing water to breed. Anseriformes typically dig or nibble at the pond bank. Lining the banks with concrete blocks, stone or other solid materials will help maintain pond continuity.<sup>44</sup>

The nasal secretions of some marine and semi-marine waterfowl are believed to inhibit the growth of mycotic spores. If these species are maintained in fresh water, the salt glands producing these secre-

tions may atrophy, affecting the bird's ability to resist infections.<sup>44</sup> These birds may die from hypernatremia if they are returned to salt water.


Multiple-species aviaries are frequently constructed with pens arranged in rows and a common stream flowing from pen to pen. This arrangement creates disease control and maintenance problems. Preferably, each enclosure should have an individual pool draining into a common drainage ditch that does not contain animals (Figure 46.4).

Planted aviaries provide nesting materials, shade and privacy for sensitive species. Large, destructive waterfowl, such as swans and geese, require hardy plants. Safe plants that are partially bird-proof include juniper, palm, pine, bird of paradise, coral tree, cycad and natal plum. Geese and other grazing birds do well on golf course fairway grasses (eg, hybrid bermuda) (Figure 46.5). In warm climates, Korean grass (*Zosia* or *Zoysia*) provides a relatively durable, lush ground cover that birds tend not to consume.<sup>108</sup>

Housing is not usually necessary for Anseriformes if they have access to open water. Some very sensitive tropical species may require protection during the winter. Water circulation systems should be used to keep ponds from freezing in the winter. If housing units are necessary, they should contain soft flooring or mats to prevent calluses and abrasions that are common with unprotected concrete floors.



**FIG 46.4** Facilities that are designed with individual enclosures, but a common pool, increase the risk of disease transmission. Preferably, each enclosure should have its own pool that can be drained into a common ditch outside the enclosure (1994 Busch Gardens Tampa. All rights reserved.).



**FIG 46.5** Geese and swans should be provided ample areas for grazing (1994 Busch Gardens Tampa. All rights reserved.).

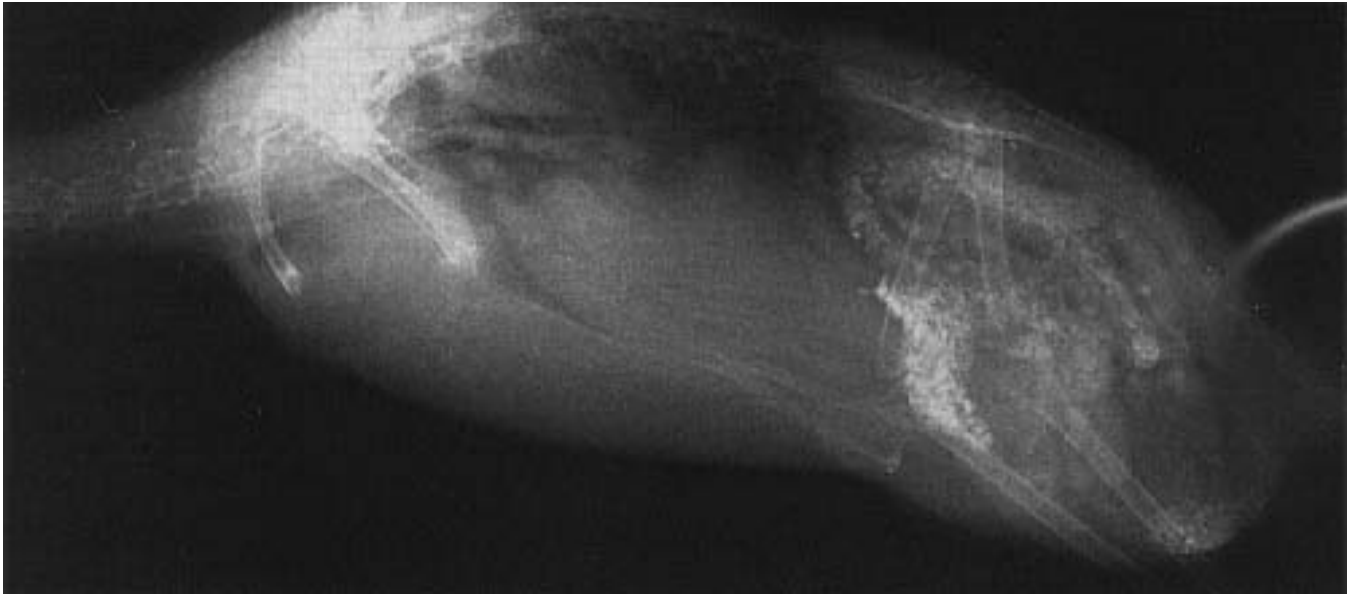
### Nutrition

Considerable nutritional information is available for commercially produced waterfowl; however, very little information is available for nondomesticated species. Because of a lack of extensive research, nutritional recommendations for nondomesticated Anseriformes are often based on observation and opinion.

The types of food consumed, and thus their nutritional components, vary widely between surface-feeding ducks and divers. High protein (28%) gamebird rations are frequently recommended for feeding ducklings; however, it has been found that a ration of 19% protein supplemented with scratch grains on a free-choice basis produced better growth and feed efficiency than higher protein diets (Table 46.4). Diets with 8% animal protein (19% total protein) promoted the best growth. Redhead, Pintail and Canvasback chicks grew best when fed a starting diet containing 2,970 kcal/kg and 19% protein until three weeks of age.<sup>43</sup> After three weeks of age, this pelleted diet was offered free choice with a mixture of cracked corn, wheat and oats or barley (the grain mixture used should depend upon the grains that free-ranging ducks are likely to consume).<sup>97</sup> Amino acid quality of the diet was maintained by the inclusion of 8% fish meal. This diet produced similar results with both dabbling and diving ducks, even though their natural feeding habits differ widely. This did not include species such as the sea ducks and mergansers that feed exclusively on fish.

Rations designed for feeding commercial ducks are not generally recommended for the long-term maintenance of other waterfowl. These diets are designed to produce a carcass to be processed for food and usually contain growth additives and compounds to stimulate feather loss. The fat content in dog foods is much higher than waterfowl can tolerate, particularly when mixed grains are

fed as part of the diet. Most ducks have a tendency to deposit excessive fat in the abdomen and around the heart and ventriculus, and overweight birds frequently die from fatty liver degeneration (see Color 20). Adequate levels of choline chloride have been found to help protect Anseriformes from fatty infiltration of the liver.<sup>45,81</sup>



**FIG 46.6** A 1.5-year-old female duck was presented with a three-week history of anorexia, ataxia and inability to fly. Abnormal clinical pathology findings included WBC=24,000, LDH=479, PCV=36.5. The bird was offered free-choice grit and, for an undetermined reason, engorged on grit, causing an impaction. The bird was given corn oil by gavage tube to facilitate passage of the grit.

Many experienced Anseriforme breeders are convinced that all waterfowl need a high-protein diet, and one pelleted ration is fed to all species. This is an inaccurate and dangerous assumption. Many geese are grazers, and most lush grasses seldom exceed 17% protein. Feeding high-protein diets to these birds can cause terminal renal failure. In addition, excessive water consumption is necessary to remove the extra protein, and a relatively short period of water deprivation can be fatal.<sup>45,81</sup> High-protein diets may also cause developmental abnormalities in the wings and legs.

Diets designed for the long-term health and breeding of Anseriformes are listed in Table 46.4. Chicken, broiler and commercial duck diets are not acceptable for commonly maintained Anseriformes. A turkey ration (20% protein) can be used as an adequate diet for recently hatched ducklings. This should be supplemented with scratch grains when birds are two to three weeks of age. After the birds mature, they can be fed a maintenance diet of 10% turkey grower pellets and 90% mixed grains until laying season begins. If grains are fed to ducklings, their diet should be supplemented with a hard, insoluble granite grit. Various-sized particles should be sprinkled on top of the feed when the ducklings are eating well (about three days of age). Later it can be provided in a separate dish. Some breeders add four percent grit to their pellets (Figure 46.6).<sup>45,81</sup>

### Feeding Habits of Free-ranging Ducks

The fall and winter diets of non-breeding, free-ranging waterfowl depend largely on the kinds of foods available in each particular locality. Gadwalls wintering in Louisiana were found to consume 95.3% vegetable foods and only 4.2% animal matter. White-faced Tree Ducks of Senegal were found to consume primarily seeds, rice, grass, water lilies and tubers. Studies with free-ranging Mallard Ducks have shown that, when given a choice, these birds consumed those foods that were most readily available in volume. When a choice was given between barley, soft wheat, or two varieties of hard wheat, the ducks preferred the barley.

Post-breeding feeding studies of Redhead Ducks at Long Island Sound showed that plant material accounted for over 90% of the total food intake in both males and females. Muskgrass and fennel leaf pond weed were the most important foods. In the breeding season, the females appeared to prefer the tubers and root stalks of this pond weed.

In New South Wales, Black Ducks were found to eat a varied diet including seeds of grasses, swamp plants, legume plants, water snails, water beetles (adults and larvae), water spiders and ostracods, as well as terrestrial invertebrates. In one study, Canvasback hens were found to enter the breeding season with heavy fat reserves and appeared to consume decreased quantities of food throughout the laying

period. Redhead hens were found to forage continuously on the most abundant foods in the marsh. During the laying and incubation periods, the Canvasback hens lost about 68% and the redhead hens, about 76% of their lipid stores.

Female free-ranging ducks seem to instinctively consume more animal materials during the laying period than they do during other times of the year. In male and non-laying female Mallard Ducks, it was found that animal foods represented about 38% of the total food intake. In comparison, animal foods represented about 72% of the diet of laying females. It is possible that ducks increase animal food consumption during breeding for reasons other than an instinctive desire for additional protein.

Studies in chickens have shown that they consume food to satisfy an inner craving for energy. They will increase their consumption of low-energy diets in order to grow and perform normally, but will not increase their consumption of low-protein diets, even when these diets are too low in protein to support normal body requirements. Breeding hens also appear to have an inner instinct that calls for extra consumption of calcium during egg production. When offered graded levels of calcium during the egg-laying period, hens will increase the total food intake when the calcium content of the diet is low. The increase in consumption of animal materials during the breeding season may relate to calcium needs rather than protein.<sup>97</sup>

Free-ranging ducks and geese consume large quantities of energy-rich foods to establish the fat reserves necessary for migration. The same diet fed to captive birds will predispose them to obesity and fat metabolism problems when they are provided excessive quantities of food.

**TABLE 46.4 Diet for Wild Ducklings**

	WILD DUCK STARTER RATION	WILD DUCK GROWER RATION
Ingredient	Pounds per Ton	
Corn meal, No. 2 yellow	933.0	753.0
Oats, heavy, pulverized	200.0	400.0
Wheat standard middlings	300.0	300.0
Soybean oil meal, 50% protein, low fiber	250.0	280.0
Fish meal, 60% protein	160.0	100.0
Fish solubles, dried basis	10.0	10.0
Dried brewer's yeast, 40% protein	20.0	20.0
Whey, dried product, 55% lactose	20.0	20.0
Alfalfa meal, dehydrated, 17% protein (100,000 A/lb)	60.0	80.0
Dicalcium phosphate	10.0	10.0
Calcium carbonate, ground	30.0	20.0
Salt, iodized	5.0	5.0
Manganese sulfate, feed grade	0.5	0.5
Copper sulfate	0.5	0.5
Zinc carbonate	0.25	0.25
DL-methionine (hydroxylanalog)	1.0	1.0
Santoquin		0.25
Vitamin, Unit of Measure	Amount per Ton	
Stabilized vitamin A, USP units	10,000,000	12,000,000
Vitamin D <sub>3</sub> ICU	1,500,000	1,500,000
Vitamin E, IU	5,000	5,000
Riboflavin, grams	3	4
Choline chloride, grams	112	250
Niacin, grams	40	40
Calcium pantothenate, pure D-isomer, grams	6	10
Vitamin K (menadione sodium bisulfite), grams	4	4
Vitamin B <sub>12</sub> , milligrams	6	6
Calculated Analysis (%)		
Protein	20.0	19.0
Fat	6.5	5.0
Fiber	4.0	4.5
Calcium	1.2	1.0
Phosphorus	0.7	0.7

Starter ration to be fed for first three weeks with insoluble grit available at all times. Grower ration to be fed from 21 days of age to maturity with scratch grains free choice. Grit to be available at all times. This diet plus scratch grain free choice can be used as a maintenance ration and for nonlaying breeders (adapted from Hyde<sup>98</sup>).

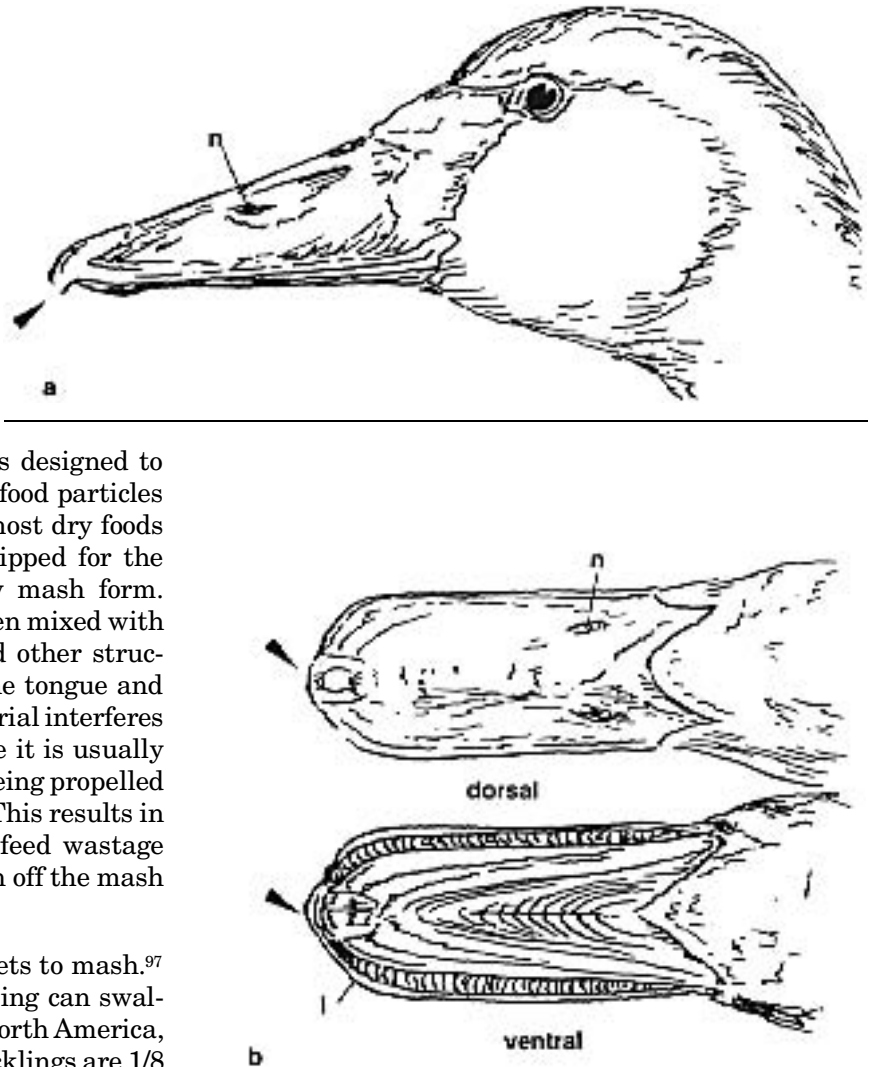
Geese appeared to have a better ability to utilize dietary fiber than ducks.<sup>97</sup> Captive geese did best when provided alfalfa hay in addition to a pelleted ration. Geese do well when fed the same diets recom-

mended for ducks (Table 46.4). A duck starter diet should be provided for four weeks, followed by the duck grower/finisher diet until maturity. Scratch grains should be added to the grower/finisher diet, approximately 50:50, after eight weeks of age.<sup>97</sup>

A duck's ability to gather food from flooded or muddy areas is assisted by cutaneous mechanoreceptors on the bill and tongue, which allow them to quickly differentiate edible from non-edible matter. Taste buds may also assist in this process.<sup>97</sup> A duck's bill is designed to allow efficient straining of submerged food particles (Figure 46.7) as well as the intake of most dry foods of appropriate size. They are not equipped for the consumption of mixed feeds in a dry mash form. Mashings tend to form a sticky paste when mixed with saliva and adhere to the lamellae and other structures bordering the outer margin of the tongue and upper and lower bill. The adhered material interferes with food passing to the tongue, where it is usually rotated and coated with saliva before being propelled back to the esophagus and swallowed. This results in a reduced food intake and increased feed wastage because the duck tries to shake or wash off the mash sticking to its mouth parts.<sup>97</sup>

When given a choice, ducks prefer pellets to mash.<sup>97</sup> The maximum diameter pellet a duckling can swallow easily dictates acceptable size. In North America, the two most common sizes used for ducklings are 1/8 inch (3.18 mm) and 5/32 inch (3.97 mm), with the latter being the maximum size for newly hatched Pekin ducklings. Starter pellets should not exceed a length of 5/16 inch (7.94 mm). Pekin ducklings can eat pellets 3/16 inch (4.76 mm) in diameter and about 1/2 inch (12.7 mm) in length by two weeks of age.<sup>97</sup>


Feeding containers for ducks should be several inches deep and at least one foot square to facilitate their normal forward "shoveling" prehension motion for food collection.<sup>97</sup> Anseriformes should always have access to fresh, uncontaminated water. The daily water requirement of ducks (by weight) is approximately four to five times the weight of the daily feed intake. Water and food containers should be positioned near each other. Poultry water units and nipple drinkers can be used for waterfowl (Figure 46.8).



**FIG 46.7** The bill of a duck is designed to gather food from flooded and muddy areas and has highly developed cutaneous mechanoreceptors. **a**) The nares (n) are located in the mid-portion of the upper beak. **b**) The epidermis is thickened at the tip of the upper beak (ducks, geese and swans) and lower beak (ducks) to form a "nail" (arrows). These nails are designed to grasp small slippery objects and have well-developed nerve endings (Herbst's corpuscles). The lamellae (l) vary in form among species and serve either to cut or to filter food (modified from Lucas and Stettenheim, 1972).

### Energy Requirements

Metabolizable energy levels commonly used for poultry are similar to those required by ducks. The Pekin Duck has been shown to thrive with pelleted diets varying from 2200-3300 kcal ME/kg of diet, provided the proper ratio of energy to protein and necessary nutrients is maintained.<sup>97</sup>



**FIG 46.8** Waterfowl should always have access to clean, fresh water of sufficient depth. The food should be kept in a flat, large container to facilitate the scooping motion of the head and neck (1994 Busch Gardens, Tampa. All rights reserved.).

### Protein Requirements

Varying reports on the protein requirement of ducks may be a result of these animals' exceptional capacity for compensatory growth. Diets formulated using milo, corn, barley, wheat or other cereal grains mixed with fish meal, soybean meal, bone meal and meat have been shown to contain adequate amounts of essential amino acids except for methionine, and possibly cystine and lysine.<sup>97</sup>

### Nutrient Requirements of Laying Ducks

Theoretical ME requirements of laying Pekin Ducks: The energy requirement for maintenance of a moderately active Pekin Duck at an environmental temperature of 21°C is about 472 kcal/day.<sup>98</sup> A duck egg contains 185 kcal energy/100 g egg.<sup>109</sup> A large Pekin Duck has an egg that weighs about 90 grams. The energy put into the egg is  $0.9 \times 185 = 167$  kcal. The efficiency of converting feed energy into duck egg energy is about 73.6%.<sup>24</sup> To produce a 90 g duck egg, the feed energy needed is approximately 167 divided by 0.736 = 227 kcal. For 100% egg production, the total ME requirement of the Pekin Duck is approximately  $472 + 227 = 699$  kcal/day. A Pekin Duck would need to consume 252 g (0.55 lb) of a diet containing 2,772 kcal/kg to obtain this amount of ME.<sup>97</sup>

Theoretical protein requirements of laying Pekin Ducks: A duck egg contains 12.81% protein.<sup>109</sup> A 90 g egg contains  $0.1281 \times 90$  or approximately 11.5 g of protein. The protein maintenance requirement of the Pekin Duck has been calculated to be approximately 10 g/day.<sup>98</sup> To produce an egg, assuming the duck is

55% efficient in conversion of feed protein to egg and tissue proteins, a duck must eat  $11.5/0.55 = 20.9$  g of feed protein. When this is added to the 10 g of feed protein required for body maintenance, the total feed protein needed per day is 30.9 g. When a duck consumes the 252 g of feed needed to provide its energy requirements, the feed should have 12.5% protein, balanced in all amino acids needed for maintenance and egg production. Protein requirements for feather replacement is not included in this calculation. A diet for breeding ducks with 16% protein provides a reasonable quantity of the essential amino acids.<sup>97</sup>

### Vitamins

Recommended vitamin levels for practical commercial duck rations are in Table 46.5.<sup>97</sup>

- **Vitamin A:** Vitamin A is important in maximizing the efficiency of feed utilization. It has also been shown that young ducklings do not utilize the provitamin A found in alfalfa meal as well as they utilize preformed vitamin A.<sup>97</sup> This is caused by a reduced digestion of plant matter in the undeveloped cecum. The vitamin A content of the livers of ducklings remains high up to 14 days of age as a result of the vitamin A fed to the hen. After 14 days of age, the ducklings acquire vitamin A from their food.

Hypovitaminosis A is associated with poor growth, muscular weakness, retardation of endochondral bone growth and ataxia, paralysis and death. Chronic hypovitaminosis A in ducks has not been verified but has been suggested as a precipitating factor in the high incidence of bumblefoot described in Anseriformes (see Color 8).<sup>97</sup>

- **Vitamin D<sub>3</sub>:** Deficiencies of calcium or phosphorus result in rickets. Vitamin D<sub>3</sub> deficiency may occur in birds on proper diets if an animal lacks the enzymes needed to convert dietary vitamin to the metabolically active metabolite, 1,25-dihydroxycholecalciferol.<sup>97</sup>
- **Vitamin E:** Hypovitaminosis E has not been associated with encephalomalacia in ducks. The muscular dystrophy caused by hypovitaminosis E in ducklings is not prevented by dietary cystine as it is in gallinaceous chicks.<sup>97</sup> Prevention of vitamin E-related muscular dystrophy in ducks is mostly associated with



their requirement for dietary selenium. With low-selenium diets, 27 mg vitamin E/kg is needed to prevent myopathies. Vitamin E-deficient diets may cause neurocalcinosis in the heart, ventriculus and intestinal muscles, while skeletal muscles may have typical hyaline degeneration. Ducklings on deficient diets often will die by three weeks of age. Muscular dystrophy is prevented with diets containing 1.2 mg vitamin E/kg of food when selenium is added at a level of 0.1 ppm.<sup>46,47</sup>

- **Thiamine (Vitamin B<sub>1</sub>):** Ducklings begin to lose weight four days after being placed on thiamine-deficient diets. “Star-gazing” is a characteristic clinical sign. If deficiencies occur, thiamine should be added to the drinking water at 100 µg/l.<sup>97</sup>
- **Riboflavin (Vitamin B<sub>2</sub>):** Riboflavin deficiencies in ducklings cause poor growth and high mortality. The “curled toe” syndrome common in riboflavin-deficient chicks has not been reported in ducklings (see Color 48). Deficiencies in breeding ducks cause late embryonic mortality.<sup>97</sup>
- **Niacin (Nicotinic Acid):** Ducklings have a relatively high requirement for niacin, which is required for growth and prevents severe leg weaknesses. Ducks have high levels of picolinic acid carboxylase, an enzyme that converts tryptophan to carbon dioxide and water instead of allowing it to be converted to niacin. Ducklings receiving a diet deficient in niacin showed a 100% incidence of bowed legs. Severity of the leg deformities increased, and growth was depressed when 2% cod liver oil was added to the diet. The growth rate was returned to normal when 5% brewer’s yeast was added to the diet. Bowed legs were completely prevented when 7.5% brewer’s yeast was added. Niacin has been shown to be poorly available from natural feedstuffs, and supplementation with pure niacin may be necessary.<sup>97</sup>
- **Biotin:** The dermatitis associated with biotin deficiency in chickens has not been described in ducks. A poor growth rate appears to be the only sign of deficiency.
- **Folic Acid:** Deficiencies result in severe anemia as well as reduced growth and poor feathering.
- **Choline:** Unlike young mammals, ducklings, chicks and poults are unable to synthesize choline until later in life. Choline deficiency in Pekin ducklings causes perosis and fatty liver degeneration. Ducklings on choline-deficient diets grow poorly, have weak legs, develop perosis and may die. Most diets for ducklings

**TABLE 46.5 Vitamin Requirements for Pekin Ducks**

Vitamin	A	B	C
Vitamin A, IU	8000	5000	10,000
Vitamin D <sub>3</sub> , IU	1000	500	1000
Vitamin E, IU	25	20	40
Vitamin K, IU	2	1	2
Thiamine, mg	2.0	2.0	2.0
Riboflavin, mg	4.5	4.5	4.5
Niacin, mg	70.0	70.0	50.0
Pantothenic acid, mg	12.0	11.0	15.0
Pyridoxine, mg	3.0	3.0	3.0
Folacin, mg	0.5	0.25	0.5
Biotin, mg	0.15	0.1	0.15
Vitamin B <sub>12</sub> , mg	0.01	0.005	0.01
Choline, mg	1300.0	1000.0**	1000.0**

\* Must be increased to 8 mg/kg if sulfaquinoxaline or other vitamin K antagonist is present in the diet.

\*\* growing ducks may be able to synthesize choline  
Adapted from Scott.<sup>97</sup>

**A** = Recommended vitamin allowances for **starting** ducks

**B** = Recommended vitamin allowances for **growing-finishing** ducks

**C** = Recommended vitamin allowances for **breeding** ducks

contain adequate levels of choline. After eight weeks of age, it is recommended that choline supplementation be added to diets so that maximum choline biosynthesis will occur before the onset of egg production.<sup>97</sup>

- **Vitamin B<sub>12</sub>:** Ducks appear to have minimal requirements for dietary B<sub>12</sub> and newly hatched ducklings have sufficient levels of this vitamin derived from the hen.<sup>97</sup>
- **Ascorbic Acid (Vitamin C):** Ducks readily synthesize vitamin C; however, birds receiving supplemental vitamin C have superior erythrocyte and hemoglobin values as well as greater bacteriocidal and lysozyme activity than unsupplemented ducks.

### Mineral Requirements

Only eight of the thirteen minerals required by animals have been studied in ducks. Of the other five, all (potassium, iron, copper, molybdenum) except iodine are found in adequate amounts in most commercial feedstuffs.<sup>97</sup> Recommended allowances for minerals in starting ducks, growing Pekin Ducks and breeding Pekin Ducks are found in Table 46.6.

- **Calcium:** Calcium levels for ducklings are recommended at 0.6 to 0.8%. Levels up to 1 or 1.5% may cause progressive-to-severe decreases in weight gain. Ducklings receiving a diet with 0.17% will develop

rickets. For laying Tsaiya Ducks, the calcium allowance is 3%. For Pekin Ducks, it is 2.75% and for Khaki Campbell Ducks, 3.25%.<sup>97</sup>

- **Phosphorus:** Adequate levels for maximum growth and percentage of bone ash is 0.6% total phosphorus, of which 0.35% is available. When phosphorus was increased to 1%, there was neither a beneficial nor negative effect on weight gain or bone ash.<sup>97</sup>
- **Sodium:** Ducklings are considerably more susceptible to low sodium levels than gallinaceous chicks. All ducklings receiving a diet without sodium chloride or sodium bicarbonate died by the 19th day on this diet. In order to maximize weight gain, sodium chloride was supplemented to 0.3% (0.135% total sodium). Mortality was prevented, but inferior growth rates occurred when sodium bicarbonate was added to the diet. Chloride at a level of 0.072% provided by the basal diet was not adequate for normal growth. Supplementation with potassium chloride (KCl) to bring chloride level to 0.122% produced normal weight gains. There is a range from 0.4 to 0.8% total dietary salt (0.15 to 0.32% sodium) that is tolerated. When more than 1% salt is added, weight gain is significantly depressed. The sodium requirement of ducks is suggested to be 0.15% throughout all stages of life.<sup>97</sup>

## Reproduction

### Breeding Factors

Most ducks become sexually mature at about one year of age. A few exceptions, such as the Bufflehead and Scaup, require longer. Geese often take two years to mature, while swans may take five years to reach sexual maturity.<sup>44</sup> Waterfowl maintained in captivity are prone to hybridize, and related species should not be housed together.

A bird's behavior may change drastically during the breeding season, and aggressive species such as Cape Barren Geese, Sheldgeese, swans and Bronze-winged Ducks must be carefully monitored. Mixed aviaries must be large enough to allow birds involved in territorial aggression to escape.<sup>108</sup>

Male Anseriformes have an erectile phallus covered with keratinized papillae. This anatomic feature allows the gender of ducks or geese to be accurately

TABLE 46.6 Mineral Requirements for Pekin Ducks

Mineral	A	B	C
Calcium, %	0.7	0.6	2.75
Available phosphorus, %	0.5	0.4	0.4
Sodium, %	0.18	0.18	0.18
Chloride, %	0.18	0.14	0.14
Magnesium, ppm	500.0	500.0	500.0
Manganese, ppm	55.0	45.0	35.0
Zinc, ppm	60.0	60.0	60.0
Selenium, ppm	0.2	0.2	0.2

Adapted from Scott.<sup>97</sup>

**A** = Mineral allowance for **starting** Pekin Ducks

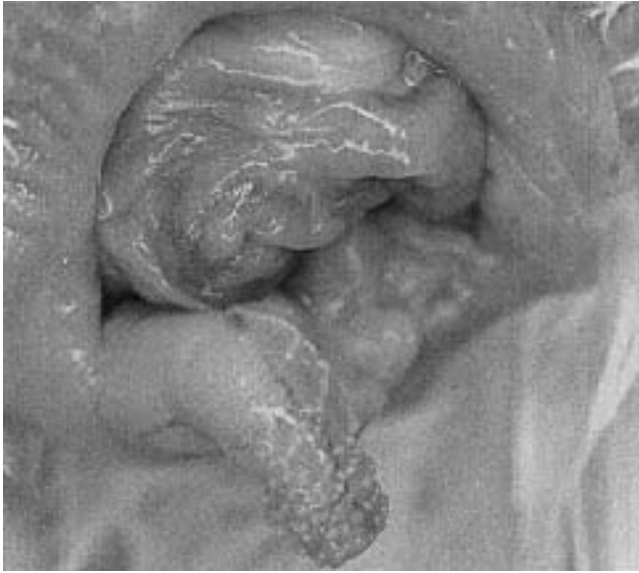
**B** = Mineral allowance for **growing** Pekin Ducks

**C** = Mineral allowance for **breeding** Pekin Ducks

determined at a very early age (Figure 46.9). Exposure and identification of structures is easier in mature breeding birds. The cloaca is manually everted to visualize the phallus by holding the bird vertically with its head down and abdomen toward the examiner. Gentle, firm pressure with the thumbs on each side of the cloaca will tend to evert the phallus. It may take some time to overcome the resistance of the cloacal sphincter but continued downward and outward pressure of the thumbs will help achieve exposure. Two small labia-like structures are found in the female. The phallus can be palpated in its retractile state and needs to be everted only for confirmation; the female requires little effort as a palpable mass cannot be detected.<sup>44</sup>

Male ducks frequently leave after the eggs are laid and the pair may or may not re-mate the following season. Swans and geese form a lasting pair bond that is broken only by the death of one of the birds. The surviving bird may have difficulty forming another pair bond, or may not breed again.<sup>44</sup>

Waterfowl nest in a variety of ways. Some prefer cavities, some thick vegetation and others, open areas. Waterfowl generally lay their eggs in the early morning. Smaller species usually lay one egg a day, while larger species lay an egg every other day. Information on average number of eggs per clutch, incubation time and incubation responsibility can be found in Table 46.1. Once incubation begins, the hen is reluctant to leave the nest, except for brief periods in the early morning or late afternoon to feed, drink and bathe.<sup>108</sup> During incubation, it is not uncommon for some free-ranging migratory waterfowl to lose up to 40% of their peak weight.



**FIG 46.9** The phallus of a male Anseriformes can be visualized or palpated in the ventral wall of the cloaca and is covered with keratinized papillae.

Because incubation of the clutch usually begins at the same time, most eggs in a clutch will hatch within a day or two of each other.<sup>108</sup> Once an egg pips, there is usually an interval of 16 to 24 hours before hatching is complete.

In some species, both parents protect the young (swans and geese), while in other species only the hen cares for the brood. There are also parasitic species (such as the Redhead) in which no parental care occurs, and the hen lays her eggs in the host nest.<sup>44</sup>

Anseriformes have nidifugous young that are covered in down and can eat, swim and dive almost from hatching. The young begin to forage within a day or so of hatching. Normal chicks have sufficient fat and yolk stores to survive for several days without eating. Some of the smaller species will fledge and can fly at about 40 days of age. Larger birds may take two to three months to fledge. An exception is the Ross's Goose chick that may fledge by four weeks of age.<sup>108</sup>

Preservation of semen and artificial insemination have been successful in free-ranging as well as captive waterfowl. Successful cryogenic preservation of semen has been reported for the Aleutian Canada Goose. Semen was diluted with Beltsville poultry semen extender, adjusted to  $270 \pm 30$  mOs and  $7.5 \pm 0.4$  pH. DMSO was added to seven percent concentration. With frozen-thawed semen, 19 of 31 eggs were fertile. About half of the live spermatozoa from the fresh semen (87.3 to 92.9% live sperm) survived the

freeze-thaw process.<sup>33</sup> Information on naturally occurring and artificial breeding programs for various waterfowl can be found in a variety of sources.<sup>37,39,51,108</sup>

## **Embryo and Neonatal Management and Pathology**

### **Incubation**

Artificial incubation and brooding of waterfowl is a common practice. A pair of birds may be stimulated to produce another clutch of eggs by removing the first clutch. In some aviaries, eggs and babies are susceptible to predators or environmental injury, and artificial incubation is necessary to ensure survival. Small enclosures may alter normal behavior so that a pair will not properly incubate or brood.

Typically, an incubator temperature of 99.3°F and 85% humidity is appropriate for most waterfowl. Improper egg storage, egg contamination, low humidity, air flow problems and inadequate turning of the eggs can all cause reduced hatchability (see Chapter 29).

Nutrition, infectious diseases and genetics can also reduce hatchability and survivability. Genetic factors have not been adequately explored as a cause of poor hatchability in birds. Inbreeding in domestic birds correlates with a significant increase in infant mortality, which may reach 100% after three to four generations of breeding.<sup>25</sup>

In a study at the New York Zoological Park, attempts to determine the cause of early embryonic death in birds were inconclusive due to rapid degeneration of the embryo at high incubation temperatures.<sup>20</sup> A study at the Regent's Park Zoo from 1973 to 1975 on 442 birds was unable to document bacterial infections as a cause of poor hatchability.<sup>96</sup>

### **Brooder Room Management**

The requirements of Anseriforme chicks are the same whether they are reared by their parents, a surrogate hen or artificially. Ducklings seem to thrive best if they are provided a thermal gradient and allowed to choose their own temperature. The temperature on the heated side of the enclosure should be about 95 to 99°F initially and then gradually decreased to about 70°F over a three-week period. It is important that chicks never become chilled. Although they may appear to recover when warmed, many affected chicks develop gastrointestinal problems or liver or kidney failure and die several days later. The chicks are the best guide to determine if a proper temperature is available. If chicks are huddled under the heat, they are too cold; if they are panting, appear stressed and


are staying away from the heat, then they are too hot (Figure 46.10).<sup>81</sup>

Housing enclosures for ducklings should be easy to clean and sanitize. With any brooding method, it is important to maintain a clean, dry, warm enclosure with an easily available supply of clean food and water. Drafts should be avoided. Many chicks seem suicidal, and pebbles or marbles must be added to the water container to prevent drowning. Chicks have been known to get stuck between the food container and a wall, and they may also jump out of the brooder and become chilled.<sup>81</sup>

An effective brooder room has a sloping concrete floor with a drain in one corner. The room has a control system that allows heating, cooling and adequate ventilation. A metal rack is attached to the wall to suspend individual containers off the floor for easy cleaning. Individual brooder boxes can be removed for intensive cleaning and disinfecting. Each box is 19 inches wide by 36 inches long. The back is 16 inches deep and the front is 10 inches deep. The bottom is made of one-fourth inch by one-half inch vinylized wire<sup>c</sup> and the removable top is made of one-fourth inch by one-fourth inch hardware cloth in a wood frame that is hinged in the middle for access to both the front and back of the brooder. Enclosures for older birds have higher walls and lack a sloping top. A small stainless steel pool is inserted into the front bottom of the enclosure (Figure 46.11). This pool has a sloping bottom so the birds can get in and out easily, and a maximum depth of three to four inches. Shallow pools, three-fourths inch deep, are used initially to acclimate young ducklings to the water.<sup>81</sup>

A 150-watt infrared heat lamp is placed over each box on an extendable cord so that the heat can vary from directly over the enclosure to 32 inches above the enclosure (Figure 46.12). Room temperature is maintained at 76 to 82°F while the box temperatures are increased by the lights. A poultry water bottle is used in each box with pebbles in the troughs so that young birds do not drown. The water bottle and food pan are positioned away from the wall at the opposite end of the heat source.

For younger birds, it is advisable to use a vinyl turf-type mat<sup>b</sup> or towel under the heat source to make the flooring more comfortable as well as to retain heat. Hay, straw, shavings, newspaper or other absorbent materials used for bedding may be consumed by some ducklings and cause impactions. The room should have a treatment area with a counter, scale



**FIG 46.10** Behavior of a neonate is the best indication of a proper temperature gradient. These chicks are standing together for security but are not huddled, which would indicate chilling. Note that the back half of the brood box is heated (Figure 46.12) and the front half is unheated, creating a natural thermogradient (1994 Busch Gardens Tampa. All rights reserved.).

and record keeping materials. Daily records are maintained on each group of birds. A double sink is effective for cleaning pans and a hose is used for cleaning the wall-mounted brooder boxes. Various disinfectants can be used. Water bottles may be changed several times a day as needed, and enclosures are cleaned once a day.<sup>81</sup> Further information on brooder room set-ups may be found in Brown<sup>3</sup> and Hyde.<sup>45</sup>

The ducklings are ready for outside pens at two to four weeks of age. It is preferable to use an intermediate facility to acclimate the ducklings to the difference between the very controlled environment of the brooder room and the limited control of outside pens. Providing birds free choice to indoor or outdoor environment is optimal. Outside enclosures approximately eight feet square with concrete floors and a gently sloping pool covering about half of the floor space are ideal. The slope of the pools should be



**FIG 46.11** As waterfowl mature, they should be provided a shallow pool with gently sloping edges. Neonates are best raised in groups of similarly sized individuals. This lone neonate was provided a stuffed toy for company (1994 Busch Gardens Tampa. All rights reserved.).

gradual, and vinyl mats should be placed on the edge of the pool and on some of the dry areas to prevent leg and foot problems. A heat lamp should be available for each pen. All pools should have overflows and good drainage for easy cleaning. Once acclimatized to the outdoors, the birds can be moved to larger growing pens. They can then be moved to other areas such as breeding pens or large mixed species aviaries.

#### Neonatal Problems

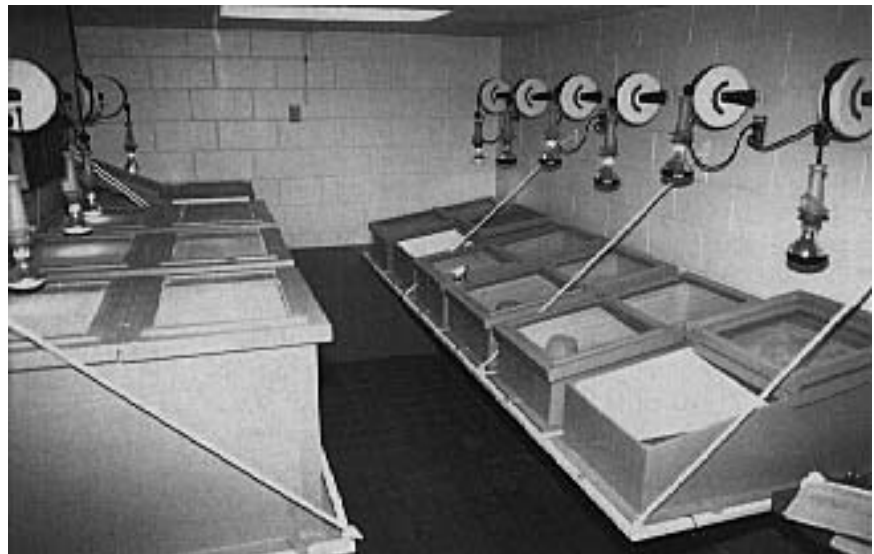The majority of losses during the first two weeks of life are associated with the poorly understood diagnosis of starveout. Starveout is a term coined by poultry pathologists to describe a condition of turkey poults wherein birds never start to eat; they starve after their yolk stores are depleted. Characteristically, deaths occur in waterfowl at 7 to 14 days of age; the birds have an empty, contracted gastrointestinal tract, a small yellow liver, a distended gall bladder and no fat stores. It has been shown that many species, especially in captive situations, require specific stimuli and encouragement to begin self-feeding,<sup>64</sup> and a lack of these stimuli may contribute to the problem.

Young waterfowl generally do not require food for the first 24 to 48 hours while the yolk sac is being absorbed. Scoters, Harlequins, Oldsquaw duck-

lings and other specialized species may be particularly difficult to get started eating and must be fed by hand and pampered for considerable lengths of time. Mallard ducklings may be used to stimulate feeding in reluctant eaters. It is easier to raise a brood of young rather than a single bird.

Simulating the natural conditions that a free-ranging hatchling would encounter may stimulate feeding behavior. Newly hatched Mandarin Ducks and Wood Ducks tend to calm down in the brooder and begin to eat after they have been tossed in the air and allowed to drop to the ground. As strange as this may seem, it works because these species are cavity nesters and young often fall 60 feet or more to the ground when they leave the nest.<sup>108</sup> Wood Duck chicks feed best if a cotton floor mop is hung in the brooder.

Ducklings may become wet and chilled in a brooder or when moved to an outdoor area and exposed to heavy rains. Their undeveloped feathers lack the natural oils and proper structure to repel water. Weaker ducklings that are not competing effectively with other chicks for food may become hypoglycemic, weak and chilled. A hair dryer can be used to dry the feathers and warm the body. Once the birds are dry, tube feeding with 0.25 to 3 cc of a prepared formula<sup>d</sup> provides a quick energy source. Steroids, subcutaneous fluids and antibiotics may prevent secondary problems. Large doses of rapidly metabolized ster-



**FIG 46.12** An ideal brooder room designed for Anseriformes and Galliformes. Tile floors and walls are easy to clean, and the brooder boxes can be removed for cleaning and disinfecting. Heat lamps are placed on retractable extension cords to allow changes in the amount of heat provided to an individual brood box. (1994 Busch Gardens Tampa. All rights reserved.).

oids (prednisolone sodium succinate 2 mg/60 g chick) should be repeated every 15 minutes (some chicks may require four or five doses) until the chick is warm and stabilized (Harrison G, unpublished).

Gastrointestinal disorders seem to be particularly common in neonatal birds. A high energy requirement and the need to establish a resident flora in what is a sterile environment at hatching probably account for many of these problems. Impaction of the crop and ventriculus, and less commonly the colon, may be the only lesions seen at necropsy. A precise etiology is rarely identified although inappropriate or excessive food intake is often implicated. Impactions lead to putrefaction of the gastrointestinal contents causing inflammation of the gastrointestinal mucosa and frequently systemic intoxication.<sup>64</sup>

- **Yolk Sac Disorders** can be divided into three overlapping syndromes. The first is retention of the yolk sac. At necropsy, affected birds have a moderate-to-large unabsorbed yolk sac in the abdominal cavity that is recognized clinically as a distended abdomen. No other abnormalities are noted. In domestic fowl, the yolk sac is completely absorbed by ten days of age. Similar data are not available for most aviary species, but, in general, persistence of the yolk past two weeks of age is abnormal and detrimental. Causes for non-absorption are unknown, as are the events that lead from retention to death of the bird. Neonates depend on the yolk sac for the first two to three days of life and if the yolk is not absorbed, the birds will be malnourished. Maternal immunoglobulins, specifically IgG, are absorbed with the yolk. Improper absorption of the yolk could result in the same immunosuppression seen in mammals that do not ingest colostrum.<sup>64</sup>

Temperature and humidity during incubation affect yolk sac development. High humidity or low temperature may cause a failure to retract the yolk sac into the abdomen prior to hatching. Low humidity during incubation has been associated with infection of the yolk sac. Infected yolk appears as a thick brownish or yellow coagulated mass compared to normal yolk, which is a greenish-yellow liquid (see Color 48). Compared to other birds, precocial birds such as waterfowl have a large yolk sac. One study showed that yolk sacs in precocial species ranged from 12 to 25% of the body weight. The majority of the yolk sac should be absorbed within a week.

The yolk sac should be surgically removed if clinical signs, palpation and radiography indicate nonabsorption. Surgery usually is successful if performed

before a bird becomes dyspneic. Clinical signs suggesting that surgery is necessary include swollen abdomen, dyspnea, exercise intolerance, inability to stand or walk, inappetence, weight loss or failure to grow. For surgery, birds are anesthetized with isoflurane and placed in dorsal recumbency with the legs pulled caudally. Feathers on the abdomen are plucked from flank to flank and from the keel to the cloaca, and the skin is surgically prepped (see Figure 48.13). Birds should be given 0.016 ml/g body weight of a 50:50 mixture of 5% dextrose in lactated Ringer's solution and 0.9% sodium chloride to compensate for any blood loss during surgery. Birds should be given broad-spectrum antibiotics postoperatively pending results of a yolk sac culture. Some chicks will require tube-feeding for several days before they will resume feeding, whereas others will begin to eat and gain weight one to two days postoperatively.<sup>58</sup>

A second syndrome, rupture of the yolk sac, can occur as a sequela to yolk sac retention or yolk sacculitis (the third yolk sac-related syndrome). Rupture can also occur following traumatic events in two- to three-day-old birds with normal yolk sacs. Death results from yolk-related peritonitis and shock. Yolk sacculitis and omphalitis can occur separately or concurrently in a bird and are most frequently associated with gram-negative organisms, especially *Salmonella* sp. and *E. coli* (see Color 48). Omphalitis is characterized by edema and inflammation of the abdominal wall surrounding the umbilicus. Yolk sacculitis is characterized by enlargement, hyperemia and petechiation of the wall and greenish discoloration and coagulation of the yolk sac. In most cases, omphalitis and yolk sacculitis arise from contamination of the umbilicus. Incubator and brooder sanitation are crucial for prevention of yolk sacculitis.<sup>64</sup>

- **Miscellaneous Microbial Infections:** Bacterial infections in neonates usually cause a multisystemic, fatal septicemia. Bacteriemia occurs so quickly that the entry point for the bacteria cannot be determined. The gross and microscopic lesions of septicemia are often subtle: splenomegaly, hyperemia and petechiation of the lung and gastrointestinal serosa, and congestion or focal necrosis of the liver. *Salmonella*, *E. coli*, *Pseudomonas*, *Streptococcus* and *Erysipelas* spp. are usually implicated. The incidence of bacterial septicemia can be reduced through sound brooder hygiene and by identifying and controlling infections in subclinical parents. *Salmonella* sp. have been implicated in necrotizing colitis in Anseriforme neonates. Infections may be localized or occur as part of a systemic infection including yolk sacculitis and air



sacculitis.<sup>64</sup> Aspergillosis is uncommon in healthy birds; however, neonates with immature defense mechanisms that are compromised by malnutrition or environmental stress are more susceptible to inhaled spores (see Color 23).

### Nutritional Diseases

- **Angel Wing:** This condition is also referred to as healed-over, slipped, crooked, rotating, tilt, sword, spear, reversed, airplane and dropped wing. Angel wing is apparently caused by the weight of the growing flight feathers placing excess stress on the weak muscles of the carpal joint. Gravity encourages the developing wing to hang and finally to twist outward. If untreated, the wing may remain in that position and the ligaments and bones will be permanently deformed (Figure 46.13). Simply taping the wing on itself (not to the body) in a normal position for three to five days is usually sufficient to correct the problem. Manganese deficiency and hypovitaminosis D<sub>3</sub> have been suggested as etiologies. Genetic factors, environmental influences or management practices have also been implicated.<sup>56,111</sup>

Angel wing has been suggested to be a problem associated with captivity; however, it has been described also in free-flying populations of *Cereopsis* in South Australia, Canada Geese in Sweden, Mute Swans in Switzerland and semi-wild Mallard Ducks in England. Most affected birds have slow natural growth rates and are from temperate or tropical areas.<sup>57</sup> Interesting differences in the susceptibility of different waterfowl species to angel wing are being recognized.

Several fast-growing species originating from the Arctic have not yet shown slipped wing. These include the Greater Snow Goose, which can grow to nearly 14 times its hatching weight by three weeks of age, and the Barnacle Goose that can grow to thirteen times. The Swan Goose and Hawaiian Goose, in similar conditions of light, heat, food and water, increase their weight by only a factor of eight. Similar slow growth rates occur for most low-latitude ducks, geese and swans.

Differences in food intake are also apparent among Anseriformes from different geographic regions. For instance, *Cereopsis* goslings spend a large part of each 24 hours sitting or sleeping. Snow Geese, on the other hand, are restless even in the dark and will feed steadily if given the chance, with frequent pauses for brief periods of sleep. The result of these differences is that the Arctic species fledge much faster than temperate or tropical species. In nature, this quick



**FIG 46.13** Angel wing is characterized by droop and outward twist of the wing. In this Black Swan cygnet, the carpus is ventrally displaced (arrows) (1994 Busch Gardens Tampa. All rights reserved.).

maturation is vital so that the birds are ready for migration before winter storms occur.<sup>57</sup>

These findings would suggest that angel wing is associated with overfeeding tropical and temperate species, causing an excessively rapid growth. Deformities are more common in the heavier members of a brood and are more frequent in males, which grow more rapidly. Angel wing is also more common during warmer weather when young birds are able to use more dietary energy for growth and less to maintain body temperatures. Angel wing seems to occur more commonly in birds fed ad libitum and provided inadequate areas for exercise. In one flock, four out of six New Zealand Gray ducklings developed angel wing, apparently after the accidental feeding of turkey starter diet (28% protein) instead of chick diet (18.5% protein).<sup>57</sup>

Excessive energy, excessive protein or a deficiency of vitamin E have all been suggested as dietary factors in the occurrence of angel wing. Clearly, a balanced diet formulated for tropical and temperate waterfowl species is required. A study with Mallard, Pintail and Redhead ducklings (slow growth-rate species) indicated that the protein requirement during the first three weeks of life is below 19%. Optimum growth curves occurred when the animal protein content of the diet was 8%.

Factors that may reduce the incidence of angel wing include exercise (swimming, diving) and plenty of grass and other green foods. Birds originating from low latitudes should not be fed high-energy, high-protein foods. It is clear that waterfowl chicks from different species must be treated differently. Birds originating north of the Arctic Circle should be provided constant light, plenty of water and a constant supply of food that is relatively high in protein. Those originating from equatorial regions should be provided 11 hours of darkness per 24 hours; these birds can consume comparatively less food of a lower quality.<sup>57</sup>

- **Perosis:** Also known as slipped tendon, perosis is characterized by enlargement of the hock, bending deformities of the mediotarsal and tarsal metatarsal bones and medial luxation of the Achilles tendon, which prevents the bird from bearing weight on the affected limb (Figure 46.14). One suggested etiology is a manganese deficiency caused by excessive calcium supplementation (calcium binds manganese). If the problem occurs before two weeks of age, it is likely that the hen's diet is deficient in manganese. Ducklings and goslings fed a manganese-deficient diet will develop perosis in two to ten weeks.<sup>111</sup> Angel wing and perosis may have a similar etiology.

A leg undergoes rapid pathologic changes once it begins to deviate (see Color 8). Bandaging or splinting the leg is usually unsuccessful. Trochlear grooving or transplantation of the insertion of the Achilles tendon laterally have been attempted. Open reduction and stabilization of the luxated tendon are successful in some cases. An incision is made through the skin and over the posterolateral aspect of the joint midway between the displaced tendon and lateral condyle of the tibiotarsal bone (Figure 46.15). The tendon is dissected free of its trochlear and medial adhesions and reduced to its normal position in the trochlear groove. The tendon sheath is sutured to the lateral periosteum and retinaculum with simple interrupted 3-0 absorbable suture. The skin incision is closed with simple interrupted 4-0 nonabsorbable suture. A tongue depressor can be used as a splint for a week. The patient should be using its leg normally by the second postoperative week.<sup>118</sup>

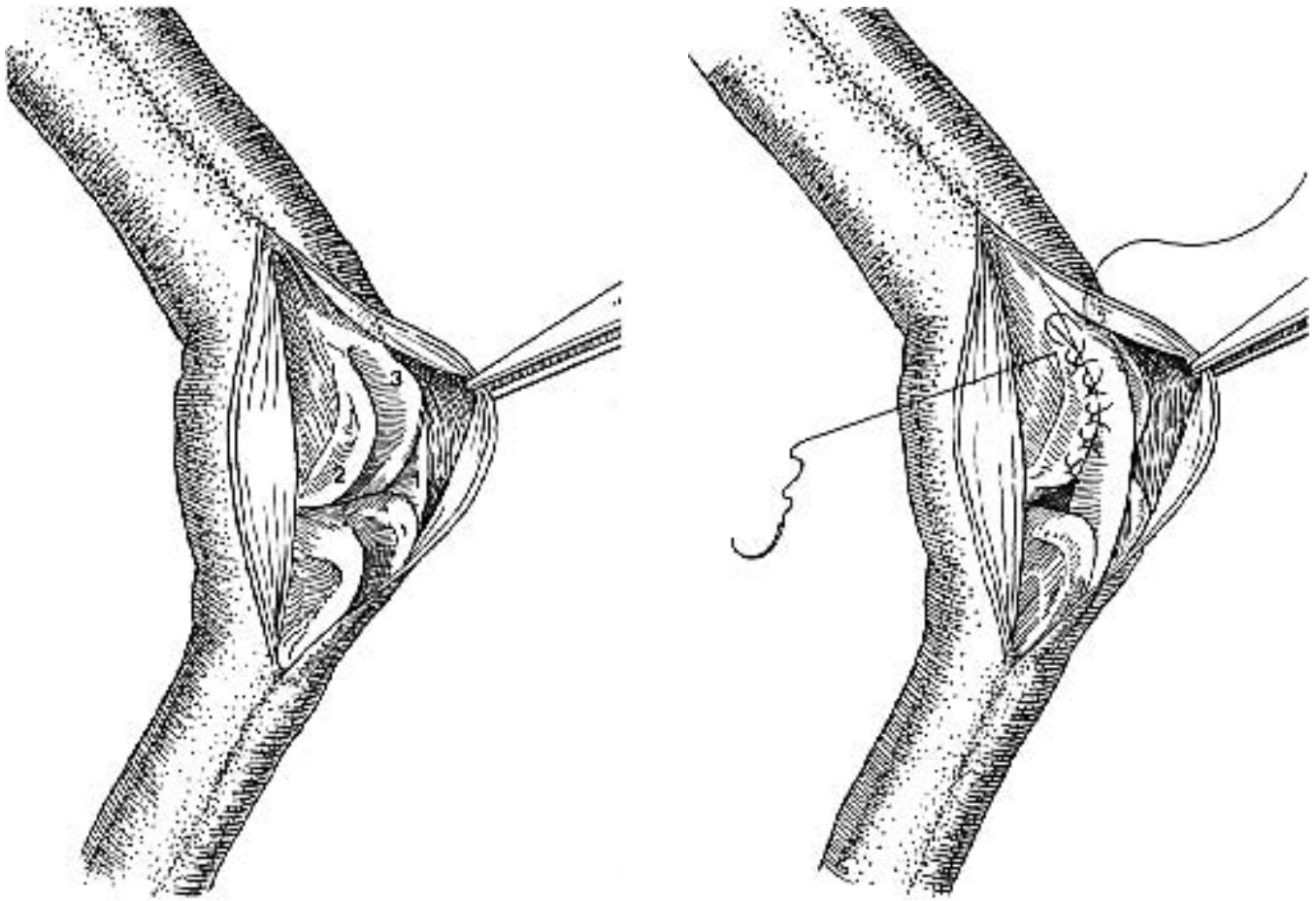
- **Nutritional Secondary Hyperparathyroidism:** Ducklings whose diets are poor in calcium or contain excessive phosphorus may develop fibrous osteodystrophy or osteomalacia. The birds may appear reluctant to move. Abscesses or blisters of the keel often develop in birds that are non-ambulatory. Soft bones

and enlarged parathyroids are common postmortem findings (see Color 14).<sup>45</sup>

- **Rickets:** Rickets results from a lack of vitamin D. The first clinical signs are lameness, retarded growth and bent or twisted breast bones. Providing a proper diet will reverse the symptoms in two to four weeks unless advanced changes have occurred.<sup>45</sup>



**FIG 46.14** Cranial and caudal view of a duckling showing the clinical appearance of a medially luxated Achilles tendon of the right hock joint. Manganese deficiencies (possibly exacerbated by over-supplementation of calcium) have been suggested as a cause (courtesy of John Olsen).



**FIG 46.15** An incision is made through the skin and over the caudolateral aspect of the joint midway between the 1) displaced tendon and 2) lateral condyle of the tibiotarsal bone. The tendon is dissected free of its trochlear and medial adhesions and reduced to its normal position in the 3) trochlear groove. The tendon sheath (right) is sutured to the lateral periosteum and retinaculum with simple interrupted 3-0 absorbable suture. The skin incision is closed with simple interrupted 4-0 nonabsorbable suture. A tongue depressor can be used as a splint for a week. The patient should be using its leg normally by the second post operative week (modified from Wolfe<sup>118</sup>).

## Restraint, Handling and Anesthesia

### Capture and Handling

Various nets can be used to catch waterfowl in the confines of an aviary. In some cases, a group of birds can be herded to a corner of the enclosure and captured together or individually. On large ponds, a boat or several people wading in the water may be needed to capture waterfowl. A bright spotlight can be used at night to “freeze” a bird, allowing it to be quietly approached.

Heavy-bodied species should not be carried by using the wings or feet alone, although smaller species can be restrained by their wings. Smaller ducks can also be held by grasping the back and wings and using the thumb and fingers to restrain the feet (Figure 46.16). For larger birds, the base of both wings should be grasped with one hand while the other hand and arm supports the body. These birds should be carried under one arm, with their head facing to the back. The arm is wrapped around the wings and a hand is used to support the body and control the legs (Figure 46.17). A wrap using Velcro adhesive straps or a pillowcase-type bag with a hole in the end for the head and neck can be used for restraining waterfowl during certain examinations, blood collection and radiographic procedures.

### Field Immobilization and Capture

Occasionally, a practitioner may be asked to catch waterfowl from a pond. Attempts to capture these free-ranging birds can be frustrating. Capture nets, mist nets, spring-loaded nets, funnel nets and rocket or cannon nets are useful but are not typically available to private practitioners.<sup>c,e</sup>

Several agents have been used to immobilize free-ranging ducks or geese, with sodium amobarbital being the most frequently used. In test studies, an oral dose of 100 mg/kg was found to produce muscle incoordination approximately 20 minutes after ingestion. The test ducks never reached a plane of anesthesia but were immobilized sufficiently to allow easy capture. For field immobilization, one cup of hen scratch was mixed with 900 mg of dissolved amobarbital and allowed to dry in shallow pans (50 pounds of scratch will dry in about four hours with the aid of fans). Animals should not be approached for 60 minutes after feeding to ensure that they are adequately immobilized and will not fly to another location and die. Recovery may take up to eight hours.<sup>36</sup>

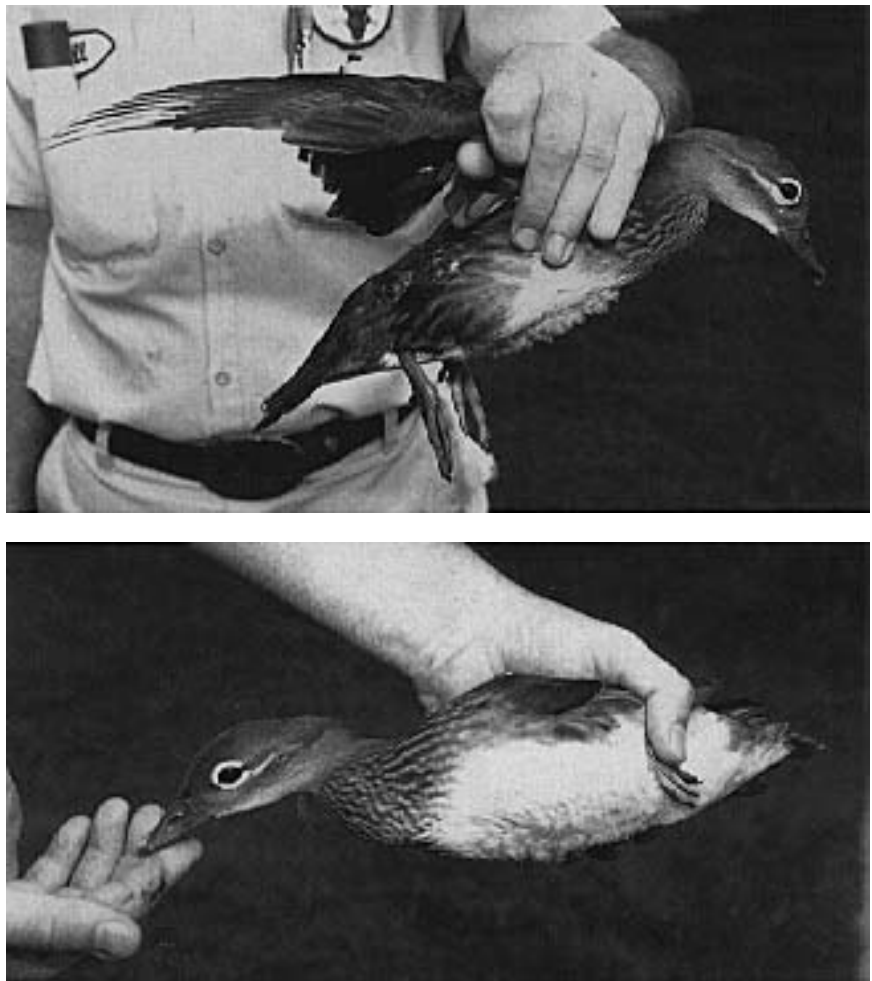
The drug has a low therapeutic index and should be used only in a field setting when restraint is critical and all other methods of capture have failed. There must be a fast method of retrieving birds from the water before they drown. Some birds may consume excessive concentrations of the drug and die. There was an eight percent mortality rate in one study of ducks. Half of these losses may have been prevented with post-capture gastrolavage or tubing with fresh water to dilute and accelerate passage of the drug.<sup>36</sup>

Another study evaluated seven agents as possible immobilizing drugs for field use on ducks. The only compound to satisfy the study criteria was tribromoethanol. Alpha-chloralose, methoxymol, metomidate, pentobarbital sodium, secobarbital sodium and thiopental sodium were all inferior to tribromoethanol. At the median effective dosage (ED<sub>50</sub>) for immobilization (100 mg/kg of body weight), the duration of induction

was 2.4 minutes, immobilization was 8.7 minutes, and recovery was 1.3 hours. The median lethal dosage (LD<sub>50</sub>) was 400 mg/kg of body weight. None of these drugs was given in feed in field situations.<sup>6</sup> The study refers to other work indicating that a drug-to-bait ratio of three grams tribromoethanol per cup of whole corn was effective.<sup>10</sup>

### Anesthesia

Waterfowl, like other birds, have a highly variable regional response to pain. The most sensitive areas are the beak, head, feet and feather follicles. Removing one or two feathers may elicit a more violent reaction than suturing a cutaneous wound or cutting skin. It is frequently possible to handle viscera without evoking any sign of pain from a conscious bird.



**FIG 46.16** Restraint technique used for small waterfowl. This technique should not be used for larger Anseriformes. Some small duck species can be restrained (bottom) by folding the legs caudally and holding the wings and legs in one hand (1994 Busch Gardens Tampa. All rights reserved.).



**FIG 46.17** Larger waterfowl should be restrained by holding the legs against the bird's body and tucking the bird, with head facing backward, under the arm of the handler (1994 Busch Gardens Tampa. All rights reserved.).

Local anesthesia is often sufficient for performing superficial procedures. Lidocaine hydrochloride (2%) is one of the safest local anesthetics for waterfowl; however, general depression can occur with high doses.<sup>4</sup> Reasonable amounts relative to weight are usually safe and effective. Using 1 ml of 2% procaine in ducks and 3 ml in swans was found to provide good local anesthesia with few problems.

Isoflurane anesthesia is convenient for performing minor procedures, positioning for radiographs or major surgery. Mask induction and maintenance for short procedures (< 15 minutes), or mask induction followed by intubation for longer procedures are common. The neck must be extended in intubated, long-necked birds to prevent the trachea from folding over

the end of the tube, causing partial or complete airway obstruction. Halothane and methoxyflurane have also been used in waterfowl but are inferior to isoflurane. Many waterfowl species have profuse salivary secretions under anesthesia and may benefit from the use of an antisialagogue such as glycopyrrolate.<sup>42</sup>

Induction times for gas anesthetics in waterfowl are frequently prolonged when compared to psittacines, probably due to the substantial subcutaneous fat deposits in the former. Recovery periods are also prolonged.<sup>54</sup> Breathing amplitude (an indicator of tidal volume) has been shown to decrease by 40 to 50% and the frequency of respiration increases 20 to 50% when birds are in dorsal recumbency. This causes a 10 to 60% decrease in minute ventilation, probably due to visceral compression of the air sacs.<sup>90</sup> Positive pressure ventilation can be used to decrease these effects. A peak positive pressure of 15 to 20 cm of water is adequate.<sup>54</sup>

With both isoflurane and halothane, waterfowl tend to change planes of anesthesia rapidly and unexpectedly. Cardiac monitoring of anesthetized waterfowl can be done with a doppler flow probe placed under the tongue, against the carotid artery or on the ventral surface of the elbow on the recurrent ulnar artery. An esophageal stethoscope or ECG can also be used. A rectal or esophageal thermometer is useful to monitor body temperature. Time of recovery from anesthesia is directly proportional to the amount of heat loss. The lower the body temperature, the longer the anesthetic recovery period.<sup>54</sup>

In one study evaluating isoflurane and halothane, 2.2 to 2.7 kg Pekin Ducks were masked with a concentration of 3.5% anesthetic gas with an oxygen flow of 3 l/min. They were intubated with 5 mm cuffed endotracheal tubes (uncuffed tubes are preferred in birds) and maintained with 2 to 3% isoflurane or 2 to 2.5% halothane. When anesthesia was discontinued, ducks received oxygen for two minutes prior to breathing room air. The ducks showed no distress from the mask or vapors.<sup>35</sup>

Palpable reflexes were lost during induction with both agents. Isoflurane induction was significantly shorter than halothane induction. Slow to absent pedal and wing reflex characterized a surgical plane of anesthesia. Both anesthetics had a smooth recovery pattern of similar length. Respiration was regular and deep with halothane and isoflurane. Both anesthetics significantly depressed respiratory rate,



**TABLE 46.7 Gas Anesthetic Parameters in Pekin Ducks**

	Induction Time	Respiratory Rate - (bpm)	Heart Rate - (bpm)	Blood Pressure - (mmHg)
Baseline	—	15 - 23	173 - 207	114 - 142
Halothane	5 - 9 minutes	4 - 6	230 - 388	96 - 128
Isoflurane	3 - 5 minutes	7 - 11	176 - 310	107 - 131

Values at 30 minutes post-induction  
Adapted from Goetz.<sup>35</sup>

increased heart rate (HR) and decreased blood pressure (Table 46.7).<sup>35</sup>

Cardiac rhythm was not affected by isoflurane. With halothane, four of eight ducks showed abnormal rhythms. Three ducks developed abnormal ECGs with ventricular bigeminy and multifocal ventricular rhythms (perhaps due to increased  $\text{paCO}_2$ ). One duck developed ventricular fibrillation and died. Mean arterial blood pressure decreased with both anesthetics.<sup>35</sup>

Isoflurane is superior to halothane because induction and recovery times are shorter, there is less preoperative stress and less postoperative hypoglycemia and hypothermia. Isoflurane also causes fewer cardiac arrhythmias and is less of a cardiopulmonary depressant. The editors believe that injectable anesthetics are a poor choice in Anseriformes and should be avoided (see Chapter 39).

## Diseases

The most prominent problems in a group of Anseriformes presented over a six-year period to the Canadian Disease Research Institute were improper management, nephritis and reproductive disorders.<sup>103</sup> At the National Zoological Park, 1,500 Anseriformes that died during a ten-year period were found to have many diseases similar to those described in free-ranging Anseriformes. Diseases identified included botulism, erysipelas, tuberculosis, pasteurellosis (avian cholera), salmonellosis, other bacterial septicemias, aspergillosis, candidiasis, amyloidosis, gout, hematozoan infections, schistosomiasis, echinuriasis and others (Table 46.8).<sup>73,74</sup> Several diagnostic facilities may be helpful in resolving problems associated with Anseriformes.

## Non-infectious Diseases

### Bumblefoot

Bumblefoot (pododermatitis) occurs frequently in captive waterfowl, especially swans. It is believed to be caused by rough, hard surfaces such as concrete pools or pens that cause trauma to the bottom of the birds' feet (see Chapter 16). Large, lumpy protuberances or eroded or scabbed lesions can develop (see Color 46). A bird may naturally recover from mild lesions if it is placed in a pen with adequate pool space and easy access in and out of the pool (Figure 46.18).

Treatment of bumblefoot is difficult and often unrewarding. If a bird is not lame, it may be best to forego treatment that frequently increases the severity of the problem. Suggested therapies that include surgical debulking of the lesion and medical management frequently fail. The bird must be maintained on soft footing during the recovery period.<sup>b</sup> One common treatment is a topically applied combination of dimethylsulfoxide (DMSO) (30 ml), dexamethasone (2 mg) and chloromycetin succinate (200 mg) (or other appropriate antibiotics based on sensitivity). This is applied to the lesion every eight hours. Recovery may take three to six weeks.<sup>104</sup> Another treatment includes daily cleaning of the lesion with iodine scrub followed by the application of camphor spirits (drying agent) and benzoin (toughens the tissues).<sup>91</sup> Supplemental vitamin A and an improved diet may also be helpful (see Chapter 16).

### U.S. Diagnostic Facilities for Resolving Problems in Anseriformes

The federal diagnostic facility is the U.S. Fish and Wildlife Service, National Wildlife Health Center, Madison, Wisconsin. Several states have active wildlife disease programs located at: Fairbanks, Alaska; Sacramento, California; Fort Collins, Colorado; Rose Lake, Michigan; Hampton, New Jersey; Delmar, New York; Fargo, North Dakota; Madison, Wisconsin; and Laramie, Wyoming.<sup>28</sup>

There are three regional wildlife disease programs affiliated with universities. These include the Southeastern Cooperative Wildlife Disease Study, University of Georgia, Athens; Northeastern Center for Wildlife Disease, University of Connecticut, Storrs; and Colorado Wild Animal Disease Center, Colorado State University, Fort Collins. The University of Florida-Gainesville and Virginia Polytechnic Institute and State University-Blacksburg also have active wildlife disease programs. Cornell University has the Duck Research Laboratory located at Box 217, Eastport, New York 11941, telephone (516) 325-0600. The primary focus of the Duck Research Laboratory is on production duck management, nutrition and disease, but it also has involvement with wild fowl. The staff has considerable expertise and diagnostic capability available. The U.S. Department of Agriculture, Veterinary Services Laboratory, Ames, Iowa can also accept diagnostic specimens that have been submitted through appropriate channels.



### Oil-contaminated Birds

Anseriformes are often affected by oil spills. The oil destroys the insulating and waterproofing properties of the plumage. Oil may also be associated with reproductive disorders; alteration of neural, endocrine and osmoregulatory functions; toxic changes in the gastrointestinal tract, pancreas and liver; aspiration pneumonia; renal damage; and Heinz-body anemia. Mortality of birds affected by oil spills often exceeds 80% but can be reduced to 15% with proper treatment (see Chapter 15).<sup>16,65</sup>

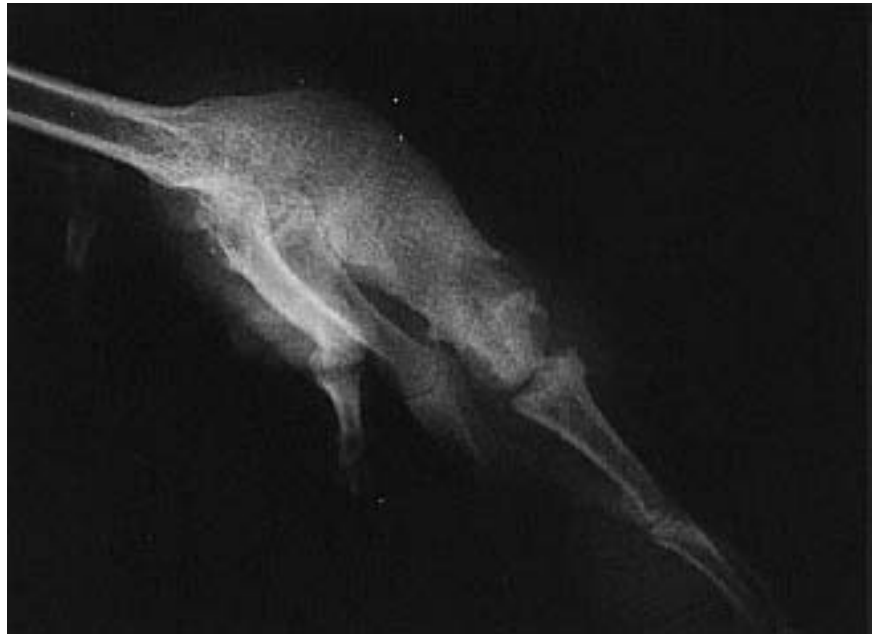### Amyloidosis

Amyloidosis is a common finding in captive and domestic waterfowl, but is rarely diagnosed in free-ranging birds. Gross lesions include pallor and enlargement of the liver, spleen or adrenal glands. Less commonly affected organs include the pancreas, kidney, intestine, lung and heart. Affected organs are firm and usually yellow-brown in color. Histologically (with hematoxylin-eosin stain), amyloid is amorphous, eosinophilic, acellular material that separates, compresses and displaces normal cells. With Congo red stain, amyloid is orange-red and slightly fibrillar, and under ultraviolet light it fluoresces when treated with thioflavine S or T.<sup>116</sup>

The pathogenesis of amyloidosis appears to be complex and is poorly understood.<sup>18</sup> Amyloidosis is found in association with a number of chronic primary diseases and can be induced by some types of immunization. Amyloidosis in domestic ducks has been associated with crowding and social stress.<sup>116</sup> Although there is no treatment for amyloidosis, maintenance of environments with minimal stress and low exposure to infectious diseases should decrease its occurrence.<sup>73</sup>

### Capture Myopathy

Capture myopathy has been reported in Lesser Snow Geese and Ross's Geese that were captured with rocket nets and restrained for several hours. Some birds (18 hours post-capture) were stiff and unable to fly but could walk. Others were unwilling to walk and appeared depressed. The only gross necropsy lesions were pallor of the skeletal muscles and pulmonary and hepatic congestion. Histologically, there was lysis and fragmentation of skeletal muscle fibers.



**FIG 46.18** Severe foot infections can progress to osteomyelitis. In this case, osteomyelitis secondary to bumblefoot was resolved, but resulted in ankylosis of the tarsometatarsal phalangeal joint.

The prevalence and importance of this condition in captured free-ranging waterfowl are unknown, but a small number of restrained birds are stiff and reluctant or unable to fly when released (see Chapter 48).

### Botulism

Botulism (limberneck, western duck sickness, duck disease, alkali poisoning) occurs from the ingestion of toxins produced by the bacterium *Clostridium botulinum*. It is a paralytic, often fatal disease. Waterfowl die-offs are usually caused by type C toxin. *C. botulinum* is commonly found in wetlands (especially those overlying limestone and alkaline water). It is resistant to heat and drying and remains viable for years in a spore form. The vegetative form produces the toxin and requires dead organic matter and an anaerobic environment. The presence of carcasses of invertebrates and vertebrates, rotting vegetation, poor water quality and high temperatures promote growth of *C. botulinum*. High temperature and vertebrate carcasses also promote maggot infestations. Birds that eat maggots may consume the toxin at the same time.<sup>28</sup>

The botulism toxin affects peripheral nerves and results in paralysis of voluntary muscles and an inability to sustain flight. Once paralysis of leg muscles has occurred, ducks may attempt to swim using their wings. By comparison, birds with lead poison-

ing retain their ability to walk and run. As the disease progresses, paralysis of the neck muscles results in an inability to hold the head erect. Death from drowning is common. Many affected waterfowl (75 to 90%) can be saved by being provided fluids, a cool environment and antitoxin.<sup>28</sup> Removing toxins and maggots from the stomach by gavage may increase the recovery rate.

Disease prevention requires control of fluctuating water levels during hot summer months and a prompt removal of animal protein to decrease the source of toxin production and maggot infestations. A single waterfowl carcass can produce several thousand toxic maggots. A duck can become intoxicated by eating only two to four maggots. Carcasses should be buried or burned. The toxin is quite stable in the environment. Botulism outbreaks have occurred worldwide. U.S. outbreaks usually occur west of the Mississippi River. In the United States and Canada, most outbreaks occur from July to September, although cases are seen in south Florida on a year round basis.<sup>28</sup> A commercial type C toxoid is available for mink and has proven to be effective in birds. One-half of the dose recommended for mink should be used in birds (Harrison GJ, unpublished).

### Lead Poisoning

Lead poisoning is a common problem in waterfowl because of the ingestion of lead shot. Less common causes are ingestion of lead fishing sinkers, mine wastes, paint pigments, bullets and other lead objects. Lead shot has been banned in many states for hunting, but is still used in skeet shooting.<sup>82</sup> Within the United States, annual waterfowl losses from lead poisoning are between 1.6 to 2.4 million birds. Lead poisoning in Trumpeter Swans occurred when drought conditions caused water levels to drop, allowing birds to reach previously unattainable shot.<sup>15</sup>

Clinical signs of lead intoxication include weight loss, weakness and depression, bright green diarrhea, anorexia and variable neurologic disorders such as leg paresis, wing droop and abnormal head tremors.<sup>15</sup> Blood (2 to 5 ml) should be collected in lead-free tubes containing sodium citrate. Treatment includes use of chelating agents such as Ca<sup>+</sup> disodium EDTA, DMSA, PA and DTPA (see Chapter 37).<sup>28</sup>

Gastric lavage and endoscopy can be used to remove lead shot from the ventriculus. Birds are fasted for 8 to 12 hours, masked down with isoflurane and intubated. A flexible polyvinyl chloride tube (1.5 cm in diameter) is lubricated and passed (approximately

TABLE 46.8 Typical Disease Prevalence in Captive Anseriformes

Type	Condition*	Number Affected
<b>Viral</b>	Duck Virus Enteritis	30
<b>Bacterial</b>	Pasteurellosis	2
	Tuberculosis	33
	Erysipelas	3
	Salmonellosis	1
<b>Fungal</b>	Aspergillosis	99
	Candidiasis	62
<b>Parasitism</b>	Haemoproteus	1
	Capillariasis	6
	Echinuriasis	1
	Amidostomiasis	2
	Tetrameriasis	4
	Cestodiasis, intestinal	16
	Schistosomiasis, intestinal	19
	Trematodiasis	6
<b>Toxicity</b>	Botulism	28
	Talon	6
<b>Noninfectious</b>	Amyloidosis	122
	Gout	52
	Bumblefoot	3
	Predator	106
	Foreign Body, GI	3
	Vandalism	5

Important pathologic conditions in 1528 captive Anseriformes necropsied at the National Zoological Park, 1975 - 1984. Adapted from Montali.<sup>73</sup>

\*An individual bird may have had more than one condition.

110 cm in a Trumpeter Swan) to the cranial aspect of the ventriculus. The bird is tilted, head down, at a 45° angle on the table. Large quantities of warm water are pumped into the ventriculus using a 140 ml gastric lavage syringe. Water pressure and gravity will force most of the food, grit and lead pellets out of the intestinal tract. Radiographs can be used to confirm that the lead pellets have been removed. A colonoscope can be used to visualize and remove remaining lead particles (see Chapter 37).<sup>15</sup>

### Zinc Poisoning

Zinc toxicity has been reported in captive Anseriformes following the ingestion of pennies minted after 1983 (containing 98% zinc) or metal fence clips (96% zinc). Clinical signs include weight loss, depression, anorexia and posterior paresis. Normal serum levels of zinc are 1.84 to 4.65 µg/g; normal liver levels are 34.9 µg/g. Abnormal levels seen in an affected group of ducks were 12.6 to 16.6 µg/g (serum) and 242 to 548 µg/g (liver). Pathologic findings include necrotizing ventriculitis and degenerative pancreatic lesions re-

sulting in acinar atrophy and ductular proliferation. Exposure to a penny for two months in the ventriculus is sufficient to cause toxicity.<sup>121</sup> Treatment consists of endoscopic removal of the foreign bodies and chelation therapy (see Chapter 37).

### Mycotoxicity

Mycotoxins are toxic metabolites produced by molds. Mold-contaminated foods are frequently unpalatable and avoided by free-ranging waterfowl, while captive birds may be forced to consume the moldy food. Diagnosis in field cases is difficult, because some toxins have subtle or nonspecific effects. Clinical changes may be delayed and animals may have changed food by the time symptoms occur, making it difficult to find the source of the toxin. Moldy food may contain more than one toxin, and analytical procedures for identification of toxins are not readily available. Aflatoxicosis, fusariotoxicosis and ergotism have been described in free-ranging waterfowl.

Aflatoxin poisoning is caused by the metabolic by-product of *Aspergillus flavus*, which can be found in feed (especially peanut products and corn). Aflatoxin has been associated with liver cirrhosis in older ducks. Nodular hypoplasia or hepatoma may occur in chronic cases. Young ducks exposed to aflatoxin die at one to two weeks of age, showing signs of inappetence, depressed growth, cyanosis of the feet and legs (caused by subcutaneous hemorrhages), ataxia, convulsions and opisthotonos.<sup>111</sup> Gross lesions include a slightly enlarged, putty-colored liver, pale and slightly swollen kidneys, and petechiae on the kidneys and pancreas. In birds over three weeks of age, the liver is firm and slightly shrunken and has a reticulated pattern; ascites and hydropericardium and petechiation may also be noted. The LD<sub>50</sub> for day-old ducklings is approximately 0.3 to 0.4 mg/kg.<sup>111, 116</sup>

Immunosuppression with chronic aflatoxicosis may be a problem with waterfowl as it is with some other species. The significance of aflatoxicosis in free-ranging waterfowl is unknown. The disease has occurred among Mallards consuming waste peanuts in the southern United States. Birds recover quickly from short-term sublethal exposure to aflatoxin once the source of toxin is removed from the diet.<sup>116</sup>

Fusariotoxicosis is caused by *Fusarium* spp., which are common saprophytes and parasites on plants. Their presence on cereal grains is important because of the variety of toxins they produce, including zearalenone (F<sub>2</sub>) and tricothecene toxins (including

T<sub>2</sub>). Zearalenone was found to interfere with sperm production in ganders but not with egg production in geese (it causes hyperestrogenism in domestic mammals). Clinical signs of T<sub>2</sub> intoxication include vomiting, thirst and depression. Geese force-fed 60 to 90 grams of contaminated grain developed head and leg tremors and died within 19 hours. Gross lesions were restricted to mucosal necrosis in the esophagus, proventriculus and ventriculus.<sup>116</sup>

Ergotism is caused by toxic alkaloids formed by the fungus *Claviceps purpurea*, which parasitizes and forms sclerotia in place of the seed in certain cereal grains. Heavy mortality was seen in two- to four-month-old Muscovy Ducks fed wheat containing 1.7% ergot sclerotia. The birds died 48 hours after developing lethargy and diarrhea. Older birds were not affected. Necrosis and gangrene of the extremities, which occur in mammals, have not been reported in waterfowl. Ergotism is unlikely in free-ranging waterfowl that have a choice of food.<sup>116</sup>

### Algal Toxins

Algae blooms usually occur in eutrophic waters in warm, sunny weather. The algae must accumulate in shallow water so that the liberated toxin will not be diluted. Algae often concentrate on the downwind shore of lakes. Some of the common genera of blue-green algae implicated in animal intoxication include *Nodularia*, *Rivularia*, *Aphanizomenom*, *Oscillaria*, *Anabaena*, *Microcystis*, *Collosphaerium*, *Nostoc* and *Gloeotrichia*. An *Anabaena* bloom on Storm Lake in Iowa was associated with the deaths of 5,000 to 7,000 Franklin's Gulls, 560 ducks, 400 coots and 200 pheasants. Death occurred two to ten minutes after ingestion of a minimal lethal dose. The very fast death factor of this *Anabaena* was found to be a depolarizing neuromuscular blocking agent that was rapidly absorbed following ingestion.

Clinical signs may be peracute prostration and death, restlessness, blinking of the eyes, repeated swallowing, salivation and regurgitation. There is no specific treatment, but oral administration of charcoal and mineral oil has been suggested. Access to clean water and food should be provided. There are no specific histologic lesions and there are no tests to detect these toxins. Diagnosis is subjective and is based on identifying toxic algae in an affected bird's environment and ruling out other etiologies of similar clinical signs.<sup>116</sup> Control in the wild is not practical. Algae blooms may be controlled in ponds with copper sulfate, or by increasing water flow to remove nutri-

ents and dilute the algae; however, copper sulfate can also be toxic.

### Marine Dinoflagellates

Waterfowl may be poisoned by mollusks living in areas affected by "red tides." Several thousand Lesser Scaup died in Florida as a result of "red tide" caused by *Gymnodinium breve*. *Gonyaulax catenella* and *G. tamarensis* are other dinoflagellates that can be a problem. Clinical signs include weakness, reluctance to fly, dehydration, nasal and oral discharge, lacrimation, edema of the nictitating membrane, bilateral mydriasis, chalky yellow diarrhea, tachypnea, tachycardia and depressed blood pressure.<sup>44</sup> No specific gross or histologic lesions have been described. Recovery occurred rapidly when affected birds were placed in fresh water.<sup>116</sup>

### Plant Toxicities

Some plants may be toxic to waterfowl. A seven-week-old goose was treated for sudden onset of ataxia, progressive paresis, recumbency and prolific salivation. Its pen mate died with similar clinical signs. Microscopic lesions included occasional hemosiderin-containing macrophages in the proximal lamina propria of the small intestine. Multifocal loss of cardiac muscle striation was consistent with oleander toxicity. Oleander leaves were found in the proventriculus and ventriculus.<sup>60</sup>

### Chemicals

Fertilizers or pesticides should not be used around birds or where runoff may enter animal enclosures. In one case, several ducks died with evidence of coagulopathy while others in the same enclosure were bleeding and had prolonged prothrombin times. The poisoning was attributed to the ingestion of insects that had consumed brodifacoum (Talon). Diagnosis was confirmed by finding 43 ppm brodifacoum in the liver.<sup>73</sup>

### Tumors

Spontaneously occurring tumors are infrequently described in waterfowl. The tumors that do occur are histologically similar to those seen in mammals. At the Philadelphia Zoo, between 1901 and 1963, there were only 19 primary neoplasias in the 19,000 birds examined. The largest number of spontaneous tumors was reported in 1949 when 148 hepatomas were found in 1,113 ducks. The youngest ducklings died when they were 143 days old, 14.5% died between three months to one year of age, 23.7% died between 1 and 1.5 years of age and 3.5% died between 1.5 and 2 years of age. Periportal inflammation and degen-

eration, bile duct proliferation, regeneration and nodular hyperplasia of liver cells with adenomatous formation were common.

This report of spontaneously occurring hepatomas is important today in view of tumors resulting from the feeding of Brazilian ground nut meal. Young ducks are most susceptible to aflatoxin toxicity (see Color 20). Hepatic tumors developed in 5 of 37 one-week-old Khaki Campbell ducklings when fed aflatoxin. Similar lesions developed in 11 ducks that were fed a ration containing 0.5% Brazilian ground nut meal for 14 months.<sup>87</sup>

### Egg-related Peritonitis

Egg-related peritonitis is life-threatening and requires intense and aggressive care.<sup>117</sup> It is not uncommon to find old remnants of egg adhered to the abdominal wall or viscera of waterfowl hens at necropsy. These findings are incidental and are usually not related to the cause of death. It is assumed these are eggs that were laid intra-abdominally and were partially reabsorbed (see Chapter 29).

## Infectious Diseases

A compilation of data on a variety of bacterial, fungal, parasitic and viral diseases seen in waterfowl can be found in Table 46.9. The reader is also referred to the appropriate etiology chapters elsewhere in this book. Few investigations have been performed on the pharmacokinetics of antibiotics and other therapeutics in free-ranging and captive waterfowl. Antibiotics and other therapeutics used in other aspects of avian medicine can often be used in waterfowl at similar dosages.

### Aspergillosis

Aspergillosis is commonly seen at necropsy in *Anseriformes*. Diagnosis and treatment can be difficult (see Chapter 35 and Color 22).<sup>48,80,86,120</sup>

### Parasites

Schistosomes in the genera *Trichobilharzia* and *Dendritobilharzia* were considered the cause of high mortality rates (90%) in a group of geese. The principal pathologic changes included thrombosis of the caudal mesenteric vein, fibrinohemorrhagic colitis and hepatomegaly. This parasite is frequently found in waterfowl but is rarely associated with disease. Weight loss and lameness were the principal clinical findings. Parasites were identified in the lumen of the thrombosed vessels. In general, lesions associated with schistosomes are secondary to reactions to the

**TABLE 46.9 Bacterial, Fungal, Viral and Parasitic Diseases of Anseriformes\***

DISEASE/AGENT	HOST RANGE	TRANSMISSION	CLINICAL SIGNS	TREATMENT/CONTROL
Aspergillosis <i>Aspergillus fumigatus</i> <sup>8,28,44,93,111,116</sup>	All species varying susceptibility	Airborne spores; moldy litter or feed	Respiratory signs; chronic debility	Prevent exposure; surgical excision of affected tissue.
Avian cholera <i>Pasturella multocida</i> <sup>8,14,28,50,93,111,116</sup>	Most species highly susceptible; epidemics in wild waterfowl and aviaries, mortality up to 50%	In excrement and respiratory secretions; recovered birds are carriers	Peracute death; acute form - anorexia, dyspnea, diarrhea, mucoid oral discharge; chronic form - dyspnea, diarrhea	Isolate affected birds; burn/bury corpses; autogenous bacterin every three months <sup>9</sup> ; A, B, E, F, H*
Avian diphtheria, contagious epithelioma, avian pox, Poxvirus <sup>8,28,111,116</sup>	Undefined, most Anseriformes; seen in Greenwing Teal, Canada and Hawaiian Geese, Mute and Tundra Swans, Mallard Duck	Mosquitoes, direct contact, skin wounds	Wart-like growths on unfeathered skin, dysphagia, dyspnea if lesions in pharynx	Self-limiting, course long; supportive care; control vectors; efficacy/safety fowl pox vaccine undetermined
Avian encephalomyelitis, epidemic tremors Picornavirus <sup>8,111</sup>	All species; affects chicks 1-2 weeks old	Egg transmission possible	CNS signs in chicks, decreased egg production	No treatment, vaccinate
Avian influenza, fowl plague Orthomyxovirus <sup>8,44,93,111</sup>	Ducks and other anseriformes; rare; not reported in wild waterfowl	Inhalation, direct contact, excrement	Sinusitis - mild to severe, mucopurulent or casseous	Reduce stress and crowding, supportive care
Chlamydiosis, ornithosis <i>Chlamydia psittaci</i> <sup>8,28,44,93,111</sup>	All species, young mainly; 20-70% mortality in ducklings possible	Excrement; inhalation; asymptomatic carriers	Conjunctivitis, rhinitis, sinusitis, diarrhea, weakness	Chlortetracycline 0.044% in feed 3-6 weeks; doxycycline
Colibacillosis <i>Escherichia coli</i> <sup>8,44,93,111</sup>	All species; common	Excrement; ingestion	Septicemia, death, diarrhea, decreased hatchability, omphalitis, salpingitis, bumblefoot	Sanitation, antibiotics based on sensitivity; A, B, G*
Duck plague, duck viral enteritis Herpesvirus <sup>8,11,28,50,93,111,116</sup>	Ducks, geese, swans; susceptibility varies; sporadic outbreaks, see in spring; mortality up to 100%	Excrement - ingestion or inhalation, free-ranging waterfowl carriers	Peracute death, hematochezia, depression, photophobia, epiphora	No therapy, live-virus vaccine, <sup>9</sup> prevent access to carriers and outside water
Duck virus hepatitis Picornavirus <sup>8,92,93,111,116</sup>	Seen in domestics; not reported in free-living waterfowl; ducklings 2-6 weeks old ≤ 90% mortality	Excrement; ingestion or parenteral	Peracute death within hours; sluggishness, paddling of feet, CNS signs	Hyperimmune serum, vaccinate breeders MLV vaccine before laying; vaccinate day old chicks <sup>9</sup>
Eastern and western encephalomyelitis virus, Alpha Virus/Togavirus <sup>8,111,116</sup>	All species; clinical disease rare; not reported in free-living waterfowl	Insect vectors	Asymptomatic or CNS signs; morbidity and mortality highest in chicks	None; vaccine for horses used in raptures and pheasants
Erysipelas <i>Erysipelothrix insidiosus</i> <sup>8,44,93,111</sup>	All, 30% mortality in ducklings	Wound infection or ingestion	Depression, diarrhea, inappetance	D;* Bacterin for turkeys may be effective by SC or aerosol (ducklings)
Goose gonorrhoea, Neisseria-like organism <sup>106,116</sup>	Geese, captive birds only	Direct cloacal contact; egg transmission	Cloacitis, inflamed/ulcerated phallus; 10% ganders die	Reference 106
Goose virus hepatitis, goose influenza, goose plague Parvovirus <sup>8,93,111,116</sup>	Common in Europe; not seen in US; domestic goslings < 30 days of age; mortality ≤ 80%	Highly contagious	Coryza, diarrhea, ataxia; survivors stunted, loss feathers neck and back	Hyperimmune serum; attenuated virus vaccine in Hungary
Leukosis/sarcoma virus <sup>8</sup>	All species; rare		Tumors of the parenchymous organs	
Necrotizing enteritis agent unknown, possible flagellate, enteric bacteria, <i>Clostridium</i> sp. <sup>116</sup>	Seen in free-living waterfowl, captive geese, mallards; common in breeder ducks, mortality ≤ 40%	Stress predisposes	Depression, subcutaneous and pulmonary hemorrhages, mucoid necrotic enteritis	Neomycin sulfate 0.02% in food for 2-3 weeks; reduce stress
New duck disease, infectious serositis <i>Cytophaga</i> sp. <sup>8,14,44,93,111,116</sup>	Ducks, geese, swans; sporadic outbreaks in wild; more common domestic flocks; ducklings = acute; older birds = chronic	Probably egg-transmitted	Lethargy, ocular discharge, diarrhea, ataxia, torticollis, often on back paddling legs, acute death	Reduce crowding; bacterin at 2-3 weeks of age; live vaccine experimental <sup>9</sup> ; A, C, D, H*
Newcastle disease Paramyxovirus NDV (serotype group 1) <sup>111</sup>	All species; uncommon; few reports clinical disease	Fecal spread likely	Respiratory, conjunctivitis, gastrointestinal, CNS signs	Vaccination for poultry may effective if legal; depopulate
Pseudotuberculosis <i>Yersinia</i> sp. <sup>8,44,111</sup>	All species; not uncommon at end of severe winter	Contaminated food supply (rodents and wild birds)	Non-specific clinical signs	
Reticuloendotheliosis Retroviruses <sup>116</sup>	Unknown; rare; high mortality in 2 week old domestic ducks	Unknown	Tumors of RE cells and organs	
Salmonellosis <i>Salmonella</i> spp. <sup>8,28,44,93,111,116</sup>	All; rare in free-ranging; common in captivity, domestic ducklings disease < 2 weeks of age	Excrement; ingestion; carried by rodents, insects, water, wild birds	Depression, sudden death; acute septicemia, enteritis	Sanitation; remove carriers; antibiotics may reduce disease but not stop carriers; B, F, I*
Tuberculosis, Mycobacterium avian, spp. <sup>8,44,111,116</sup>	All; rare in free-ranging; common in captivity	Excrement	Emaciation, diarrhea, debility; often dead, no symptoms	Depopulate infected birds, flame environment; potential treat rare birds

table continued on next page

\* see Chapters 18, 32, 33, 35 and 36 for further information; treatments: A — sulfaquinoxaline 0.025-0.05% in feed, or penicillin-streptomycin 50,000 U/kg IM; B — sulfadimethoxine-ormetoprim 0.02-0.08% in feed; C — sulfamethazine 0.2-0.25% in drinking water or feed; D — penicillin 50,000 U/kg IM; E — tetracycline IM; F — chlorotetracycline 300-400 g/ton feed; G — lincomycin-spectinomycin IM; H — novobiocin 350 g/ton feed; I — furazolidone 0.022-0.044% in feed.

DISEASE/AGENT	HOST RANGE/TRANSMISSION	CLINICAL SIGNS	DIAGNOSIS	TREATMENT/CONTROL
Acuaria <i>Echinuria uncinata australis</i> <sup>5</sup>	Unknown. Daphnia is intermediate host	Proventricular ulceration, anorexia, weight loss, anemia, death		Increase water flow to decrease daphnia; J, L, M, N, O*
Air sac mites <i>Cytodites nudus</i> <sup>111</sup>	Anseriformes are aberrant hosts		Seen in respiratory passages and air sacs	Difficult
<i>Avioeserpens taiwana</i> <sup>44</sup>	Ducks in Taiwan, Indochina and North America; cyclops is intermediate host	Parasite-induced masses, submandibular, thigh, shoulder		Remove masses
Capillariasis <i>Capillaria contorta</i> <sup>8,44,111</sup>	All; rare	Occasionally, anorexia, dysphagia, diarrhea, necrotizing enteritis	Fecal flotation; barrel-shaped eggs, bipolar plugs; parasites in esophagus, crop, small intestine	J, K, L, N, O*
Cecal worms <i>Heterakis</i> sp. <sup>8,44,111</sup>	All; rare	Common at postmortem; rarely clinical signs	Fecal flotation; ellipsoidal, thick shelled eggs, 60x40µ	
Coccidiosis <i>Eimeria</i> sp., <i>Tyzzeria</i> sp., <i>Wenyonella</i> sp. <sup>8,22,93,111</sup>	All; common; mortality ≤ 10% in ducklings; direct transmission	Enteritis, emaciation, anemia, death, renal disease in geese	Fecal flotation; intestinal lesions with merozoites	Amprolium; B, C, Q*
Conjunctival worms <i>Oxyuris mansonii</i> <sup>111</sup>	All; rare	Conjunctivitis, blepharitis, epiphora	Direct visualization; slender, thread-like worms	Manual removal, dilute ivermectin topically
Gape worms of geese <i>Cyathostoma bronchalis</i> <sup>31,44,111</sup>	Geese; mortality highest in goslings. Carrier adults	Depression, anemia, coughing, blood-tinged tracheal mucus	Parasite or eggs in tracheal mucus or feces; worms in bronchi and trachea	L, O, P*
Gizzard worms (several nematode species) <sup>8,28,111</sup>	Ducks, geese, swans; mortality highest in young; direct life cycle	Unthriftiness, ventricular dysfunction	Eggs in feces; hairlike worms under horny gizzard lining	K, L, N, O*
Heartworms <i>Sarcoca eurycerca</i> <sup>111</sup>	Whistling Swan, White-faced Goose; rare	Depression, death, myocardial necrosis	Microfilaria in blood smear; 2-3 adults/host	Unknown
Leeches <i>Hirudinea</i> sp., <i>Theromyzon</i> <sup>12,21</sup>	Many species; occasional	Anemia, conjunctivitis, asphyxiation, bloody nasal discharge		Drain and disinfect pond
Lice - shaftlice, wetfeather <i>Holomenopen leucocytozoon</i>	Unknown	Moist-appearing feathers; louse feeds on quill; severe irritation		Malathion powder
Lice - chewing <i>Mallophaga</i> spp. <sup>8,44,111</sup>	All; common; life cycle 2-3 weeks	Mainly nonpathogenic; feed on feather debris may cause local irritation	Adults or eggs on feathers	5% carbaryl powder
Ocular trematodes <i>Philophthalmus gralli</i> <sup>111</sup>	Ducks, geese	Conjunctivitis, epiphora	Direct visualization 5 x 1.2 mm	Manual removal
Sarcocystis <i>Sarcocystis ridleyi</i> <sup>9</sup>	Ducks, especially dabblers; more common in adults	Asymptomatic	Small white rice grain masses in muscles	Nonpathogenic
Schistosomiasis <i>Dendritobilhargia pulverulenta</i> <sup>15</sup>	Diving ducks, geese	In arteries, not veins; multisystemic signs; granulomatous encephalitis	Flukes in aorta and cranial branches	
Simulian black fly <sup>111</sup>	Many species	Anemia, toxicity; transmit leukocytozoon and microfilaria		4% malathion inside buildings
Spirurids <i>Streptocara</i> spp. <sup>105</sup>	Ducks; common	Proliferative gastritis, vomiting, weight loss	Parasites in gizzard or under mucus lining gizzard and proventriculus	Unknown
Tapeworms <sup>8,23,111</sup>	All; not uncommon; invertebrate or fish = intermediate host	Asymptomatic; catarrhal enteritis, diarrhea, emaciation	Fecal flotation; onchosphere proglottids in feces	R*
Tetrameres <sup>44</sup>	Rare; grasshopper or anthropod is intermediate host	Poor growth; proventricular dystrophy; anemia	Parasite in mucus glands proventriculus	J, K*
Toxoplasmosis <i>Toxoplasma gondii</i> <sup>111</sup>	Geese	Anorexia, anemia, emaciation, diarrhea, CNS signs	Complement fixation; Sabin-Fellman Dye test	C, D*
Trematodes/flukes (numerous species) <sup>8,23,111</sup>	Ducks, geese; not uncommon; mollusk is intermediate host	Unthriftiness, enteritis or hepatitis depending on location	Fluke eggs in feces	Difficult; O*

\* see Chapters 18, 32, 33, 35 and 36 for further information; treatments: A — sulfaquinoxaline 0.025-0.05% in feed, or penicillin-streptomycin 50,000 U/kg IM; B — sulfadimethoxine-ometoprim 0.02-0.08% in feed; C — sulfamethazine 0.2-0.25% in drinking water or feed; D — penicillin 50,000 U/kg IM; E — tetracycline IM; F — chlorotetracycline 300-400 g/ton feed; G — lincospectinomycin IM; H — novobiocin 350 g/ton feed; I — furazolidone 0.022-0.044% in feed; J — piperazine 200-1000 mg/kg PO, 6-10 g/gal drinking water for four days; K — piperazine 45-200 mg/kg PO single dose or 6-10 g in 4 liters of drinking water; L — mebendazole 5-15 mg/kg PO for two days; M — thibendazole 100 mg/kg PO; N — thibendazole 200-500 mg/kg PO; O — levamisole 25-50 mg/kg PO; P — ivermectin 1% (200µg/kg SC); Q — furazolidone in the feed at 0.033% for 14-21 days; R — niclosamide (toxic to geese) 250 mg/kg PO, droncit, Bunamadine PO.



eggs. Lesions associated with adult schistosomes have been reported in the liver, intestines and lung, and reactions to eggs have been reported to cause encephalitis. The high mortality in this group of birds was believed to have been potentiated by placing a group of birds that normally spend the summer in an Arctic marine environment into a fresh water pond.

### Proventricular Dilatation

A syndrome similar to that described with neuropathic gastric dilatation in Psittaciformes was documented in two free-ranging Canada Geese. The birds were found in an emaciated state. Postmortem findings included pectoral muscle atrophy and a dilated, thin-walled proventriculus. Nonsuppurative encephalitis with lymphoplasmacytic perivascular cuffing was the principal histologic lesion (see Chapter 32).

## Common Surgical Procedures

Most surgical techniques used in psittacines can be applied to waterfowl. Anseriformes normally have a high concentration of subcutaneous and intra-abdominal fat, making the delineation of anatomic structures (particularly vessels) difficult. The transection of large vessels coursing through the fat is common. Blood that may be present on feathers following a surgical procedure should be carefully removed from goslings, ducklings or cygnets to prevent the parents from traumatizing the area through excessive grooming.<sup>44</sup> Most waterfowl can be easily managed in a hospital situation although some do better when their mate or a companion is with them. Birds that are stressed do well in a quiet, darkened enclosure.

### Pinioning

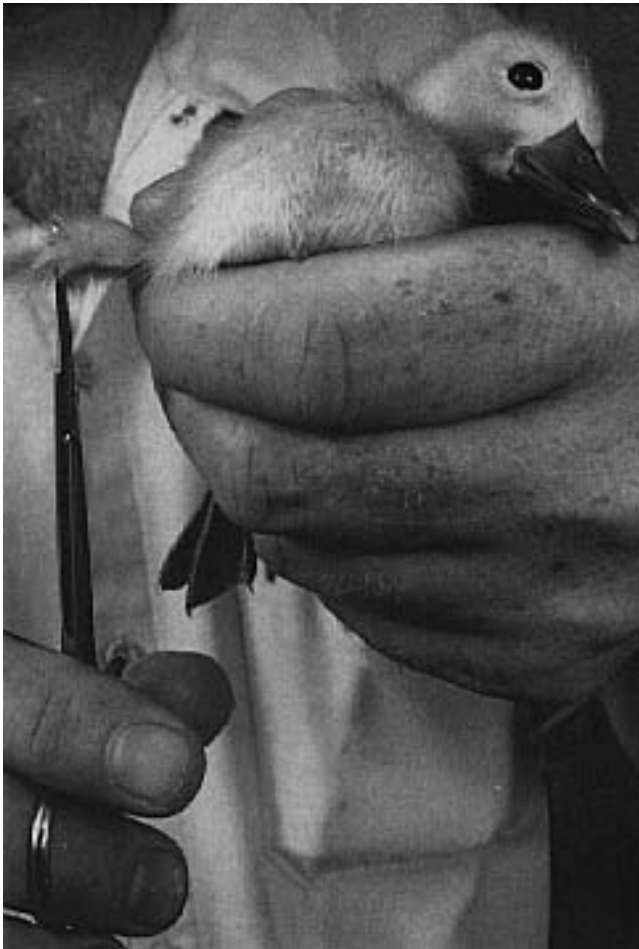There are various surgical means of deflighting birds including patagiotomy,<sup>68,89</sup> joint ankylosis,<sup>111</sup> tendonectomy<sup>71,94</sup> and pinioning.<sup>44,68,71,89,94,111,114</sup> The most common procedure is pinioning. When waterfowl are one to four days of age, they can be quickly and easily pinioned without anesthesia. This procedure causes very little hemorrhage or stress to young chicks. Early pinioning obviates the need for a more complicated procedure at a later date. Toe nail clippers,

scissors or other cutting device (suture scissors and wire cutting scissors work well) are used for the procedure. The chick is held upside down, preferably with one wing outstretched, and the alula (second digit) is held out from the carpus (Figure 46.19). The third and fourth metacarpals are then cut as close to the alular and carpus as possible. This will remove all of the primary flight feathers. Although no further treatment is usually necessary, bleeding can be controlled with silver nitrate, Monsel's solution or radiosurgery. The stump can be sprayed with an antibiotic powder.

In older birds, pinioning can be performed at the level of the carpus, but is usually performed at the proximal end of metacarpals III and IV. The procedure can be performed using a local anesthetic in a bird that is manually restrained or the bird may be anesthetized with isoflurane (Figure 46.20). Feathers are removed from the carpus to midway on metacarpals III and IV. A tourniquet is placed on the wing at the level of the humerus. The skin is prepped with povidone iodine and alcohol. A ligature of absorbable suture of approximately 2-0 size is placed around the proximal end of metacarpal IV, incorporating as much interosseous tissue as possible. A similar ligature is placed around metacarpal III, also incorporating as much interosseous tissue as possible. These sutures are designed to ligate the interosseous metacarpal artery, which passes between these bones. A figure-of-eight suture placed around and between the metacarpal bones has been suggested, but in the author's opinion it is inferior to the described technique.

The skin is then incised between mid-shaft and the proximal one-third of metacarpals III and IV. Muscle and fascia are cut deep to the bone. The skin and muscle are bluntly dissected and pushed proximally using a gauze pad to expose the metacarpal bones. The bone should be exposed as close to the base of the alula as possible. Metacarpal bones III and IV are cut as proximal as possible with a bone saw. Rongeur's or nail trimmers tend to splinter the bone. Vessels are ligated if necessary. The skin and muscle are pulled back over the bone end and excess tissue is removed. Muscle and fascia should be sutured over the bone to help pad the ends. Two or three overlapping horizontal mattress sutures are generally sufficient for closure, and the end of the incision can be sealed with tissue adhesive. Skin should be sutured loosely over the bone ends to prevent pressure necrosis.

Although bandaging is not usually required, a pressure wrap may be placed over the stump for several



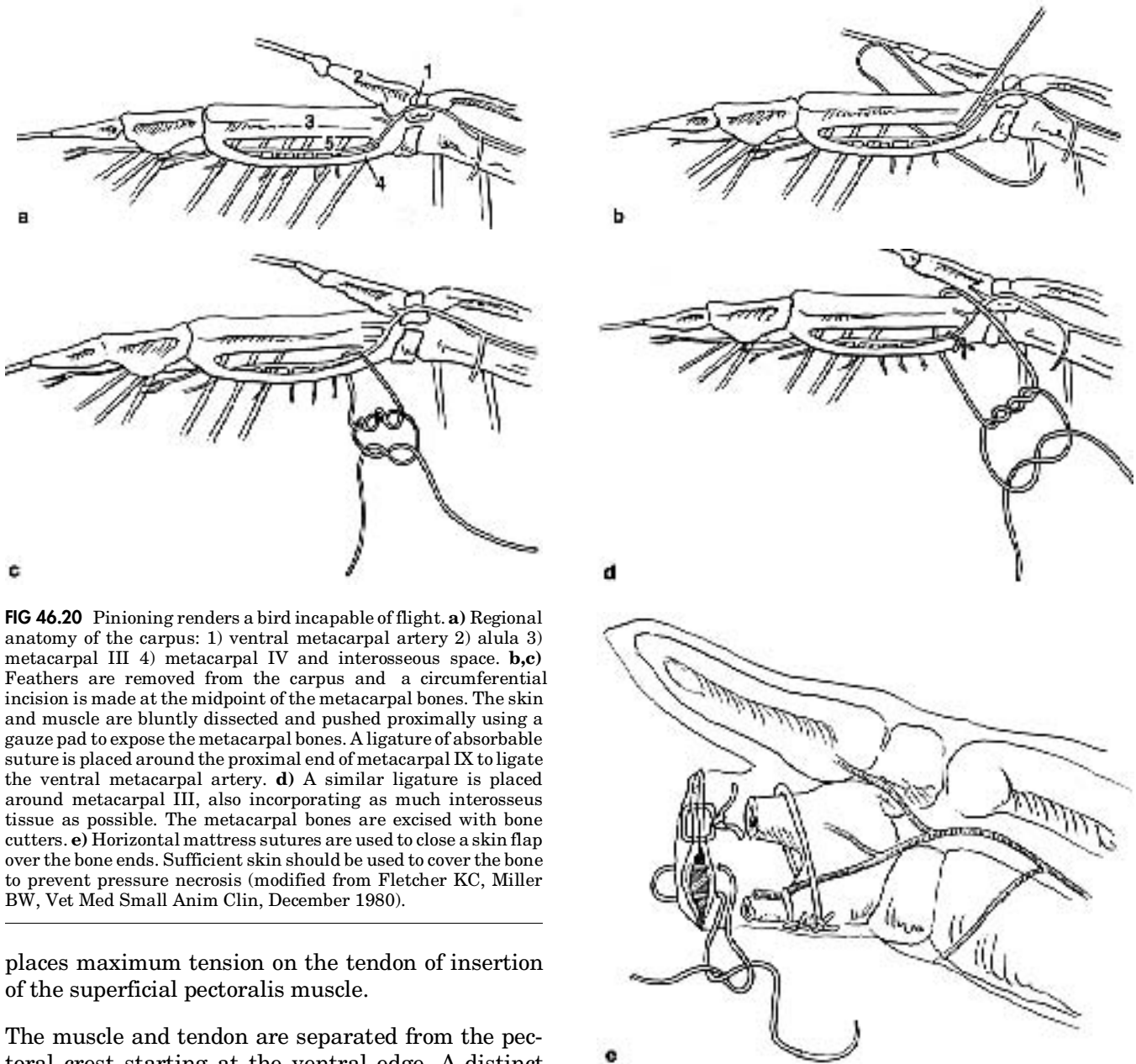
**FIG 46.19** Pinioning is easiest in two- to three-day-old birds. A pair of sterile scissors (top) is used to remove metacarpals III and IV, while leaving the alula intact. Bleeding is minimal (bottom) and can be controlled with a silver nitrate stick, if necessary (1994 Busch Gardens Tampa. All rights reserved.).

days to control mild hemorrhage and protect the incision. Birds should be restricted from the pool for three to seven days to prevent water and bacteria from contaminating the incision. If tissue glue is used to seal the skin, the wound may be sufficiently protected to allow immediate release to water.<sup>111</sup> The comparison of a pinioned and non-pinioned wing is shown in Figure 46.21. A modification of this procedure utilizes elastic castration bands at the base of the metacarpal and excision of bone and tissue distal with a double action bone cutter.<sup>66</sup> However, several weeks may be necessary for the stump to necrose, slough and heal. The editors do not recommend this procedure, for humane reasons.

### **Tendonectomy**

Pinioning results in an aesthetically altered bird, particularly if the wings are extended during preening or courtship behavior. Some bird keepers believe that a pinioned male will have difficulties in maintaining the necessary balance to properly mount and mate with a hen. Suggested alternatives to pinioning include removal of the extensor carpi radialis tendon (tendonectomy) or a wedge resection of the propatagium (patagiectomy). Both techniques are cosmetically and functionally unacceptable. In addition, scar tissue may form that allows the carpus to be sufficiently extended to sustain flight. This is more likely to occur in large-winged birds on windy days when the birds are able to run, jump and glide for variable distances.

Another form of tendonectomy involves removing the insertion point of the superficial pectoralis muscle. This will result in a bird that cannot fly but is cosmetically normal (Figure 46.22). To perform this procedure, the bird is anesthetized with isoflurane and placed in lateral recumbency. The feathers are removed from the ventral side of the humerus directly over the pectoral crest, distal to the level of the scapulohumeral joint. The area is aseptically prepared and the skin is incised with a bipolar radiosurgical unit in a curvilinear manner beginning just distal to the pectoral crest. The incision ends at a point proximal to the scapulohumeral joint. In most birds, the pectoral crest can be visualized through the skin. The dorsomedial aspect of the pectoral crest is the insertion point for the supracoracoideus muscle, which originates deep to the pectoralis and is the primary muscle responsible for elevation of the wing. The wing is then extended fully over the bird's back and should approach the mid-line of the body. This



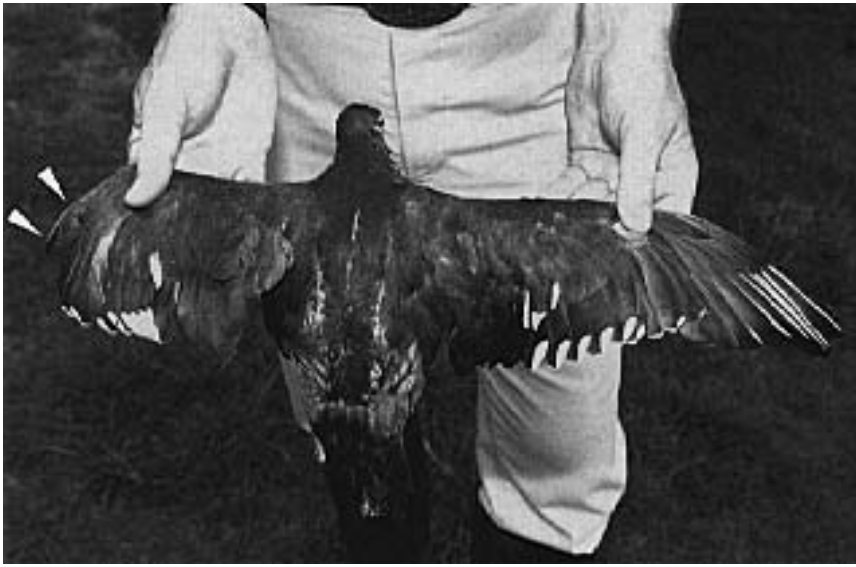
**FIG 46.20** Pinioning renders a bird incapable of flight. **a**) Regional anatomy of the carpus: 1) ventral metacarpal artery 2) alula 3) metacarpal III 4) metacarpal IV and interosseous space. **b,c**) Feathers are removed from the carpus and a circumferential incision is made at the midpoint of the metacarpal bones. The skin and muscle are bluntly dissected and pushed proximally using a gauze pad to expose the metacarpal bones. A ligature of absorbable suture is placed around the proximal end of metacarpal IX to ligate the ventral metacarpal artery. **d**) A similar ligature is placed around metacarpal III, also incorporating as much interosseous tissue as possible. The metacarpal bones are excised with bone cutters. **e**) Horizontal mattress sutures are used to close a skin flap over the bone ends. Sufficient skin should be used to cover the bone to prevent pressure necrosis (modified from Fletcher KC, Miller BW, *Vet Med Small Anim Clin*, December 1980).

places maximum tension on the tendon of insertion of the superficial pectoralis muscle.

The muscle and tendon are separated from the pectoral crest starting at the ventral edge. A distinct popping sound is audible when the final strands of muscle and tendon are separated from the crest. All of the fibrous connective tissues (tendon and periosteum) are radiosurgically removed and the site is fulgurated. The complete radiosurgical destruction of the area of insertion of the superficial pectoralis will prevent the muscle from partially reattaching, which could allow flight. Tissue fragments are debrided from the humerus by scraping with a scalpel blade. The wound should be flushed with sterile LRS. The insertion of the supracoracoideus muscle on the dorso-medial aspect of the pectoral crest should be

avoided. This muscle elevates the wing and must be intact to provide the bird with proper balance.

A second branch of the pectoralis muscle, the tensor proptagialis, crosses the shoulder cranial to the superficial pectoralis muscle. The tensor proptagialis is easily identified by grasping and pulling on the leading edge of the wing (proptagial membrane). A 2 or 3 cm section of the tensor proptagialis is removed. The incision should be carefully examined to ensure that the transection is complete. The skin is closed in a continuous or simple interrupted suture pattern. This procedure prevents a bird from flying,



**FIG 46.21** A pinioned bird. Note that the alula (arrows) remains to cover and protect the transected end of metacarpals III and IV (1994 Busch Gardens Tampa. All rights reserved.).

but allows normal flexion and extension of the wing. The wing can be moved in a relatively normal fashion for breeding or display, but there is no strength to the down stroke of the wing or control to the leading edge of the wing and thus, no lift. Aesthetically, the bird is normal. The procedure has been successful in de-fighting Anseriformes, Ciconiiformes, Pelecaniformes, Galliformes, Gruiformes, Charadriiformes and Columbiformes (see Figure 46.22) (Fletcher K, unpublished).

### Beak Repair

Beak injuries that result in an inability to eat, drink and preen will occur in waterfowl. Various attempts at applying prosthetic bills have been described.<sup>7,30,117</sup> One report described the placement of a fully threaded 0.045 Kirschner wire into each tomial margin of the maxilla. The pins were threaded until the tapping end was palpated exiting the caudal aspect of the maxilla at the rectus. The distal tips of the Kirschner wire were bent approximately 90° medially, slightly shorter than the planned rostral prosthetic edge. Prior to surgery, a two-piece template (dorsal and ventral halves) of the upper bill from a Canada Goose model was formed using fast, self-curing dental repair acrylic<sup>c</sup> at a 1.5:1 ratio of powder to liquid. The templates were then waxed to help prevent adherence to the prosthesis.

The nares and the oral cavity were plugged with cotton to prevent possible influx of dental acrylic. The

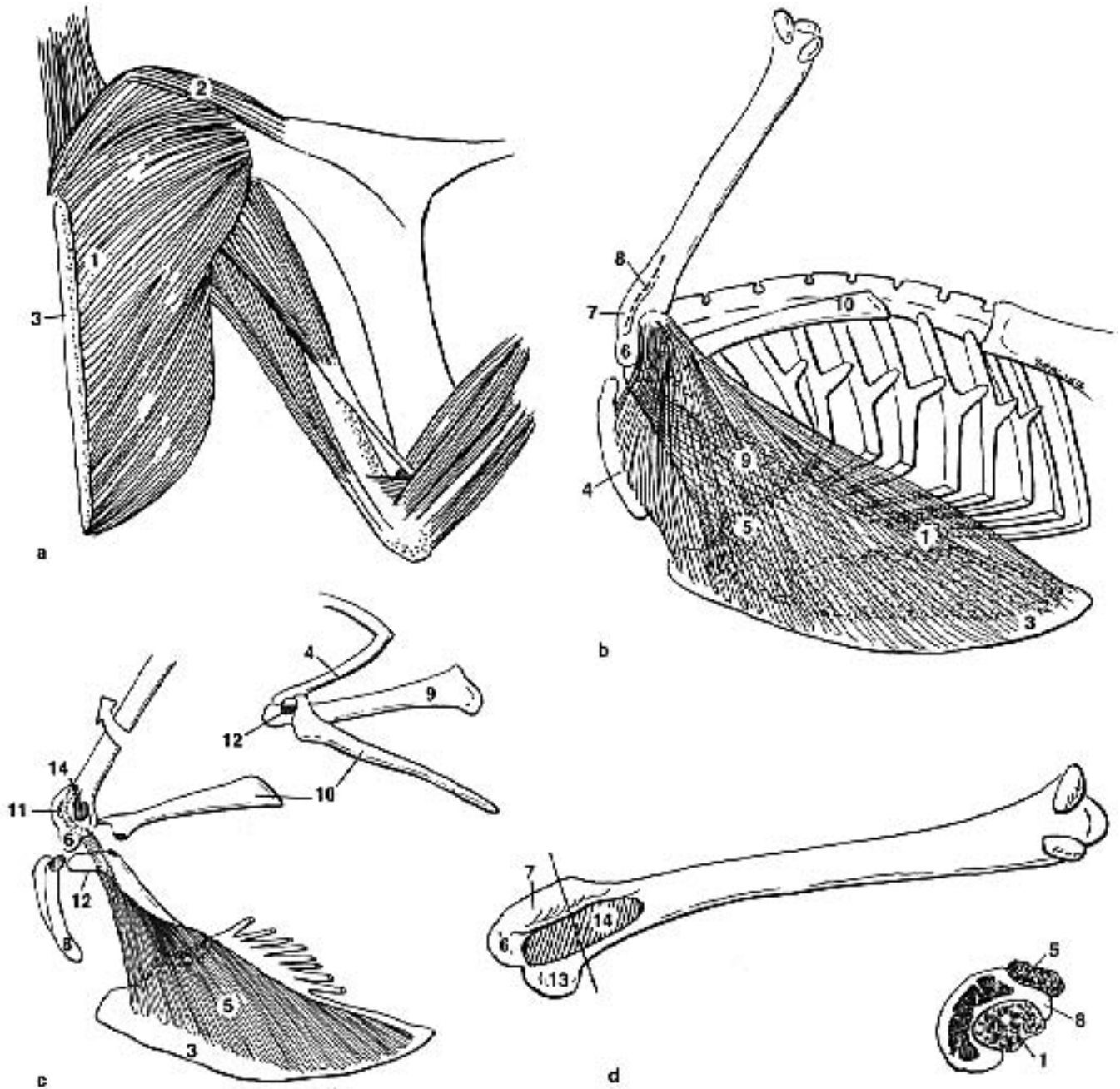
dorsal half of the template was fitted into position over the maxillary stump and the Kirschner wires. The mold was manually held in position while dental acrylic was poured onto it using a 3 ml syringe. The ventral half of the template was positioned over the semi-solid acrylic and pushed down in apposition with the dorsal half of the template. Holding the mold in position, the acrylic was allowed to harden (approximately ten minutes) and the mold was removed.

Additional acrylic was applied with a fine brush to strengthen thin areas of the prosthesis and to feather out the caudal edges of the prosthesis, both on the dorsal surface and the ventral surface where the prosthetic overlapped the bill. This feathering was carried caudally approximately 6

mm with care being taken to exclude external nasal openings. At this point, a high-speed hand-held drill with a fine grinding stone was used to do final shaping and smoothing. A grinding disk was used to create lamellae on the prosthesis. Postoperative care was uneventful, and the bird immediately started to utilize the new bill and was able to eat, drink and preen normally. This bird was monitored for six months, and there were no signs of loosening or instability of the prosthesis.<sup>117</sup> This procedure would be considered a temporary repair and would need replacement in 6 to 12 months (see Chapter 42).

### Air Sac Cannulation

Installation of an air sac cannula as emergency care for airway obstruction is described in Chapter 15. In Psittaciformes, this procedure is usually performed in the abdominal air sac. Successful cannulation of the clavicular air sac has been reported in Pekin Ducks.<sup>90</sup> The clavicular air sac is located just under the skin in the area of the thoracic inlet and can be visualized with minimal dissection (see Anatomy Overlay). Chest tubing (6.5 cm long) of the same internal diameter as the endotracheal tube was placed 2 cm into the air sac and fixed in place with a purse-string skin suture. The study showed that the heart rate, mean arterial blood pressure, PaO<sub>2</sub>, and PaCO<sub>2</sub> of cannulated birds remained unchanged from control values. There were significant increases in tidal and minute volume.<sup>90</sup>



**FIG 46.22** Superficial pectoralis tendonectomy for cosmetic deflighting: **a)** The insertion point of the 1) superficial pectoralis muscle and the 2) tensor propatagialis can be excised. **b)** A curvilinear incision (dotted line) is made from a point distal to the pectoral crest extending to a point proximal to the scapulohumeral joint. The wing is then extended fully over the bird's back and should approach the mid-line of the body. This places maximum tension on the tendon of insertion of the superficial pectoralis muscle. **c)** The superficial pectoralis muscle is removed at its insertion on the humerus. The insertion of the supracoracoideus muscle on the dorsomedial aspect of the coracoid must be avoided. A two- to three-cm section of the tensor propatagialis is removed. **d)** Anatomy of the head of the proximal humerus including a cross section showing the relationship of the superficial pectoralis and supracoracoideus muscles to the pectoral crest. 3) sternum 4) clavicle 5) supracoracoideus muscle 6) head of the humerus 7) dorsal tubercle 8) pectoral crest 9) coracoid 10) scapula 11) attachment of supracoracoideus muscle 12) triosseal canal 13) ventral tubercle and 14) insertion of the superficial pectoralis muscle.

## Castration and Caponizing

Ganders may become very aggressive during the breeding season. As an alternative to removing an aggressive bird, some clients will choose to have the animal castrated to prevent inter-male fighting, reduce aggression toward people and prevent additional offspring. The procedure is performed on an anesthetized bird placed in lateral recumbency. The wings are extended and taped above the body. Geese are very muscular, so full caudal extension of the up leg is necessary to expose the surgery site. The area of the last two ribs cranial to the femur is plucked and prepped for surgery.

The lungs extend almost to the last intercostal space, so care is necessary when making a one-half-inch vertical incision between the last two ribs. Retractors are necessary to keep the ribs separated. Blunt dissection through the air sac reveals the testicle. Two curved hemostats are clamped between the testicle and body wall and left in place for two minutes. The outer hemostat is then pulled up and away from the other hemostat, tearing the testicle free. Minimal

bleeding can be expected. Alternatively, two hemostatic clips may be applied between the testicle and the body wall, taking care not to occlude the aorta or vena cava. The ribs are closed in a simple interrupted pattern with an absorbable suture material. The skin is then closed. The opposite testicle is removed in a similar manner. Several affected birds have been reported to maintain their original personality, but their bellicose nature associated with previous breeding seasons did not develop.<sup>83</sup> This procedure can be most safely performed in young birds.

### Products Mentioned in Text

- Chemistry assays from Gilford Impact 400 Autoanalyzer, Ciba Corning Diagnostics, Oberlin, OH
- Nomad Mat #262105, 3-M, distributed by Zellerbach (USA); EnKamat #7210106, Flatback Erosion Control Systems, Tuscaloosa, AL
- Valentine, Hinsdale, IL 323-7070.
- Emeraid I, Lafeber, Odell, IL
- Nichols Net & Twine Company, Inc., Granite City, IL
- Lang's Jet Acrylics, Lang Dental Manufacturing Company, Chicago, IL

## References and Suggested Reading

- Boever WJ, Wright W: Use of ketamine for restraint in anesthesia of birds. *Vet Med Sm Anim Clin* 70:86-88, 1975.
- Borzio F: Ketamine hydrochloride as an anesthetic for wildfowl. *Vet Med Sm Anim Clin*: 1364-1367, Dec 1973.
- Brown AF: *The Incubation Book*. Surrey, England, Spur Publications, 1979.
- Brownell JR, Sadler WW: An evaluation of selected anesthetics and surgical anesthetics for chickens. *Avian Dis* 13(7):1967.
- Clark WC: *Echinuria australis* n.sp. and *E. uncinata* (Nematoda: Spirurida) parasites of ducks in New Zealand. *NZ J Zool* 6:7, 1979.
- Cline DR, Greenwood RJ: Effect of certain anesthetic agents on mallard ducks. *J Am Vet Med Assoc* 161(6):624-633, 1972.
- Clipsham R: Surgical beak restoration and correction. *Proc Assoc Avian Vet*, 1989, pp 164-176.
- Coles BH: *Avian Medicine and Surgery*. Boston, Blackwell Scientific Publications, 1985.
- Costango GR: Sarcocystis in American black ducks wintering in New Jersey. *J Wildl Dis* 26(3):387-389, 1990.
- Cridler ED, McDaniel JC: Oral drugs used to capture waterfowl. *Proc SE Assoc Game & Fish Comm* 22:1-18, 1968.
- Dardiri AH: Duck viral enteritis (duck plague) characteristics and immune response of the host. *Am J Vet Res* 36(4):535-538, 1975.
- Davies R, Wilkialis J: A preliminary investigation on the effects of parasitism of domestic ducklings by *Theromyzon rude*. *Can J Zool* 59:1196, 1981.
- Davis JW, et al: *Infectious and Parasitic Disease of Wild Birds*. Ames, Iowa State University Press, 1978.
- Dean WF, Price JJ, Leibovitz L: Effects of medicaments on bacterial infections on ducklings. *Poult Sci* 53(2):549-558, 1973.
- Degernes LA, et al: Lead poisoning in trumpeter swans. *Proc Assoc Avian Vet*, 1989, pp 144-155.
- Dein, FJ, Frank LS: Rehabilitation of oil-contaminated birds. *In* Kirk, RW (ed): *Current Veterinary Therapy IX*. Philadelphia, WB Saunders Co, 1986, pp 719-723.
- Dein FJ: *Laboratory Manual of Avian Hematology*. New York, Association of Avian Veterinarians, 1984.
- DiBarotola SP, Benson MD: The Pathogenesis of Reactive Septemic Amyloidosis. *J Vet Intl Med* 3:31-41, 1989.
- Dieterich RA: *Alaskan Wildlife Diseases*. Fairbanks, Institute of Arctic Biology, 1981.
- Dalensek EP, et al: Hatching problems in exotic birds. *Proc Am Assoc Zoo Vet*, 1979, pp 63-64.
- Elliot JM, Talbett, DA: Leech parasitism of waterfowl. *Wildfowl* 33:164, 1982.
- Fairbrother A, O'Loughlin D: Differential white blood cell values of the mallard (*Anas platyrhynchos*) across different ages and reproductive states. *J Wildl Dis* 26(1):78-82, 1990.
- Fairbrother A: Changes in mallard (*Anas platyrhynchos*) serum chemistry due to age, sex, and reproductive condition. *J Wildl Dis* 26(1):67-77, 1990.
- Farrell DJ: Energy expenditure of laying ducks; Confined and herded. *In* *Duck Production Science and World Practice* (D.J. Farrell and Stapleton, Eds.) University of New England, Armidale, NSW, Australia 1985.
- Fisher HI: *Auk* 75:391-399, October 1958.
- Fite RW: Diagnosis and control of leukocytosis in captive waterfowl. *Proc Assoc Avian Vet*, 1984, pp 193-198.
- Franson JC: Enzyme activities on plasma, liver and kidneys of black ducks and mallards. *J Wildl Dis* 18:481, 1982.
- Friend M: *General Field Procedures and Diseases of Migratory Birds*, Vol 1. Fieldguide to wildlife diseases, Washington DC, US Department of the Interior Fish & Wildlife Service, 1987.
- Fritz JC, Archer W, Barker D: Vitamin D requirements of ducklings. *Poult Sci* 20(15):1-154, 1941.
- Frye FL: Prosthesis enhance quality of life. *Veterinary Medicine* July:931-935, 1984.
- Gassman-Duval R: An acute *Cyathostoma bronchialis* outbreak in the Hawaiian goose and other parasites found. *Proc First Intl Conf Zool & Avian Med*, 1987, pp 61-68.
- Gee CG, Carpenter JW, Hensler GL: Species differences in hematological values of captive cranes, geese, raptors and quails. *J Wildl Mgt* 45:463, 1981.
- Gee GF, Sexton TJ: Cyogenic preservation of semen from the Aleutian Canada goose (*Branta canadensis leucopereid*) *Zoo Biol* 9(5):361-372, 1990.
- Gieffer G et al: On the occurrence of leeches (Hirudinea) in waterfowl. *Proc Intl Symp Erkrankungen der Zoo- und Wildtiere*, Sofia Bulgaria, 1988, pp 333-335.
- Goelz MF, Hahn AW, Kelley ST: Effects of halothane and isoflurane on mean arterial blood pressure, heart rate, and respiratory rate in adult Pekin ducks. *Am J Vet Res* 51(3) March, 1990.
- Gordon B: The use of sodium amobarbital for waterfowl capture. *J Zoo Am Med* 8:34-35, 1977.
- Gryzimek's *Animal Life Encyclopedia*. Anseriformes: screamers, ducks and geese, chapter 11. New York, Nostrand Reinhold, 1972, p 253.
- Haigh JC: Levamisole in waterfowl: Trials on effect and toxicity. *J Zoo Anim Med* 10:103-105, 1979.
- Harrison CJO (Consult ed): *Birds, Their Life, Their Ways, Their World*. USA, The Readers Digest Association, Inc, 1979, pp 206-211.
- Harvey-Clark C: Clinical and research use of implantable oscular access ports in avian species. *Proc Assoc Avian Vet*, 1990, pp 191-209.
- Hayes MB (ed): *Rehabilitation Guidebook for Birds and Mammals*. Brunker Nature Center, Ohio, 1984.
- Heard DJ: Overview of avian anesthesia. *Assoc Avian Vet Today* 2(2):92-96, 1988.
- Holm ER, Scott ML: Studies on the Nutrition of Wild Waterfowl. NY Fish & Game J 1:171-187, 1954.
- Humpreys PN: Introduction and identification, restraint and handling, parasitic diseases. *In* Fowler ME (ed): *Zoo and Wild Animal Medicine 2nd ed*. Philadelphia, WB Saunders Co, 1986, pp 334-335, 341-342, 353-357.
- Hyde DO: *Raising Wild Ducks in Captivity*. New York, EP Dalton and Company, 1974.
- Jager FC: Effect of dietary linoleic acid and selenium on the requirement of vitamin E in ducklings. *Nutri and Metab* 14:210-227, 1972.
- Jager FC: Linoleic acid intake and vitamin E requirements in rats and ducklings. *Ann NY Acad Sci* 203:199-211, 1972.
- Jenkins JR: Aspergillosis. *Proc Assoc Avian Vet*, 1991, pp 328-330.
- Jensen WI: Perosis in Canada geese (*Branta canadensis*). *Wildl Dis Assoc* 4:95-99, 1968.
- Jessup DA: Infectious diseases, avian cholera, botulism. *In* Fowler ME (ed): *Zoo and Wild Animal Medicine 2nd ed*. Philadelphia, WB Saunders Co, 1986, pp 342-352.



## CHAPTER 46 ANSERIFORMES

51. **Johnsgard PA:** Ducks, Geese, and Swans of the World. Univ of Nebraska Press, 1978, pp xvii-xxiii.
52. **Johnsgard PA:** Waterfowl: Their Biologies and Natural History. Lincoln University of Nebraska Press, 1968.
53. **Jordan R:** Parrot Incubation Procedures. Ontario, Canada, Silvio Mattacchione & Company, 1989.
54. **Kaufman E, Pokras M, Sedgwick C:** Anesthesia in waterfowl. *Assoc Avian Vet Today* 2(2):98, 1988.
55. **Kawashiro T, Sheid P:** Arterial blood bases in undisturbed resting birds: Measurements in chicken and duck. *Respir Physiol* 337-342, 1975.
56. **Kear J:** Feeding and nutrition. *In* Fowler ME (ed): *Zoo and Wild Animal Medicine* 2nd ed. Philadelphia, WB Saunders Co, 1986, pp 335-341.
57. **Kear J:** Notes on the nutrition of young waterfowl, with special reference to slipped wing in Duplaix-Hall N (ed): *Intl Zoo Yearbook*, Vol 13, London, The Zoological Society of London, 1973, pp 97-100.
58. **Kenny D, Cambre, RC:** Indications and techniques for the surgical removal of the avian yolk sac. *J Zoo Wildl Med* 23(1):55-61, 1992.
59. **Klea JA:** Artificial incubation: Problems and solutions. *Proc Jean Delacour/IFCB Symposium on Breeding Birds in Captivity*, 1983, pp 223-238.
60. **Klein PN:** The challenge of toxicological investigation in birds. *Proc Assoc Avian Vet*, 1989, pp 139-143.
61. **Kocan RM, Pitts SM:** Blood valves of the canvasback duck by age, sex and season. *J Wildl Dis* 12:341, 1976.
62. **Kocan RM:** Some physiologic blood values of wild diving ducks. *J Wildl Dis* 8:115, 1972.
63. **Kock RA et al:** Acuariasis in waterfowl at Whippsnade Zoo. *Proc Intl Symp Erkrankungen der Zootiere*, Cardiff, 1987, pp 65-73.
64. **Langenberg J, Montali RJ:** Avian neonatal pathology. *Proc Am Assoc Zoo Vet*, 1983, pp 172-175.
65. **Lauer DM, Frank J, Dein FJ:** Rehabilitation of ruddy ducks contaminated with oil. *J Am Vet Med Assoc* 181(11):1398-1399, 1982.
66. **Lewandowski AH, Sikarskie JG:** Pinioning: a quick and simple technique. *Proc 1st Intl Conf Zool & Avian Med*, 1987, pp 414-415.
67. **Ludders JW et al:** Effects of ketamine, xylazine, and a combination of ketamine and xylazine in Pekin ducks. *Am J Vet Res* 50(2):245-249, 1989.
68. **Mangili G:** Unilateral patagiotomy: A new method of preventing flight in captive birds. *Intl Zoo Year Book*, London Zool Soc 11:252-254, 1971.
69. **Mauvino M:** Avian lead intoxication. *Proc Assoc Avian Vet*, 1990, pp 245-247.
70. **McLelland J:** A Color Atlas of Avian Anatomy. Philadelphia, WB Saunders Co, 1991.
71. **Miller JC:** The importance of immobilizing wing after tenectomy and tenotomy. *Vet Med Sm Anim Clin* 68:35, 1973.
72. **Miller RE, et al:** *Leucocytozoon simondi* infection in European and American eiders. *J Am Vet Med Assoc* 183(11):1241-1244, 1983.
73. **Montali RJ:** Comparisons of diseases of waterfowl in captive and free-living species. *Sonderdruck aus Verhandlungsbericht des 29. Internationalen Symposiums über die Erkrankungen der Zootiere*. Cardiff, 1987, pp 7-12.
74. **Montali RJ:** Disease of waterfowl: Comparisons in captive and free-living species. *Proc Am Assoc Zoo Vet*, 1989, pp 2-6.
75. **Mori JG, George JC:** Seasonal changes in serum levels of certain metabolites, uric acid and calcium in the migratory Canada goose (*Branta canadensis interior*). *Comp Biochem Physiol* 59B:263, 1978.
76. **Morishita TY:** Establishing a differential diagnosis for backyard poultry flocks. *Proc Assoc Avian Vet*, 1990, pp 136-146.
77. **Motzok I, Branion HD:** The vitamin D requirements of growing ducks. *Poult Sci* 27:482-485, 1948.
78. **Mulley RC:** Haematology of the wood duck *Chenonetta jubata*. *J Wildl Dis* 16:271, 1980.
79. **Mulley RC:** Haematology and blood chemistry of the black duck *Anas superciliosa*. *J Wildl Dis* 15:437, 1979.
80. **Napolitano RL, Dolensek EP, Russo EA:** Serodiagnosis of aspergillosis in avian species. *Proc Am Assoc Zoo Vet*, 1978, pp 265-267.
81. **Olsen JH:** Management and disorders of young waterfowl. *The Role of Veterinary Medicine in Aviculture*, AFA Veterinary Seminar, Orlando, 1984, pp 36-49.
82. **Peek JM:** Chlordiazepoxide and pentobarbital as tranquilizers for cow birds and coturnix quail. *J Am Vet Med Assoc* 149:950-952, 1966.
83. **Phalen DN:** Castrating the gander. *Assoc Avian Vet Today* 1(4):173-174, 1987.
84. **Pokras MA, Blackman R:** Understanding the syringeal bulla. *Assoc Avian Vet Today* 2(3):134-135, 1988.
85. **Redig P:** An overview of avian anesthesia. *Proc Assoc Avian Vet*, 1982, pp 127-139.
86. **Redig, PT:** Treatment of bumblefoot and the management of aspergillosis and various other problems commonly seen in raptors. *Proc 1st Intl Conf Zool & Avian Med*, 1987, pp 309-321.
87. **Rigdon RH:** Tumors in the duck (Family Anatidae): A review. *J Natl Cancer Trust File* 49(2):467-476, 1972.
88. **Robinson PT, Buzikowski RB:** Pinioning young birds with hemostatic clips. *Vet Med Sm Anim Clin* 70:1415-1417, 1975.
89. **Robinson PT:** Unilateral patagiotomy: A technique for deflighting large birds. *Vet Med Sm Anim Clin* 70:143-145, 1975.
90. **Rode JA, Bartholow S, Ludders JW:** Ventilation through air sac cannula during tracheal obstruction in ducks. *J Assoc Avian Vet* 4(2):98-102, 1990.
91. **Rowley J, Brown RD, White SE:** Bumblefoot in raptors. *Avian/Exotic Prac* 2(1):5-7, 1985.
92. **Sandhu T:** Duck virus hepatitis, goose virus hepatitis, *Pasteurella anatipestifer* infection. *In* Fowler ME (ed): *Zoo and Wild Animal Medicine* 2nd ed. Philadelphia, WB Saunders Co, 1986, pp 346-349.
93. **Sandu TS:** Important diseases of ducks. *In* Farrell DJ, Stapleton P (ed): *Duck Production Science and World Practice*. Univ New England, pp 111-134.
94. **Schroder CR, Koch K:** Preventing flight in birds by tenotomy. *J Am Vet Med Assoc* 97:169-170, 1940.
95. **Schwartz LH:** Poultry surgery. *In* Hofstad M, et al (eds): *Diseases of Poultry* 5th ed. Ames, The Iowa State University Press, 1965, pp 1149-1161.
96. **Scientific Report of the Zoological Society of London.** *Journal of Zoology*: 306-307, 1975-1977.
97. **Scott ML, Dean WF:** Nutrition and Management of Ducks. Ithaca, ML Scott of Ithaca, 1991.
98. **Scott ML:** Nutrition of Humans and Selected Animal Species. Somerset NJ, John Wiley & Sons, 1986.
99. **Shave H:** Clinical pathology. *In* Fowler ME (ed): *Zoo and Wild Animal Medicine* 2nd ed. Philadelphia, WB Saunders Co, 1986, pp 357-362.
100. **Shave HJ, Howard V:** A hematologic survey of captive waterfowl. *J Wildl Dis* 12:195, 1976.
101. **Soifer FK:** Anthelmintics for exotic & zoo animals. *Proc Am Assoc Zoo Vet*, 1970, pp 123-124.
102. **Soothill E, Whitehead P:** *Wildfowl of the World*. London, Blandford Press, 1988.
103. **Speckmann G:** Necropsy findings in various avian species other than domestic chickens and turkeys. *J Zoo Anim Med* 7(4):27-30, 1976.
104. **Stefanatos J:** A new treatment for bumblefoot in birds. *J Zoo Anim Med* 5(2):25, 1974.
105. **Steiner MC, Starkhouse L:** Parasitic ulcerative ventriculitis in mallards (*Anas platyrhynchos*). *J Wildl Dis* 23(4):680-682, 1987.
106. **Szep I, Pataky M, Nagy G:** Infectious Inflammatory Disease of Cloaca and Penis in Geese (Goose Gonorrhoea). I. Epizootiological, Clinical, Pathological Observations & Control. *Acta Vet Acad SEI HUNG*, 1974..
107. **Tarsnane S:** *Waterfowl: A Guide to Management and Propagation*. Tarsnane Productions, Montana, 1985.
108. **Todd FS:** *Waterfowl: Ducks, Geese and Swans of the World*. Sea World Press, San Diego, 1979.
109. **USDA Agriculture Handbook** No. 8-1 1976. *Dairy and Egg Products*; No. 8-5, 1979 *Poultry Products*. U.S. Government Printing Office, Washington, DC.
110. **Valverde A, Honeyman VL, Dyson DH, Valliant AE:** Determination of a sedative dose in influence of midazolam on cardiopulmonary function in Canada geese. *Am J Vet Res* 51(7):1071-1074, 1990.
111. **Wallach JD, Boever WJ:** Gamebirds, waterfowl, and ratites. *In* *Diseases of Exotic Animals: Medical and Surgical Management*, Philadelphia, WB Saunders Co, 1983, pp 831-888.
112. **Wilgas HS:** Reserpine for tranquilizing geese. *Second Conf Use of Reserpine in Poultry Production*. The Institute of Agriculture, St. Paul, MN, 1960, p 54-56.
113. **Williams JJ, Traines DO:** A hematological study of snow, blue and Canada geese. *J Wildl Dis* 7:258, 1971.
114. **Williamson WM, Russell WC:** Prevention of flight in older captive birds. *J Am Vet Med Assoc* 159(5):596-598, 1971.
115. **Wilson RB, New JC, Scholtens RG:** Granulomatous encephalitis caused by schistosomiasis in swans. *J Am Vet Med Assoc* 181(11):1386-1387, 1982.
116. **Wobeser GA:** *Diseases of Wild Waterfowl*, New York, 1981.
117. **Wolf L:** Prosthetic bill technique in a Canada goose. *Proc Assoc Avian Vet*, 1985, pp 177-179.
118. **Wolfe DA:** Surgical correction of paresis in a 3-week-old mallard duck. *Vet Med Sm Anim Clin* :1567-1570, 1978.
119. **Yanoff SR:** Egg yolk peritonitis in a duck. *Proc Am Assoc Zoo Vet*, 1983, pp 214-215.
120. **Yearout DR:** Prevention and treatment of aspergillosis by vaccination: A new protocol. *Proc Assoc Avian Vet*, 1988, pp 139-144.
121. **Zdzarski JM, et al:** Zinc toxicity in downy ducks. *J Zoo Anim Med*, in press.