

CHAPTER

43

PASSERIFORMES

Patricia Macwhirter

**P**asseriformes (perching and songbirds) is the largest order of birds. It contains nearly 60 percent of all bird species ranging in size from the tiny Weebill (80 mm in length) to the Superb Lyrebird (130 cm long, including a 72 cm tail). Canaries, finches, starlings and mynahs are examples of passerine birds that are common in captivity. Passerines are widely distributed throughout the world, and all passerines share a common anisodactyl foot structure with three unwebbed toes pointed cranially and one caudally. The altricial young are usually naked when hatched and are reared in a nest.

The order is believed to have originated in Gondwana, the ancient southern continent. Convergent evolution makes differentiating species based on morphologic grounds difficult, and in the past, the anatomy of the syrinx has been a primary means of classification. Recent DNA hybridization and protein electrophoresis studies are modifying traditional views. One group of passerines is now believed to have evolved and radiated in eastern Gondwana, proto-Australasia (these include such species as bowerbirds, lyrebirds, birds of paradise, honeyeaters, Australian grass finches and fairy wrens). Another group, the suboscines or primitive songbirds are believed to be of western Gondwanan origin (current-day South America). These include such primitive South American species as contingas, manikins, antbirds and gnateaters. More advanced songbirds like Fringillidae finches, sparrows, warblers, starlings, thrushes and sunbirds may also have evolved via western Gondwana and migrated from this area to become widely distributed.<sup>10</sup>

While Passeriformes are widespread in the northern hemisphere, there are very few endemic families and many of the species are migratory.<sup>56</sup>

## Anatomy and Physiology

Passeriformes have become adapted to a wide variety of ecological niches. The anatomic and physiologic differences expressed within the order reflect these specific evolutionary patterns (Table 43.1).

### Digestive System

The basal metabolic rate (BMR) of passerine birds is generally about 65% greater than that of non-passerines, and their body temperature is about two degrees Centigrade higher (around 42°C). While some desert passerines such as the Zebra Finch have been known to survive months without drinking water, most small passerine birds drink from 250 to 300 ml/kg body weight of water each day and may eat up to 30% of their body weight daily. These figures are higher than those for most non-passerines, which tend to be larger birds.

Most passerine species have a narrow, triangular tongue compared with the thick blunt tongue of parrots. The tongue is rarely involved in clinical problems. The tongue of passerines may become hyperkeratotic at the tip and extend rostrally through the beak. The syndrome appears to cause few clinical problems, but the hyperkeratotic tissue can be slowly trimmed back with a pair of strabismus scissors, taking care not to cut healthy mucosa. Other parts of the digestive tract differ depending on the species' feeding patterns. A ventriculus is present in granivorous and insectivorous species such as finches, but not in species such as honeyeaters that consume nectar and soft foods. If present, cecae are generally small and vestigial.

Inexperienced Passeriformes breeders may present chicks for evaluation of a "sore" or "swelling" on the neck. This clinical sign is usually determined to be the crop distended with seeds and visible beneath thin, featherless skin.

There is no production of crop milk in passerines as there is in pigeons, but some finches will regurgitate crop contents to feed their young. Pathogens can be transmitted from parent to offspring during this process, particularly with foster-raised chicks that probably did not receive yolk-derived antibodies against microorganisms from their foster parents'

digestive system. For example, although *Cochlosoma* sp. may cause inapparent infections in adult Bengalese (Society) Finches, significant mortality may occur in juvenile Gouldian Finches being fostered by Bengalese parents.<sup>15</sup>

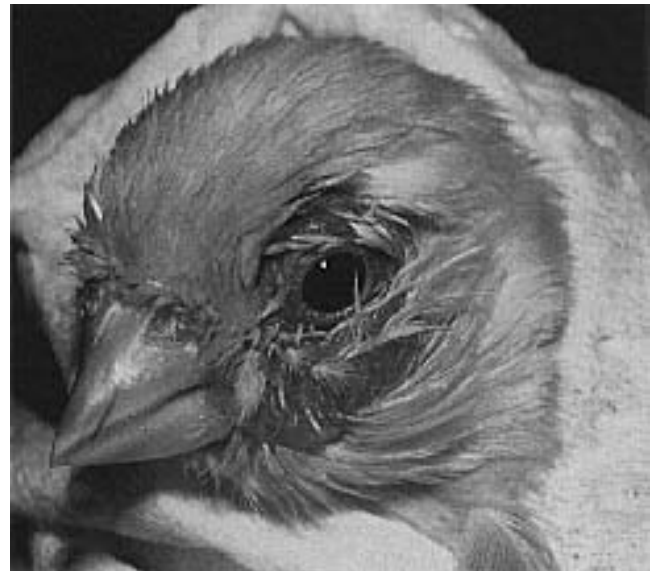Nestling Estrilid finches (eg, Gouldian and Zebra Finches) normally have characteristic luminous mouth markings. Mucosal patterns are species-specific and help to guide parents to their own chicks within the recesses of dark nests.

The spleen in most passerines is oblong, not spherical, as it is in Psittaciformes.

### Respiratory System

In most Passeriformes, unlike in Psittaciformes, the right and left nasal sinuses do not communicate. In passerine birds, separate samples for rhinal disease (bacterial, viral, chlamydial) cytology examination should be taken from each sinus if a bilateral nasal discharge occurs (Figure 43.1).<sup>9</sup>

Singing ability is highly developed in many passerine species and is related to the complexity of the syringeal anatomy. Some species have the capacity to sing duets with themselves by alternately using op-



**FIG 43.1** Passeriformes, like this canary, have right and left paranasal sinuses that do not communicate as they do in Psittaciformes. If bilateral oculonasal discharge suggestive of sinusitis is occurring, it is wise to collect samples from both the right and left sinuses for culture and cytologic evaluation. Conjunctivitis in this canary was responsive to tylosin therapy (courtesy of Michael Murray).

TABLE 43.1 Distinguishing Features of Selected Passerine Birds

Family	General Composition	Approx. Number of Species	Characteristics
Emberizidae	New World finches, cardinals, buntings, Cuban finch	550	Cup-shaped open nest, female incubates, diverse group, 9 primary feathers
Estrildidae	African, Asian and Australian finches, waxbills, nunias, parrot finches	125	Palatal markings in young, monogamous, dome-shaped nest with side entrance, 10 primary feathers
Fringillidae	True finches, canaries, goldfinch, chaffinch	125	Cup-shaped open nest, female incubates, 9 primary feathers, 12 long tail feathers
Passeridae	Sparrows, finches	32	Bulky domed nest of dried grass, breed in colonies, seed-eating, finch-like birds
Ploceidae	Weavers, whydahs, queleas	145	Dome-shaped, covered, woven nest, do not sing, some species parasitic
Sturnidae	Starlings, mynahs	108	Dark, iridescent, or brightly colored, colonial, nest in holes, long straight bills, mimicry ability



FIG 43.2 A hand-raised European starling can develop an extensive vocabulary and have a voice quality that is similar to its relative, the mynah bird (courtesy of Mark Spreyer).

posite bronchi. Roller canaries are specifically bred and trained for their singing ability.

The ability to mimic the human voice is well developed in some passerines, notably mynahs, starlings and corvids (Figure 43.2). Among Australian passerines, lyrebirds are legendary in their ability to mimic the calls of other bird species, and rain forest gullies will re-echo with an apparent chorus of calls that can

be traced to a single individual bird. The American mockingbird has similar abilities and may mimic the sounds of companion Psittaciformes.

Like psittacine birds but unlike ratites and penguins, passerine birds have a highly developed neopulmonic and paleopulmonic parabronchi. This allows for highly efficient oxygen exchange. In most passerines, the cranial thoracic air sacs are fused to the single median clavicular sac, making a total of seven air sacs as opposed to the nine air sacs of psittacine species.

Reproductive System

In general, only the left ovary and oviduct develop in normal female passerines. Occasionally a nonfunctional right ovary will develop in female sparrows. Both testicles develop in males and during the breeding season these may reach enormous proportions in relation to the size of the bird. These physiologically enlarged testicles should not be mistaken for pathologic conditions.

**Role of Light in Reproduction**  
Temperate-evolved species (including canaries) are usually dependent on daylight intervals for reproductive performance. Increased daylight hours trigger the release of luteinizing hormone (LH) in responsive individuals. The precise light interval varies among species but the physiologic control mechanism appears to be similar. Light stimulates photoreceptors in the brain, probably in the hypothalamus, where there is a circadian rhythm of photosensitivity. If

light coincides with the period of sensitivity, luteinizing hormone releasing factor (LHRF) is released and gonadotrophin secretion is increased. If light coincides with the insensitive phase of the rhythm there is no response. Gonadotrophin release in turn, triggers the release of sex hormones.

There must be a rest period following a long light exposure to allow the photoreceptive system to reac-

tivate and once again be responsive to increasing day length. Stimulation of the reproductive cycle is best accomplished by a progressive increase (four-week period) of exposure to light. In general, the maximum effect of increasing day length will occur when a passerine individual is exposed to 10-14 hours of light. In males, the release of testosterone may occur in less than 24 hours following exposure to appropriately increased daylight hours. This in turn can result in rapid development of secondary sexual characteristics and breeding display (territorial calling, testicular and cloacal enlargement, courtship behavior).

Courtship behavior is the culmination phase of the reproductive cycle. Response of females to increased photoperiod is less dramatic, and it may require the presence of a male in breeding condition to trigger appropriate nesting and egg laying responses.<sup>60</sup> By gradually increasing the light exposure, a more natural reproductive cycling occurs, and a male is less likely to brutalize a slowly responsive hen. This also accounts for the common aviculture practice of separating males and females during the non-breeding season.

Many aviculturists use a “breeder” cage with a removable partition that allows the male to feed the female through an opening. At various intervals, the partition separating the two sexes is removed, and if the female “accepts” the male, they are left together. The nest is put in the male’s side of the cage along with a source of nest material, which he collects in the nest as part of the courtship activity. An experienced canary breeder can remove the partition at precisely the right time for the female to accept the male.

This photoresponsive mechanism is very sensitive, and some species of birds indigenous to high latitudes commence breeding at almost the same week from one year to the next. The fact that many Psittaciformes hens produce eggs within a one- to two-day period on an annual basis suggests a similar, well defined control system of the reproductive cycle. This is obviously an advantage where suitable conditions for raising chicks are restricted to a very limited season. In indoor breeding aviaries, it is important to mimic appropriate daylight patterns in order to stimulate breeding. Appropriate daylight-hour patterns will vary from species to species. In canaries, 14 hours of light is commonly recommended to induce reproductive behavior in a responsive bird. Longer light periods may cause a shorter breeding period

and early molting. Molting causes an immediate cessation of breeding activity.

After a period of long daylight hours, birds become refractory to photostimulation, and plasma concentrations of both LH and FSH begin to fall. In male White-crowned Sparrows, for example, this occurs after 50 days of long daylight hour exposure. Following the molt and period of decreasing daylight hours (fall), the breeding season starts again with the increasing daylight hours in the late winter and early spring. Following the molt and several months of reconditioning, the process starts over (in the United States, this occurs in December with January breeding).

### Testosterone-induced Singing

Male canaries will usually sing best in the spring in response to the endogenous testosterone “surge.” If a bird becomes ill, it may stop singing and may not recommence vocalizations until the following spring, even though the initial illness has resolved. In contrast, some canaries (even some females) sing year round and birds that stop singing because of illness re-commence singing as soon as their general condition improves. Injectable testosterone has been suggested as a method of inducing singing in birds that have stopped after a period of illness. This is a practice that should be discouraged because the testosterone has a negative feedback that causes shrinking of the testes and reduced fertility.

## Avicultural Considerations

### Husbandry

Dietary and husbandry requirements for passerines are diverse. There are primarily seed-eating species such as the canary and Bengalese Finches that have been domesticated for centuries, are easy to care for and breed well in captivity. Many varieties of these domesticated species bear little resemblance to their free-ranging ancestors. Java Finches, Zebra Finches and Gouldian Finches have somewhat shorter histories of domestication but are also bred intensively in captivity, and many mutations have occurred.

Many Passeriformes are critically endangered because of habitat destruction and human interference. By developing a better understanding of these spe-

TABLE 43.2 Breeding Characteristics of Selected Passerine Birds

	Eggs Per Clutch	Incubation (days)	Fledging
Australian Grass Finches	4-8	12-17	21-25
Birds of paradise	1-2	17-21	17-30
Bowerbirds	1-2	19-24	18-21
Bulbuls	2-5	12-14	14-18
Canaries and Frigillid finches	3-5	12-14	11-17
Cardinals	2-5	11-14	9-15
Crows and jays	2-8	16-22	20-45
Java Finch	4-8	14-14	26-28
Sparrows and weavers	2-5	13-14	21-24
Starlings and mynahs	2-7	11-18	18-30

cies and pressuring local, national and international leaders to preserve all remaining natural habitat, the aviculturist and avian veterinarian can have a dramatic impact on the health of the planet.

Table 43.2 lists the breeding characteristics of selected passerine species.

Housing

Aviaries for Passeriformes should provide adequate protection from the elements, with tropical species requiring the greatest degree of protection. In mild climates, hardy species of Passeriformes do well in carefully planned, planted aviaries that provide adequate protection as well as visually attractive sur-

roundings (Figure 43.3). Indoor, temperature-controlled rooms may be necessary to raise finches in harsher climates or when artificial lighting control is necessary to increase production.

Planted aviaries are popular for passerines because these birds cause less damage to vegetation than psittacines and the vegetation provides observers a more natural view of a bird's behavior. Care must be taken to ensure that the plant species are nontoxic.

Some passerine birds require special materials for nesting or to stimulate display behavior. Care must be taken that the type of objects provided for these birds are safe. Any contact with fine synthetic fibers should be avoided because these may become entangled around the birds' feet, toes or other body areas and cause damage, loss of limb or death. Burlap (hessian) cut into small squares, torn strips of facial tissue or coconut fiber make suitable, safe nesting materials (Figure 43.4) (see Color 24).

Male Satin Bowerbirds will build intricate display nests that they decorate with blue objects if suitable materials are provided. At one time in Australia, blue plastic rings were used to seal milk bottle tops, and free-ranging bowerbirds would selectively collect these rings from rubbish dumps and elsewhere to decorate their bowers. The rings would occasionally slip over the bowerbird's neck with fatal results. Manufacturers changed the color of the rings from blue to white or red, ending the strangulation deaths.

Disease Control

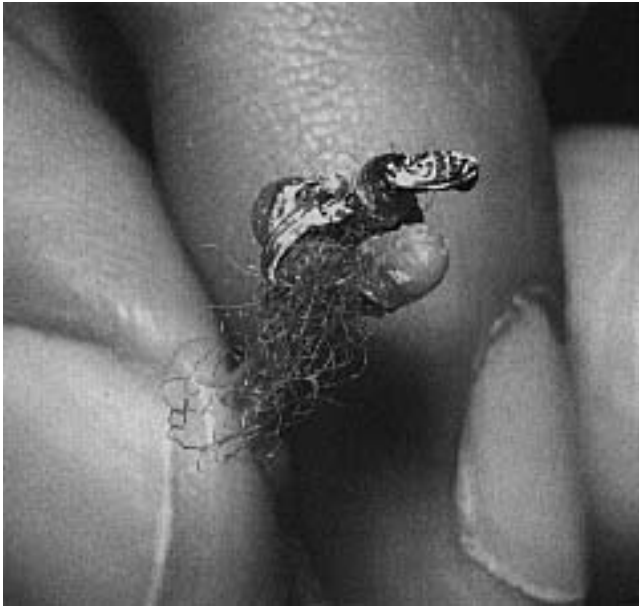Disease control in planted aviaries can be challenging because of the difficulties involved in controlling microorganisms and in medicating individual birds. Because it is difficult to eliminate infectious agents once they are introduced into a planted aviary, it is critical that any new birds be quarantined, tested and treated for parasites and infectious diseases prior to introduction.

Free-ranging birds should be excluded from aviaries to prevent the transmission of microorganisms. Sparrows, for example, may transmit poxvirus, *Plasmodium*, feather lice, mites and *Haemoproteus* to canaries.




FIG 43.3 Depending on the climatic conditions and the durability of the species, many Passeriformes can be maintained in attractive, planted outdoor aviaries.



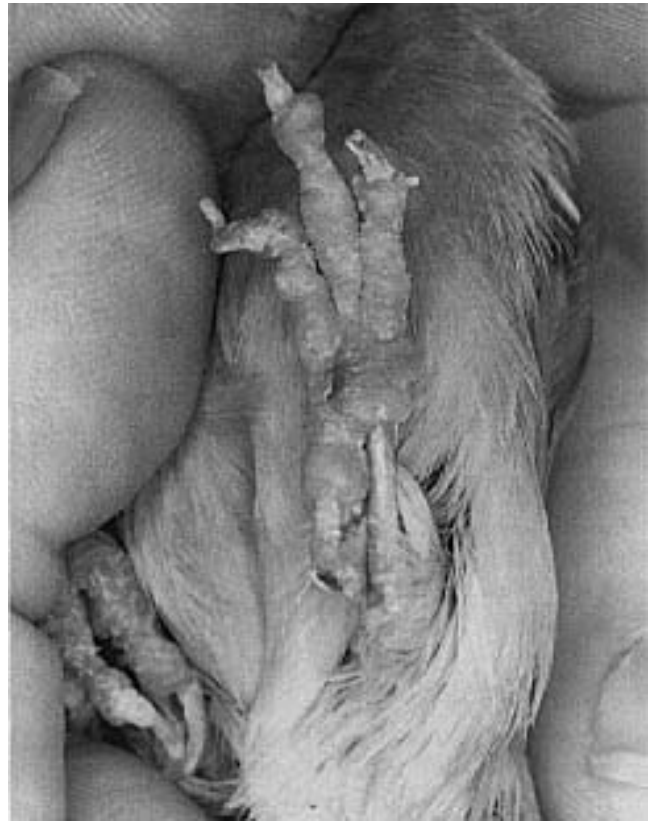


**FIG 43.4** Only natural substitutes (burlap, coconut fiber) should be used for nesting material in Passeriformes. Synthetic fibers (particularly yarn) may wrap around a digit, leg or wing causing avascular necrosis distal to the constriction. In some cases, the fibers are grossly visible, while in others, magnification is necessary to see and remove the constricting fibers. A 26 or 30 ga needle makes an excellent cutting tool for removing small fibers under magnification (courtesy of Michael Murray).

### Nutrition

Passeriformes may be granivorous, nectivorous, frugivorous, insectivorous, omnivorous or carnivorous. Some species adapt readily to commercially available diets, while others may require live food and are thus difficult to maintain in captivity. Some free-ranging species have specific dietary preferences (Gouldian Finches prefer sorghum) but may adapt to diets provided in captivity. Even finches that are considered omnivorous or carnivorous can be successfully raised on properly balanced vegetable-based diets (Figure 43.5).

Recommended dietary levels of vitamins and minerals developed for poultry are used as a base in small passerines. Finches may consume up to 30% of their body weight daily in food compared with 10% for larger parrots. If dietary supplementation is based on a percentage of particular ingredients in the diet, finches may be consuming greater amounts on a per gram body weight basis than larger species. Overdosage of vitamins and minerals may occur, resulting in infertility, renal calcification, gout and general poor condition; thus, only diets specifically formulated for finches should be used.



**FIG 43.5** A mature canary was presented with a four-month history of progressive lameness. The bird was maintained on an all-seed diet in a small enclosure and had no exposure to water for bathing or sunlight. Note the generalized edema, hyperkeratosis, dry brittle nails and poor feather quality suggestive of chronic malnutrition.

Feather color is dietary-dependent in species with carotenoid pigmentation. Red factor and new color canaries have genotypes that require exogenous sources of carotenoids or related compounds to enable full development of yellow, orange and red pigments in feathers. Foods for these birds contain carotenoids and xanthophylls to enable proper color development. Reduced or absent carotenoids during feather formation produces pale or whitish feathers while excess carotenoids will cause a deepening of yellow and red pigments.<sup>8</sup> Commercial diets that contain algae (spirulina) should have sufficient levels of naturally occurring carotenoids to maintain proper feather coloration. In the United States, “colored” foods generally contain carotene-soaked stale bakery products and should be avoided in favor of more natural sources of carotenoids.

Free-ranging Green Finches may be bronze or reddish if they are exposed to excessive carotenoids. Their natural color will return when they are placed

on a more natural diet. Cardinals may fade in color when fruits, berries or greens that contain canthaxanthin are scarce.

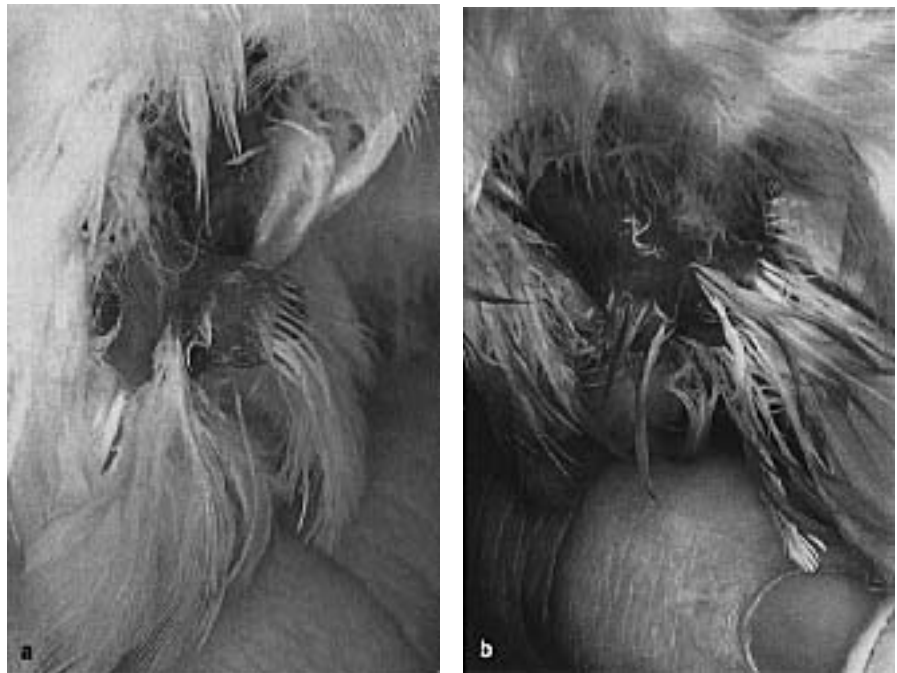
Vitamin A lacks color even though it is related to carotenoid pigments. Birds that have yellow feathers (honeyeaters) may become pale in captivity in spite of being given access to grated carrot and other sources of vitamin A precursors, due to the nutrient's being bound to undigestible cellulose. Consideration should be given to the bird's natural diet. Pollen, for example, may be a source of utilizable carotenoids such as apocarotenol, a pigment associated with golden-orange shades.

### Seasonal Feeding Practices

In passerines indigenous to tropical or arid regions, seasonal changes related to daylight hours are less important to the reproductive cycle than the periodic availability of food and water. Most successful breeders of these species mimic natural conditions by lowering the caloric, protein and fat content of diets and maximizing the birds' physical condition by allowing free flight in open aviaries during the non-breeding season. At the beginning of the breeding season, the birds are "flushed," or encouraged to come into a breeding condition by increasing the plane of nutrition. Mist-ing some species with water (to mimic rainfall) and providing green, fresh foods and foliage may stimulate breeding, particularly those species from desert environments such as the Australian grass finches. Birds must not become chilled during the misting process. Depending on the species, birds may be transferred in pairs to smaller breeding enclosures or left in flights to colony breed.

### Sexing Passerines

In some passerines, there are obvious or subtle morphologic differences between the genders. Males are generally brightly colored or elaborately marked, particularly during the breeding season. Differences in singing, courtship or nesting behavior may also provide clues as to gender. Males usually have a melodious song and are more active during courtship



**FIG 43.6** In many male Passeriformes, the seminal glomerulus swells and pushes the cloaca caudally during the breeding season. The cloacal promontory is **a)** present in the male and **b)** absent in the female, which has a flatter vent.

with dancing, hopping and assuming of various unusual postures in addition to building the nest. The females usually have more of a chirp or single-note call and are more passive in the courtship role.

In males of many species, the caudal end of the ductus deferens forms a mass of convolutions called the seminal glomerulus. During the culmination phase of the breeding cycle, the seminal glomerula pushes the cloacal wall into a prominent projection, the cloacal promontory. This can be observed by blowing the feathers on the bird's vent cranially (Figure 43.6). Hens do not develop this projection and have a flatter vent. In the non-breeding season and with immature birds, these differences are less obvious.

Laparoscopy can be used to determine gender in monomorphic passerine birds, but the small size of many species may increase the risk of this procedure. Newer methods of gender determination using DNA technology are proving useful and will probably be used more extensively in the future. The cost of these procedures tends to limit their application to more expensive species.

### Vasectomy in Finches

Estrilid finches may be vasectomized by making a 3 mm bilateral incision 5 mm lateral to the cloaca. The skin and muscle layers are incised and adipose tissue

is displaced to reveal the seminal glomus. A portion of each seminal glomus is removed. The incisions are closed with single sutures and the bird placed on antibiotics postoperatively. The procedure generally takes less than 15 minutes.<sup>5</sup>

### Combating Aggression

While passerine species may be small, some are quite territorial and others have well developed pecking orders. Head trauma, feather picking, other injuries or death may occur in individuals that have been attacked by a companion (Figure 43.7). Self-mutilation, poor body condition and increased susceptibility to disease can be indirect results of such aggression in birds that are psychologically stressed because of their low social position. Aggression is more likely to occur if the birds are overcrowded in small, open enclosures where less dominant birds have few opportunities to escape from dominant birds. Aggression-related injuries can be particularly pronounced if new birds are introduced into collections where a social order has already been established.<sup>3</sup>


Appropriate measures to prevent combat aggression will vary depending on individual circumstances. Suggestive control measures include:

- prevent overcrowding; the fewer birds, the better
- keep stocking densities low
- clip the wings or remove particularly aggressive individuals
- provide extra vegetation or visual barriers (burlap sheets) to provide less dominant birds with an escape area
- provide multiple perches, feeding locations and nesting sites
- maintain subdued lighting in indoor areas
- simultaneously introduce all birds into a new environment.

Parents that become aggressive toward their chicks are preparing to lay a second clutch of eggs and the chicks should be removed.

Sick or injured birds should be housed separately from other birds to prevent them from being injured by their healthier companions.

Successfully establishing aviaries containing psittacine, passerine and other bird species requires a working knowledge of individual behavioral characteristics and interspecies tolerance. Parrots from the



**FIG 43.7** A Zebra Finch female was presented after having been involved in an episode of territorial aggression in an overcrowded enclosure. The bird had bilateral rear limb paresis with some deep pain. The finch responded to therapy that included corticosteroids and being placed in a dark, cool (72°F) environment.

genera *Neophema* (Bourke's or Scarlet-chested Parrots) or *Polytelis* (Princess Parrots) are usually sedate and will mix well with finches. In contrast, rosellas (except for the Western Rosella) or *Psephotus* parrots (Hooded or Blue Bonnet Parrots) are usually aggressive and will kill other birds that are in their space.

### Cross-fostering Techniques

Species with long histories of domestication, such as Bengalese (Society) Finches, will usually breed freely in captivity without the use of specialized techniques. Members of this species are sometimes used as foster parents to incubate and raise other finches. Similarly, Border Canaries may be used as foster parents for other canary varieties. Cross-fostering is practiced to increase the production of a particular pair of birds. Many species will breed and lay but may require certain foods to raise the young. Many birds will immediately re-lay when eggs are pulled to foster, thereby increasing production.

One of the inherent problems in cross-fostering is that it does not enable selection for good parenting ability in the offspring. The problems that gave rise to the need for fostering in the first place are often perpetuated into future generations. Some organisms such as *Campylobacter* spp. and *Cochlosoma* spp. may cause inapparent infections in foster parent birds but be transmitted to cross-fostered juveniles where disease may result. By comparison, using foster parents may prevent some infectious diseases that are transmitted from infected parent to offspring. For example, colonies of Gouldian Finches that are air sac mite-free have been established by



using Society Finches, which are not susceptible to air sac mites, as foster parents.

Cross-fostering has also been used as a technique to enhance breeding populations of endangered species. The Helmeted Honeyeater, state bird of Victoria, Australia, is endangered. In an effort to save this bird, eggs are collected from free-ranging Helmeted Honeyeaters and are incubated in captivity by the closely related Yellow-tufted Honeyeater. This induces the free-ranging Helmeted Honeyeaters to produce a second clutch of eggs and increase the annual production of chicks from a single pair. Similar techniques have been used to save other endangered passerines such as the Black Robin (fostered under Chatham Island Robins). However, preservation and rehabilitation of suitable natural habitats must also be a priority if captive breeding and subsequent release to the wild is to be effective.

### Imprinting

One of the major disadvantages of fostered birds is that they imprint on the foster parents and may be less likely to breed with their own species. Experimental work in Bengalese and Zebra Finches has shown that development of sexual orientation and adult song patterns occur during a defined period in early juvenile life. Male finches reared by foster parents of a different species or color variety preferentially choose females of the foster species as they sexually mature. If only male members of the foster species were available, the cross-fostered males formed homosexual pairs with these birds rather than heterosexual pairs with birds of their own variety. The critical sensitive period for sexual orientation from imprinting lasts from about the 15th to the 40th days of life. Acquisition of adult song follows a similar pattern: birds raised by foster parents learn the song of the foster parent, even if this song was audible only some weeks prior to the young bird's beginning to sing.<sup>35</sup> For species-specific imprinting to occur, a finch should be exposed to its own species from the 15th to 40th days of life.

Parallels of the imprinting behavior that occur in finches have been defined in humans and other animal species. For example, adult humans retain accents acquired during childhood even when they move to new locations. By comparison, children will quickly change an original accent and acquire the one characteristic to a new location. As an example in other birds, Whooping Cranes in the United States that were foster-raised by Sandhill Cranes did not learn appropriate Whooping Crane courtship behav-

ior, yet were rejected by Sandhill Cranes during the breeding season.

Finches are an inexpensive experimental animal and are being used as a model to study neurophysiologic controls of imprinting.

### Breeding Parasitic Species of Passerines

Some finch enthusiasts relish the challenge of breeding parasitic species (birds that lay their eggs in the nests of other species) such as Paradise Whydahs (parasitize various species of the *Pytilia* family) and Broad-tailed Whydahs (parasitize Aurora Finches). Whydahs are generally bred in large planted aviaries where the parasitized finch species has first been firmly established and is breeding freely. The parallels between the appearance and behavior of the whydah chicks and the finch chicks that they mimic are striking even though the adults of the two species are very different.

If male and female whydahs do not originate from the same geographic area, they may not enter breeding condition simultaneously, preventing successful reproduction. The male whydah develops a long, flowing tail during the breeding season.

## Special Considerations in Managing Passerine Patients

Passeriformes are increasingly presented for veterinary evaluation as aviculturists recognize that successful medical and surgical treatment can be performed, even in tiny patients. However, owner financial constraints and difficulties in collecting samples from small birds may limit diagnostic and treatment options. Veterinary care in these species is frequently directed toward appropriate preventive husbandry measures and approaching medical problems from a flock perspective. As importation of wild-caught Passeriformes (eg, African finches) ceases, the cost of acquiring pairs warrants further financial investment in their care.

### Restraint and Handling

A “lights out/perches out” approach to capture is often useful for small active birds. Birds will generally not move in a dark room and can easily be removed from an enclosure with minimal stress. Once out of the enclosure, the bird can be restrained by placing the head between two fingers so that the body rests in the palm of the hand, or it can be restrained by holding the head gently between the thumb and first finger. The latter can be difficult to execute (Figure 43.8).

### Blood Collection Techniques

The right jugular vein is generally the best site for collecting blood or giving intravenous fluids. It is surprisingly large even in very small birds. A nail clip, medial metatarsal vein or cutaneous ulnar vein are alternative blood collection sites but they frequently provide insufficient sample volumes. A skin prick technique from these sites or from the external thoracic vein (which courses on either side of the rib cage just behind the shoulder) can be used. The blood is collected directly from the skin into a micro-collection tube.<sup>71</sup>

The lymphocyte is the predominant white cell in most passerine species, and lymphocytes rather than heterophils tend to increase in stress-related conditions.

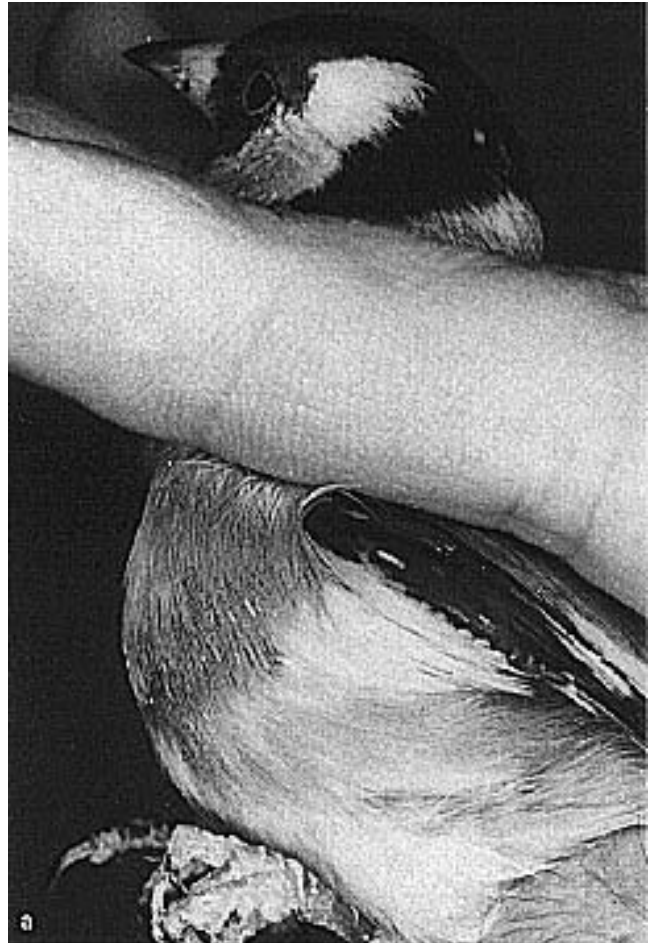### Treatment Techniques

#### Therapeutics

Although the right jugular vein can be used for administering intravenous fluids, intraosseous catheterization using a 26 ga needle is a practical means of fluid administration in a finch.

Hemorrhage may be a problem following intramuscular injections into the pectoral muscles in small birds. To minimize risk, the injection site should be located in the caudal third of the chest muscles, and a fine gauge needle should be used (25 ga or less). Aspiration should be performed prior to injecting any drug to ensure that a blood vessel has not been cannulated. After the needle has been removed the site should be observed for hemorrhage, and pressure should be applied digitally if bleeding does occur.

Drug dosing in small patients must be based on an exact weight (as determined by a gram scale) and should be delivered with precise microliter or insulin syringes to avoid overdose. There is little room for a dosing error in a small bird.



**FIG 43.8** Passeriformes can be restrained by **a)** placing the head between the second and third fingers and letting the body rest in the palm of the hand, or **b)** by holding the head between the thumb and first finger. Note the clean, dry nostril and perinasal area, relatively smooth beak, dry sleek feathers and clear bright eye suggestive of a healthy Gouldian Finch.

### Fiber Removal

It is common to see canaries and finches with fine fibers (cotton or synthetics) wrapped around their feet or legs. Swellings associated with the feet and legs should be examined using magnification to determine if fibers are involved. Individual digits or the whole foot may be lost from untreated or chronic vascular constriction (see Figure 43.4) (see Color 24).

If there are only a few fibers, it may be possible to remove them using magnification and gentle teasing with fine scissors, a needle and forceps under magnification. If numerous fibers are present, it is best to cut through all the fibers down to the skin, keeping the incision parallel to the long axis of the leg or digit. The incision should be made on the lateral side of the appendage or wherever the fibers are least imbedded. Pulling on deeply imbedded fibers can cause them to further constrict vascular structures. Once all the fibers have been severed, they may be removed with reduced risk of iatrogenic damage.

### Splinting

In small birds, lower limb fractures can often be repaired with a sandwich adhesive or masking tape splint (see Figure 16.3). The limb should be positioned in moderate flexion to enable the bird to move and to prevent bending that may occur if the leg is splinted straight. Several layers of tape may be needed. This type of splint is also used to provide support to weakened or damaged bones following the removal of tight leg bands.



## Diseases

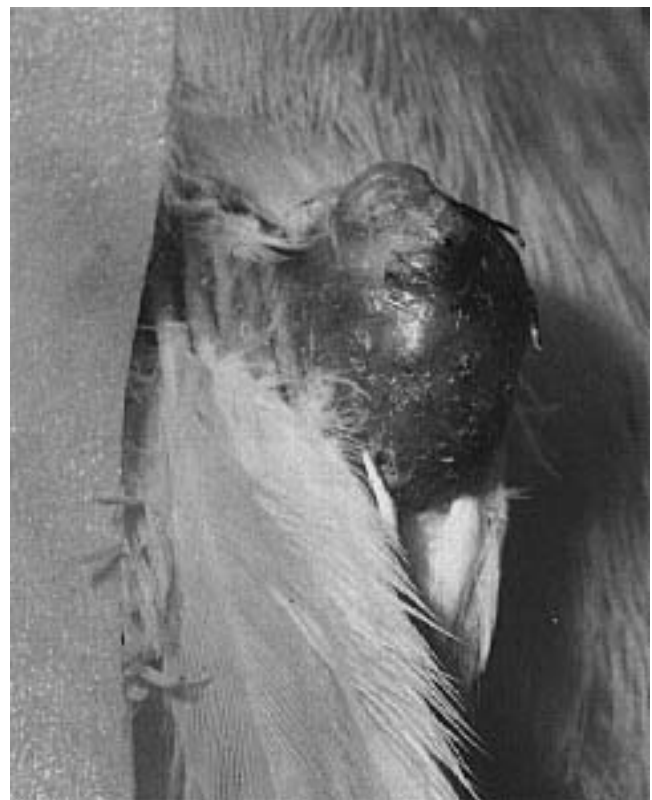Table 43.3 lists the most common diseases of captive Passeriformes that are likely to be seen by avian practitioners.

### ■ Mutations and Genetic Diseases

Some passerines, such as Gouldian Finches, new color canaries and Zebra Finches, are bred for their color mutations. Other varieties (eg, Norwich, Glouster and Yorkshire canaries) are bred for morphologic characteristics. Some of these mutations may be associated with genetic disease (Figure 43.9).



**FIG 43.9** Linebreeding and inbreeding to achieve color or morphologic mutations produce a weaker bird with greater potential for genetic abnormalities. This color mutation Gouldian Finch will have a reduced life-span in comparison to its wild-type conspecifics.



**FIG 43.10** Feather cyst formation is believed to be hereditary although infectious agents have not been ruled out as an etiology. Severe localized feather cysts, like this one in a canary, generally require surgery to remove the cyst and all affected feather follicles. Less aggressive therapy generally results in recurrence of cyst formation with subsequent molts (courtesy of Michael Murray).

### Feather Cysts (Hypopterionosis Cystica)

Heavily feathered canaries, particularly those with “double buff” soft feathers, may develop feather cysts. Norwich, Crested, Crest-bred and dimorphic new

color canaries are most frequently affected with this condition but it may occur in other varieties as well. The condition is believed to be hereditary but the mode of inheritance is not simple, and other factors apart from genetics may play a role in the development of the condition. The possibility of a vertically transmitted virus infection causing folliculitis with secondary cyst formation has been suggested.

Feather cysts may occur as isolated or multiple lumps. Often they affect the wings, back or chest. They may be bilaterally symmetrical or occur randomly on the body (Figure 43.10). Badly affected birds have irregularly directed feathers all over their bodies (see Color 24). The cysts may involve one or more feather follicles, and occasionally whole feather tracts are affected. The texture of the material within the cyst will vary depending on the stage of molt. Actively growing feather cysts will have vascular walls and contain blood and gelatinous material. Mature cysts will contain drier keratinous material, and the cyst wall may be more expansive, thickened and reduced in vascularity (see Color 24).

Medical treatment for feather cysts is generally unrewarding. Some canary breeders believe that iodine given at 0.1 ml to 50 ml drinking water will hasten the maturation of feather cysts and allow some to desiccate and slough naturally. Controlled trials to verify this mode of therapy have not been performed, and some feather cysts will heal without treatment. Once mature, the material can be expressed from small cysts but the problem will recur with the subsequent molt.

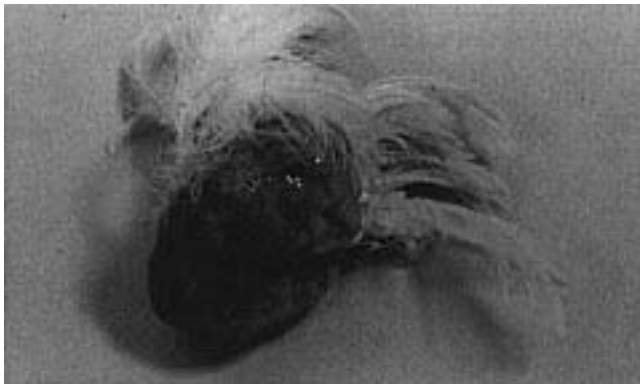
Surgical options for feather cysts include excision of individual cysts, removal of complete feather tracts or lancing and curetting individual cysts (Figure 43.11). Excision will remove the affected follicle and may be useful for solitary cysts, particularly those

**TABLE 43.3 Common Clinical Presentations and Diagnoses in Companion Passerines**

Clinical Presentation	Common Diagnoses
<b>Canaries</b>	
Open-mouthed breathing, moist rales	Air sac mites, upper respiratory tract infections (bacteria, mycoplasma), inhalant toxins, lymphoproliferative disease
Masses on head	Pox, caseated sinus abscesses, mycoplasma
Masses on wings and body	Feather cysts
Masses on legs and feet	Pox, insect bites, swelling from strangulating fibers, Knemidokoptes mites
Digit necrosis	Strangulating fibers, Staphylococcus infections
Scale on legs, swollen feet	Knemidokoptes mites, genetic, nutritional, associated with aging in some birds
Diarrhea in nestlings	Bacterial infections, Isospora, toxoplasmosis
Black spot (enlarged, dark liver visible through skin)	Toxoplasmosis, bacteremias, Plasmodium
Deaths in adults (both sexes)	Bacterial septicemias (especially colibacillosis and yersiniosis)
Abdominal enlargement	Egg binding, leukosis
Deaths in breeding hens	Egg peritonitis (often due to <i>E. coli</i> )
Feather loss from head	Feather mites, male baldness, aggression, malnutrition
Torticollis	Paramyxovirus, listeriosis, cerebral vascular accident
<b>Finches</b>	
Open-mouthed breathing, moist rales	Air sac mites (Gouldian Finches), upper respiratory tract infections
Masses on legs and feet	Knemidokoptes (esp. European Goldfinches), swelling from strangulating fibers, insect bites
Scale on legs	Knemidokoptes (may also be genetic/nutritional in some birds)
Diarrhea in nestlings	Bacterial infections, coccidiosis, toxoplasmosis, polyomavirus (in Gouldians), Cochlosoma (in Gouldians cross-fostered on Bengalese)
Voluminous white droppings	Campylobacteriosis, pancreatic insufficiency
Seed in droppings	Cochlosoma infections, vitamin E or selenium deficiency, enteritis, lack of grit
Deaths in adults (both sexes)	Bacterial septicemias (especially colibacillosis and yersiniosis); tapeworms or gizzard worms (in insectivorous finches); mycobacteriosis (esp. siskins); avian malaria (parrot finches)
Feather loss from head	Feather mites, aggression from enclosure mates
<b>Mynahs (and other Sturnidae)</b>	
Ascites, dyspnea	Iron storage disease, hepatic cirrhosis or neoplasia, congestive heart failure
Seizures	Epilepsy
Nasal discharge, sinus swelling, rales	Bacterial upper respiratory tract infections, malnutrition
Chronic weight loss, dyspnea	Aspergillosis, mycobacteriosis

located on the body. This therapy is not practical if there are numerous cysts and will not prevent new cysts from developing at remote sites. In birds with numerous cysts it may be more practical to remove a complete feather tract<sup>2</sup> (see Color 24).

The author's preference for treating feather cysts is to place hemostats at the base of the cyst and remove



**FIG 43.11** Surgically removed feather cyst from a canary (courtesy of John Cooper).

all tissue to the base of the hemostats with a radiosurgical unit. With this technique, the contents of the cyst are removed along with the skin that forms the wall of the cyst but the cyst is not totally excised. The hemostats are removed, and any remaining keratinous material is curetted from the base of the cyst. The small remaining part of the interior lining is cauterized with the radiosurgical unit. An elastic adhesive bandage is used to control minor bleeding. The advantages to this technique are that it is quick, economical and can be performed without anesthesia. Stitches are generally not required. The cosmetic effect is preferred to what occurs when cysts are simply lanced, and damage to surrounding tissue is less than with total excision. If the base of the cyst has been adequately cauterized, there is generally no recurrence at that site.

Birds with feather cysts should not be used for breeding. Unfortunately, cysts may not develop in a bird until after it is reproductively active.

### Crested Canaries

Crested varieties of Norwich or Glouster canaries are occasionally kept for show or pets. Depending on the variety, birds with crests are referred to as “coronas” or “crested” while those of the same conformation but without crests are referred to as “consorts” or “crest-bred.” The desirable crested phenotype is heterozygous for the autosomal crested gene. Birds that are homozygous for the crested gene die. Crested canaries are produced by breeding crested birds (coronas) with non-crested (consorts or crest-bred) canaries. This mating will result in 50% crested birds (Cc) and 50% non-crested birds (CC). If crested birds are mated to crested birds, normal Mendelian genetics will result in 25% non-crested, 50% crested and 25% dead chicks.

### Dominant White Lethal Factor

Canaries that are homozygous for the dominant white gene die, while heterozygous individuals are white. Two dominant white birds should not be mated or all the chicks will die. If white birds are mated with other color varieties, 50% of the chicks will be heterozygote-dominant white and 50% of the chicks will be other colors.

### Straw Feathers

Canaries and Zebra Finches occasionally show retention of the feather sheath and incomplete development of the barbs and barbules. The disease may affect first-molt fledglings or adult birds in a symmetrical fashion; it is believed to be genetically determined (see Color 24).<sup>18,58</sup>

### Cataracts

Cataracts are occasionally seen in canaries, particularly in Norwich and Yorkshires. Affected birds will often be found on the bottom of the cage or aviary, possibly avoiding flight after a previously misjudged landing. Histologically, there may be disorganization of lens cortex, fragmentation of fibers, globule formation and lens resorption. Cataracts are reported to be caused by a recessive gene in Yorkshire and Norwich canaries. They may be removed surgically.<sup>36,67</sup>

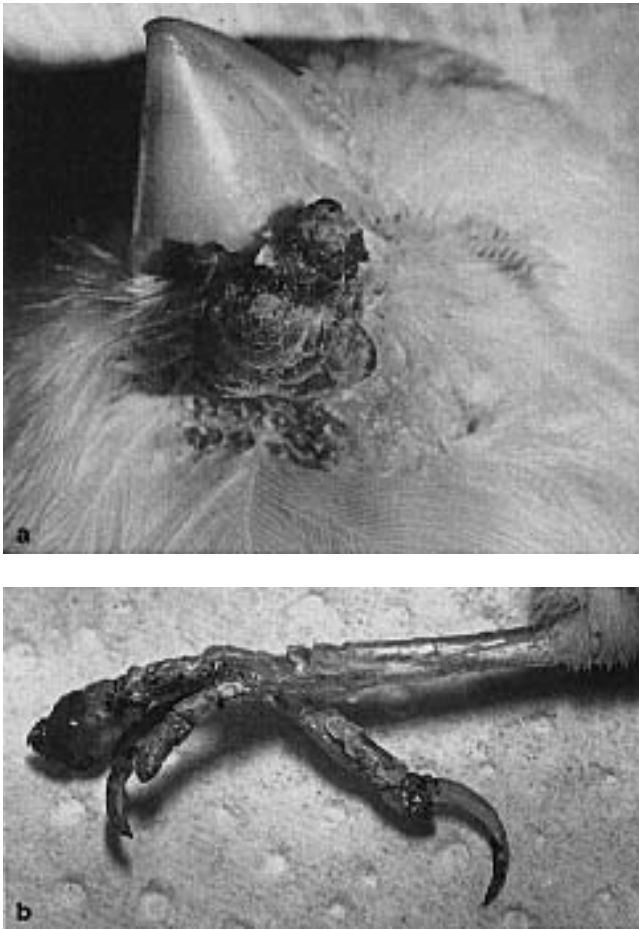
## Viral Diseases

### Poxvirus

- **Clinical Presentation:** The clinical appearance of poxvirus in passerine birds varies with the virulence of the strain, the mode of transmission and susceptibility of the host. Canaries and House Sparrows are particularly susceptible and may show the cutaneous, septicemic or diphtheroid forms of the disease (Figure 43.12). The cutaneous form of poxvirus has also been reported in a variety of free-ranging Passeriformes, eg, starlings, juncos, silvereyes and Australian magpies.<sup>26,57</sup> Poxvirus infections are usually self-limiting in free-ranging birds.

Poxvirus may be transmitted from free-ranging starlings to other members of the Sturnidae family. In one instance, all of a group of Rothschild's Mynahs exposed to infected starlings died. In Greater Hill Mynahs, poxvirus has been associated with low mortalities, but chronic eye, wattle and oral lesions occur. These include proliferative lymphocytic conjunctivitis, keratitis, chronic corneal ulcers, lid depigmentation, cataracts, eyelid distortion and scar tissue with feather loss on the head.<sup>37</sup>





**FIG 43.12** Poxvirus infections are common in canaries that are maintained outdoors in areas with high densities of mosquitoes. Depending on the species of bird and virulence of the virus, either cutaneous, diphtheritic or septicemic forms of the disease may occur. Cutaneous lesions are common on **a**) the face or **b**) feet and legs (courtesy of Michael Murray).

Mortalities of up to 100% have occurred in some outbreaks of canary pox. Acutely affected birds may show lethargy, ruffled feathers, open-mouthed breathing and death in two to three days. In less acute cases, birds may show conjunctivitis, blepharitis and lacrimation before the appearance of characteristic proliferative lesions around the eyes and mouth. Death may result if these lesions cause pharyngeal obstruction. On necropsy, birds dying acutely may show cloudy air sacs and pneumonia with proliferative necrotizing bronchitis, while those dying later in the course of the disease are more likely to show proliferative skin lesions and typical intracytoplasmic inclusions in the epidermis and respiratory epithelium. The skin lesions should be differentiated from mosquito bite abscesses, which result in discrete lumps that contain caseous material when

lanced.<sup>18,40</sup> An uncomplicated pox lesion is a contained fibrous reaction without a necrotic, expressible center.

A much milder form of cutaneous canary pox is also seen in southeastern Australia and California. Periodically more virulent strains erupt and high mortalities occur, particularly in birds kept in outdoor aviaries in areas with dense mosquito populations.

While birds affected with poxvirus will typically show intracytoplasmic Bollinger bodies, intranuclear inclusions have been demonstrated in the junco. Concurrent infections with other viruses have also been noted. Retrovirus-like particles have been found in the brains of some poxvirus-infected canaries.<sup>11</sup> Adenomatous tumors in the lungs have occurred as a sequel to poxvirus infections.

Serologic cross-reactions between strains of poxvirus in Passeriformes have not been demonstrated, but some strains will affect more than one passerine species. For example, in one outbreak, canaries and House Sparrows were the only species to show clinical signs of poxvirus or mortality even though ten species of passerine birds were present in the aviary (see Chapter 32).

- **Treatment and Control:** There is no specific treatment for poxvirus. Antibiotics may be useful to control secondary infections, and vitamin A or its natural precursor may aid in the healing process. Scarifying individual pox lesions may result in spontaneous remission. Topical application of astringent solutions such as mercurochrome or alcohol may be useful. Adenine arabinoside ointment<sup>a</sup> has also been recommended. Mild baby shampoo may be gently applied to any lesions around the eyes to remove scabs. Immune stimulants such as PEP-E<sup>b</sup> and echinacea may be of possible value.

Avian poxviruses can be transmitted by mosquitoes, mites or by contact through damaged epithelial surfaces. Bird rooms should be mosquito-proofed and treated with insecticides to eliminate vectors, and affected birds should be isolated until fully recovered. Recovered birds generally have lasting immunity to the disease but may become carriers and shed the virus. A modified live virus canary pox vaccine<sup>c</sup> is available in some countries.<sup>15,18</sup>

### Herpesvirus

Herpesviruses have been isolated from Estrildid finches, Ploceid finches (weavers and whydahs) and canaries, but in most cases they have not been asso-



ciated with disease. Outbreaks of conjunctivitis in Gouldian Finches associated with herpesvirus-like particles have been reported in Europe.<sup>64</sup>

### Cytomegalovirus

An epidemic of conjunctivitis with respiratory distress and a 70% mortality rate was reported in Australian grass finches maintained in Europe. Basophilic intranuclear inclusions were seen in karyomegalic epithelial cells of conjunctiva, esophagus and trachea. Cytomegalovirus-like particles were identified by electron microscopy.<sup>12</sup>

### Polyomavirus

Polyomavirus-like infections have been associated with several clinical presentations in passerine birds. Sporadic deaths have occurred in adult finches of various species, particularly in birds that have been stressed by transport or other factors. Ventricular mycosis has been reported as occurring concurrently with polyomavirus in many of these birds.<sup>40</sup>

In color mutation Gouldian Finches, polyomavirus-like infections have been reported to cause acute mortality in two- to three-day-old babies, and poor growth, dirty feathering and late fledging in older nestlings. Many affected birds had an abnormal lower mandible that was long and tubular (Figure 43.13). Nonspecific illness and mortality occurred in slightly older birds. Concurrent *Candida* infections were common.<sup>46</sup>

In a separate report, deaths in fledgling and immature Gouldian Finches occurred without any concurrent feathering or beak defects. The most consistent gross lesion was a swollen, pale liver.<sup>22</sup> Currently there is no effective treatment for polyomavirus. Controversy exists as to whether it is best to depopulate, rest breeding stock or to continue to breed with the expectation that birds will develop immunity (see Chapter 32).

While polyomavirus-like intranuclear inclusion bodies have been described in finches in North America, Europe and Australia, the virus has not yet been cultured from passerine species. Gross lesions that have been associated with polyomavirus infections in finches include perirenal hemorrhage, serosal or subserosal intestinal hemorrhage, splenomegaly, and swollen or mottled liver. Histologically, amphophilic intranuclear inclusion bodies are typically seen in the kidneys, heart, spleen, gastrointestinal tract or liver. Cellular necrosis may occur in the bone marrow, gastrointestinal tract, spleen or hepatocytes.



**FIG 43.13** Long, tubular lower beaks have been reported in Gouldian Finches with polyomavirus-like infections.

Diagnosis is based on the histologic presence of large, clear-to-amphophilic, intranuclear inclusion bodies in one or more organs. Fluorescence should occur using polyclonal antibody FITC-labelled conjugate specific for polyomavirus antigen. Electron microscopy should reveal polyomavirus-like particles.<sup>75</sup>

### Papillomavirus

Avian papillomavirus has been demonstrated in association with papillomas on the legs of wild European chaffinches. Three hundred and thirty birds out of approximately 25,000 birds examined were affected. The virus was purified and its physicochemical properties characterized.<sup>42,51</sup>

Viral papillomatosis has also been described in canaries from Argentina. The disease occurred seasonally during late summer and autumn over a three-year period, and the outbreaks were controlled using hygienic measures and an autogenous vaccine.<sup>45</sup>

### Paramyxovirus

Passerines are known to harbor paramyxoviruses of groups 1, 2 and 3.<sup>26</sup>

- **Group 1 (Newcastle Disease Virus):** Many weaver finches are susceptible and show conjunctivitis, pseudomembrane formation in the larynx and death. Neurologic signs are rare. Canaries rarely develop clinical signs, and infected birds should be considered asymptomatic carriers. Because species susceptibility varies, mortality patterns in an aviary may be sporadic and an infectious agent may not be considered as the cause.

- **Group 2:** Free-ranging passerines, particularly weaver finches in North Africa, are considered to be carriers of this virus. Many infected birds are asymptomatic but others may die following a period of emaciation and pneumonia.
- **Group 3:** This virus has been isolated from a variety of passerines including canaries, Gouldian Finches and weaver finches. It is generally associated with an overall poor condition and central nervous system signs (tremor, paralysis or torticollis).

### Leukosis

Sporadic deaths associated with enlarged pale livers and spleens and histopathologic lesions suggestive of leukosis have been reported in canaries in Europe, Australia and North America. A viral etiology has been proposed but has not been confirmed.<sup>1,15,18</sup> Treatment with prednisolone may slow the progression of the disease.

### Chlamydia Infections

Passeriformes are less susceptible to chlamydiosis than Psittaciformes. Chlamydia has been isolated from the droppings of clinically normal finches in households in which clinical cases of chlamydiosis occurred in psittacine species. Active disease outbreaks are intermittent, and infection rates of less than ten percent of the at-risk population are typical.<sup>16</sup> Chlamydiosis should be suspected in passerines with recurrent respiratory disease especially if they are exposed to psittacine birds.

### Mycoplasma

*Mycoplasma* spp. have been isolated from canaries with wheezing, respiratory signs including tail-bobbing and conjunctivitis. Many cases of conjunctivitis and upper respiratory disease in canaries are responsive to tylosin. However, there has been no conclusive experimental work proving that mycoplasma is associated with this syndrome<sup>25</sup> (see Figure 43.1).

Tetracyclines are believed to be effective against many mycoplasma isolates as well as chlamydia. Both of these infectious agents are difficult to identify in a live bird, and a therapeutic trial with tetracyclines may be appropriate if they are suspected of being part of a disease complex. Tylosin or tiamulin are other drugs that may be considered if mycoplasmal disease is suspected.

### Bacterial Infections

Some investigators believe that bacteria and other microorganisms should seldom be found in stained fecal smears from normal canaries and finches. Others believe that low levels of gram-positive rods or cocci are considered normal. There is generally no bacterial growth on routine aerobic microbiological cultures taken from passerine birds.<sup>15,21</sup>

The general principles for treating and controlling bacterial infections in passerines are similar to those discussed in psittacines (see Chapters 17, 33). Passerines are frequently maintained in planted aviaries and medicating individuals can be extremely impractical. If a decision is made to use water-based medication, frequently used drugs include tri-methoprim and sulfamethoxale, amoxicillin, chlor-ampenicil, tetracyclines and enrofloxacin. Some passerines are particularly sensitive to certain antimicrobial agents (dimetridazole, furacin) and care should be exercised when administering any medication to a finch or canary (see Chapter 18).

### Gram-positive Flora

- ***Staphylococcus* spp.** are normal inhabitants of the gastrointestinal tract and the skin but occasionally virulent strains may cause disease in susceptible hosts (see Chapter 33). Staphylococcal infections are commonly associated with the occurrence of thrombi in arterioles. This lesion can be particularly dangerous in small birds because collateral circulation is more limited than with larger birds. Digit necrosis, gangrenous dermatitis and pododermatitis are likely outcomes. Other clinical syndromes that have been associated with staphylococcus infections in passerines include high embryonic mortality, omphalitis, septicemia and arthritis.<sup>27</sup>

Streptococcal infections have also been associated with embryonic mortality, omphalitis, septicemia and arthritis in passerines, although, like staphylococcus, these bacteria are often part of the normal autochthonous flora.

- ***Enterococcus fecalis*** (formerly *Streptococcus fecalis*) has been associated with chronic tracheitis, pneumonia and air sac infections in canaries. Experimental infections are possible following subcutaneous or intrathoracic air sac injections but not by simple aerosol administration. Clinically affected birds have harsh respiratory sounds, voice changes and dyspnea. These changes are similar to those caused by the tracheal mite *Sternostoma tracheacolum*. Concurrent infections are possible.<sup>13</sup>

- ***Mycobacterium avium*:** Passerines are susceptible to *Mycobacterium avium* and may show nonspecific signs similar to those seen in other avian species: chronic wasting, diarrhea, polyuria, anemia, dull plumage and leukocytosis. Classic tubercles rarely develop, and gross necropsy findings usually reveal minimal changes. Two histopathologic conditions have been noted: small focal granulomas may be found in the lungs or high numbers of acid-fast bacteria may be noted in the lamina propria of the intestine.<sup>27,47,61</sup>

Red-hooded Siskins may be particularly susceptible to tuberculosis. Treatment of companion birds for *Mycobacterium* spp. is not recommended because of the public health concerns.

- ***Erysipelothrix rhusiopathiae*** may cause disease in passerines as it does in other avian species but infections are not common.
- ***Listeria monocytogenes*** is a ubiquitous organism that may be transmitted by the oral route. Canaries are particularly susceptible to listeriosis and flock outbreaks may occur. Clinical signs include torticollis, tremors, stupor, paresis or paralysis. A marked monocytosis may occur. Tetracyclines may be useful therapy in the early stages of the disease but treatment is usually ineffective in birds with CNS signs.<sup>21</sup>
- ***Clostridium perfringens*** was isolated from a canary that died after eating contaminated food. Other reports of clostridial infections in Passeriformes are scarce but there is no reason to believe that birds of this order would not be susceptible.<sup>31</sup>
- ***Megabacterium*:** A large, rod-shaped, gram-positive bacteria that was difficult to culture and was associated with a proliferative, inflammatory reaction in the proventriculus of canaries was described in Europe. In affected birds, the proventriculus had an increased pH and altered synthesis of mucopolysaccharides. The koilin lining of the ventriculus was thinner in affected canaries than in a control group, possibly as a result of the increased pH in the proventriculus. The organism identified in these birds appeared to be very similar, if not identical, to the organism defined as “megabacterium” in psittacine birds (see Color 14).<sup>69</sup>

#### Enterobacteriaceae and Other Gram-negative Bacteria

Enterobacteriaceae are generally considered secondary pathogens. The predisposing factors that allowed organisms to colonize the bird should be identified and corrected.

Oral neomycin or spectinomycin may be useful for infections localized to the gastrointestinal tract.

- ***Escherichia coli*** has been associated with a variety of disease problems in passerine birds including diarrhea, septicemia and ascending oviduct infections. Ascending oviduct infections are usually rare; however, *E. coli*-induced egg-related peritonitis and metritis have been associated with high mortality in some canary flocks in southeastern Australia. Juveniles and cock birds on the same premises were not affected. Mortalities stopped when the birds were placed on appropriate antibiotics (as indicated by sensitivity testing). Interestingly, bacteria isolated from Australian birds are frequently sensitive to a wider range of antibiotics than are commonly reported with similar organisms in the United States.<sup>44</sup>
- ***Salmonella typhimurium* var *copenhagen*** is commonly isolated from finches in Europe that develop a characteristic granulomatous ingluvitis, which can be confused with crop candidiasis or capillariasis. Histologic lesions are nonspecific and include intestinal inflammation and focal necrosis in the heart, lung, liver, spleen and kidney. Granulomas may occur in chronic cases. *Salmonella* spp. have also been isolated from cases of osteomyelitis and subcutaneous granulomas in canaries.<sup>54,62</sup>
- ***Citrobacter* sp.** is commonly found as a secondary invader in weaver finches and waxbills. It has also been associated with acute septicemia and death.<sup>21</sup>
- ***Yersinia pseudotuberculosis*** is a common cause of peracute mortality in finch and canary aviaries as well as causing general ill health, diarrhea and dyspnea. The organism is believed to have originated in Europe with worldwide dissemination occurring through rodents on ships. Yersiniosis is a widespread problem in Australian aviaries where rodent control is poor. Infections occasionally occur in free-ranging birds. Enteritis and pinpoint or large abscesses throughout the liver and spleen are characteristic gross findings. Affected birds are often too sick to respond to therapy but treatment of exposed birds with antibiotics based on sensitivity testing will usually stop an outbreak. Decontaminating the aviary and rodent-proofing food and water supplies should accompany any antibiotic therapy.<sup>27,44</sup>
- ***Klebsiella*, *Pasteurella* and *Haemophilus* spp.** are occasionally isolated from Passeriformes. *Pasteurella* is often associated with fatal septicemias following cat bite wounds. Even if injuries seem mi-

nor, birds that have been bitten or scratched by cats should receive antibiotics immediately.

- *Campylobacter fetus* var. *jejuni* has been associated with pale, voluminous droppings (“popcorn poohs”) in canaries and finches of a variety of species (particularly Gouldian Finches). European investigators have suggested that adding animal protein, minerals and vitamins (soft food) to the diet may strengthen the bird’s immune system and protect against repeated infections. Antibiotics (particularly erythromycin and tetracyclines) may also be useful.<sup>70</sup>
- *Pseudomonas* sp. infections may originate from the consumption of contaminated drinking water, misting bottles or inappropriately prepared soaked seed. The organism may cause foul-smelling diarrhea or mucopurulent pneumonia and air sacculitis. Treatment should be based on sensitivity testing, as the bacteria is often resistant to routinely used antibiotics. Steps should be taken to identify and remove environmental sources of contamination.
- *Aeromonas* sp. has been isolated from European rooks and House Sparrows.<sup>29</sup>

## Fungal Infections

### *Candida albicans*

Identifying candida in fecal swabs from passerines should be evaluated with caution. Many passerine species are fed bread products that are made with yeast. Yeast blastospores may pass through the gastrointestinal tract unchanged and appear in large numbers in the feces. These organisms do not reflect disease. Small numbers of candida blastospores may also be present as a part of autochthonous flora.

*Candida albicans* is occasionally associated with upper gastrointestinal tract infections in passerines, particularly in immunosuppressed or hand-fed neonates. Vomiting, anorexia, weight loss and diarrhea are characteristic findings. The lining of the crop may be thickened and covered with whitish “turkish towel” coating (see Color 14). Yeast blastospores or hyphae may be identified on Gram’s stain of material from a crop wash. Systemic candidiasis has also been reported in canaries.<sup>17</sup> Nystatin or ketoconazole may be useful in infections confined to the gastrointestinal tract (see Chapter 15).

### *Aspergillus* spp.

Aspergillosis may cause weight loss, respiratory distress, anorexia, vomiting or diarrhea in infected pas-

serines. Immunosuppression, usually from malnutrition, along with contaminated environmental conditions are primary factors in the development of the disease. Captured free-ranging birds are often stressed, suffering from poor nutrition and kept in unclean surroundings with decaying organic material. It is not surprising that aspergillosis occurs under these conditions. Aspergillosis is also a common postmortem finding in sporadic deaths in free-ranging passerine birds. A granulomatous form of this disease occurs in which nodules varying in color from yellow to white may be seen in the liver, lungs, kidneys, muscles and subcutaneous tissues. Most Passeriformes should be considered susceptible.<sup>57</sup>

Aspergillosis was a major cause of mortality in hatchling Helmeted Honeyeaters. Mortality was controlled by nebulizing the birds with amphotericin B.

Captive mynahs are reported to be particularly susceptible to aspergillosis, possibly because of their moist, messy droppings and the tendency for these birds to be maintained in small enclosures<sup>39,63</sup> (see Chapter 35).

### *Cryptococcus neoformans* var. *neoformans*

Respiratory or systemic cryptococcosis has been rarely diagnosed in passerine birds, even though the organism has been isolated from seed and droppings of canaries. It has been suggested that the fungus might persist from year to year on the wood of poorly cleaned enclosures. The organism has been associated with deaths in munia finches<sup>53</sup> (see Chapter 35).

### Zygomycosis (Mucormycosis)

Multiple fungal granulomas have been identified in the lung, liver or brain in canaries and Gouldian Finches fed damp, germinated seeds (sprouts). Histologically, fungal hyphae are frequently associated with blood vessel walls.

### Superficial Mycoses

Dermatomycoses are occasionally reported in passerines and generally cause alopecia (especially of the head and neck) or hyperkeratosis. *Microsporum gallinae* and *Trichophyton* spp. are the most common etiologic agents, but other saprophytic fungi may also be involved. Whole body dermatomycosis has occasionally been seen in free-ranging Red Wattle birds (a type of honeyeater) presented at the author’s practice. In one case, the client also developed dermatomycosis. Treatment with ketoconazole and griseofulvin provided some improvement but did not eliminate the infection. Topical baths with chlor-

hexidine and tamed iodine washes were irritating but they did lead to some improvement. One bird died when the owner attempted home treatment by applying a propylene glycol-based product over extensive areas of the bird's body.

## Protozoa

### Cochlosoma

*Cochlosoma* spp. are flagellates that inhabit the gastrointestinal tract of some finches. Bengalese Finches may be inapparent carriers of this organism; when they are used to foster species of Australian finches (such as Gouldians), they may pass the organism on to juveniles, causing high mortality in nestlings. Typical clinical signs include debility, dehydration and passing whole seeds in the droppings. At necropsy the intestine may be filled with a yellow suspension or whole undigested seeds. Most affected birds are six to twelve weeks of age.

The organism may be identified by direct wet preparation of fresh warm droppings or at necropsy using intestinal contents. *Cochlosoma* has six anterior flagella with a helicoidal, anterior ventral sucker.<sup>38</sup>

Treatment with ronidazole at 400 mg/kg in egg food and 400 mg/liter of drinking water for five days has been suggested. After a two-day rest period, the treatment is repeated. Dimetridazole may also be used at no more than 100 mg of active ingredient per liter of water for five days. Water containers should be disinfected and rinsed clean (the organism is sensitive to most common disinfectants) and the aviary should be kept clean and dry.<sup>15</sup>

### Trichomonas

*Trichomonas* spp. infections are occasionally seen in finches, particularly those housed near infected budgerigars. Clinical symptoms include gagging, neck stretching, regurgitation, respiratory distress, nasal discharge, green diarrhea and emaciation. Diagnosis is made by identifying the flagellate on a wet smear prepared from a crop wash. At necropsy, caseous material may be seen lining the crop and esophagus, and flagellates may be identified from this material provided that it is fresh.

### Giardia

*Giardia* sp. has also been reported to be associated occasionally with gastrointestinal tract infections in finches. Treatment is the same as for cochlosomiasis.

## Coccidiosis

Coccidia infections in passerine birds may be asymptomatic or associated with diarrheal syndromes (sometimes with blood in the droppings), emaciation, general ill health and systemic disease. Systemic protozoal disease is occasionally diagnosed in avian species, but it is difficult to classify the causative organism based solely on histologic appearance. Fresh tissues for transmission studies, blood for serology and hematology and feces for parasitologic evaluation should be saved from patients where protozoal disease is suspected.

Coccidia in the Eimeriidae family have a single host. Development of the endogenous stages occurs within host cells to produce a resistant oocyst. Sporulation of oocysts usually takes place outside the host and oocysts of different genera have a characteristic number of sporocysts, each with one or more sporozoites<sup>68</sup> (see Chapter 36).

Eimeriidae genera affecting passerines include:

- *Eimeria* (oocysts with four sporocysts each containing two sporozoites)
- *Isospora* (oocysts with two sporocysts each with four sporozoites)
- *Dorisiella* (oocysts with two sporocysts each with eight sporozoites)
- *Wenyonella* (oocysts with four sporocysts each with four sporozoites)
- *Sarcocystis* (oocysts with four sporozoites)
- *Toxoplasma* and *Cryptosporidium* (same as *Isospora*, but sporocysts are usually found individually instead of inside membrane-like oocyst wall)

When examining fresh fecal material, it is often not possible to classify coccidial oocysts because sporulation may take several days to occur (see Chapter 36).

Atoxoplasmatidae are single-host coccidia with merogony in the blood and intestinal cells, gametogony in the intestinal cells of the same individual and sporulation outside the host. This family contains a single genus, *Atoxoplasma*. Early work suggested that *Atoxoplasma* spp. could be transmitted between different bird species, particularly between House Sparrows and canaries, by an arthropod transport host (particularly the red mite *Dermanyssus gallinae*). More recent investigations have shown that these findings were incorrect, and that the parasite is transmitted directly via oocysts in the feces and that it is host-specific.<sup>21,38,43,68</sup>

### Coccidia in Canaries

Oocysts from *Atoxoplasma* or *Isospora* spp. may be found in the feces of infected canaries. *Isospora* is less pathogenic and completes its life cycle within the intestines while *atoxoplasma* develops asexually in mononuclear blood cells and spreads hematogenously to other organs including the liver, spleen and lungs.

Canaries with atoxoplasmosis may be defined as having "black spot," referring to the enlarged, dark liver that is visible beneath the skin. Diarrhea, non-specific illness and death sometimes occur. The organism can be diagnosed by identifying sporozoites on Giemsa-stained impression smears of the spleen, liver or buffy coat. The sporozoites are found in the cytoplasm of lymphoid-macrophage cells and appear as oval structures containing pink-staining chromatin. Indentation of the host nucleus often occurs (see Chapter 36). Table 43.4 is useful for differentiating between these two species.<sup>20</sup>

Sulpha drugs or amprolium are usually effective for *Isospora* sp. but *Atoxoplasma* sp. is resistant to treatment. Maintaining clean surroundings to reduce the birds' exposure to the infective oocysts may help control infections, but will probably not eradicate the organism from an aviary.

### Coccidia in Other Passerine Species

Morphologically similar *Isospora* species of coccidia have been identified in over 50 species of passerine species throughout the world. This species has been named *Isospora lacazei* although it represents more than a single species. Many other morphologically distinct species of *Isospora* have also been identified. Life cycles are believed to be similar to *Isospora canaria*.<sup>68</sup>

*Eimeria* spp. generally follow the same pattern as *Isospora* and complete their life cycle in the intestinal tract. One species, *Eimeria grallinida*, has been described in a wild-ranging Australian Magpie-Lark in which the parasite was found in the liver. The affected bird had been found in a moribund state and died shortly thereafter. On necropsy, the bird showed marked hepatic enlargement with small white foci. Various stages of the life cycle including schizogony, gametogony and oocysts were found in the bile ducts. Sporulated oocysts were consistent morphologically with *Eimeria* sp.<sup>60</sup>

Coccidia of the genus *Dorisiella* have been identified in a number of passerine species including munias,

TABLE 43.4 Characteristics of *A. serini* and *I. canaria*

Characteristic	<i>A. serini</i>	<i>I. canaria</i>
Oocyst length	20.1 (13-23) $\mu$ m	24.6 (17-30) $\mu$ m
Oocyst width	19.2 (13-23) $\mu$ m	21.8 (17-30) $\mu$ m
Length:width	1.05	1.13
Prepatent period	9-10 days	4-5 days
Patency	10 ->95 d	5-18 d post-infection
Duration of infection	4 months	2-3 weeks

avadavats, hawfinches and a Fohkein Grey-headed Crow Tit. Pathogenicity appears to be minimal. *Wenyonella* sp. has been recovered from Pied Wagtails in India.<sup>68</sup>

### Sarcocystis

Sarcocysts are common in the skeletal muscles of passerines from many geographic regions. North American cowbirds, grackles and other Passeriformes have been shown to be the intermediate hosts of *Sarcocystis falcatula*, for which opossums are the definitive host. In Australia, sarcocysts are incidental findings at necropsy and a definitive life cycle has not been determined. Cysts can sometimes be observed through the skin.<sup>33,38</sup>

### Toxoplasmosis

*Toxoplasma gondii* is occasionally identified in passerines and in isolated cases may cause death. In one outbreak, all 23 mynahs in a shipment died with visceral toxoplasmosis. It was postulated that the birds had been exposed to the organism at some time prior to shipment and that the stress of transportation had reactivated latent infections.<sup>14</sup>

Cats and other members of the Felidae family are definitive hosts for *Toxoplasma gondii*, and birds must ingest oocysts from cat droppings or visceral cysts from other animals in order to be infected. Feral cats in Australia have damaged native bird populations from direct killing and by spreading *Toxoplasma* sp. In one Tasmanian study, over 30% of free-ranging ravens were found to carry the organism. Carnivorous marsupials, many of which are threatened or endangered, are extremely susceptible to toxoplasmosis. If a free-ranging bird infected with toxoplasmosis is eaten by one of these species, the marsupial is likely to die. Birds infected with toxoplasmosis may be asymptomatic or show neurologic symptoms, ophthalmitis or sudden death. Such birds are easy targets for free-ranging carnivores. To avoid fecal contamination and the risk of toxoplasmosis, cats should be prevented from entering bird food storage areas.



### Cryptosporidiosis

*Cryptosporidium* sp. has been associated with acute onset, severe diarrhea and death in a Diamond Fire-tail Finch. At necropsy the bird showed focal cuboidal metaplasia of glandular epithelial cells of the proventriculus and amyloid deposits at the base of the glands, as well as renal amyloidosis.<sup>6</sup> Proventricular cryptosporidiosis has also been identified in canaries with concomitant salmonellosis. Renal cryptosporidiosis has been diagnosed in a Black-throated Finch.<sup>24</sup>

*Cryptosporidium* sp. has a direct life cycle but oocysts have not been identified in the droppings of clinically affected passerines. The true clinical significance of the organism is not known, as it is often associated with other disease entities.

### Blood Parasites

Blood parasites may be detected on routine screening of apparently healthy passerines, but they are occasionally implicated as the primary cause of disease or death. Life stages of the coccidian parasite *Atoxoplasma* sp. may also be seen in monocytes and lymphocytes. The occurrence of blood parasites varies from time to time and region to region. There is some evidence that the incidence of blood parasites in birds has decreased in some areas as a result of decreased numbers of invertebrate vectors.<sup>4</sup>

Passerine families reported to be most commonly infected with hematozoa in one European study included Paridae (tits, 8% affected), Sylviidae (warblers, 14% affected) and Turidae (thrushes, 10% affected). The most commonly encountered parasites included *Haemoproteus* sp. (4%), *Leucocytozoon* sp. (1.8%), *Trypanosoma* (0.9%), *Plasmodium* (0.8%), *Atoxoplasma* (0.2%) and microfilaria (0.1%). *Haemoproteus* sp. is also the most common blood parasite encountered in birds in North America and Australia.<sup>4,43</sup>

Other blood parasites that are occasionally seen in passerines include the small tick-borne erythrocytic parasites *Aegyptianella* and *Nuttallia* spp.

### Plasmodium

*Plasmodium* spp., the cause of avian malaria, are mosquito-borne protozoa of the family Plasmodiidae that occur worldwide. Sporogony occurs in the invertebrate host, schizogony occurs in erythrocytes and pigment is formed from the host cell hemoglobin. Each of the avian plasmodia has a limited host range but they do not appear to be particularly host-specific. *Plasmodium* spp. have been described in free-

ranging wild tits, Fringillid finches, Old World warblers, thrushes, starlings, sparrows and in Australian magpies.<sup>4,43</sup>

The parasite has been associated with significant mortalities in Blue-faced Parrot Finches in the Taronga Zoo in Sydney. Free-ranging house sparrows are believed to have been asymptomatic carriers of the organism. No other species of captive birds at the zoo were affected. The parrot finches showed signs of lethargy, anorexia, labored respiration and death. A darkened, enlarged liver could be observed as a "black spot" through the skin and muscle of the abdominal wall. Treatment with chloroquine or pyrimethamine was successful in some cases but the birds did not have any lasting immunity and were susceptible to repeated infections. Controlling mosquito vectors is necessary to prevent infections. Avian malaria has also been reported to cause deaths in canaries and other species.<sup>23,71</sup>

### Haemoproteus

Like *Plasmodium* sp., *Haemoproteus* spp. are found worldwide and are capable of infecting a variety of birds. Each species appears to have a limited host range but they are not particularly host-specific and generally cause only mild or inapparent clinical symptoms. Diagnosis is based on identification of typical pigment containing gamonts in erythrocytes. For most species of *Haemoproteus* the intermediate hosts are hippoboscids, biting midges (*Culicoides* spp.) or tabanids.

Passerine species in which *Haemoproteus* spp. have been reported are numerous and include mynahs, Fringillid finches, swallows, fly catchers, tits, sparrows, weaver finches, warblers and thrushes. In one outbreak, canaries were believed to have been infected following exposure to free-ranging house sparrows.<sup>38,43,57</sup>

Schizonts have a predilection for development in skeletal and cardiac muscle, lung and spleen. One form of schizont is sausage-shaped and often branches during development within capillary endothelium. Megaloschizonts may develop in the absence of circulating gamonts and reach sizes of up to 200 µm. Extensive myopathy and myonecrosis may be associated with intramuscular megaloschizonts (eg, commonly seen in free-ranging infected Pied Currawong around Sydney, Australia). These birds show multiple, yellow streaks in pectoral and other muscles, and most are presented thin, weak and unable to fly.<sup>57</sup> Treatment with antimalarial drugs

(chloroquine at 250 mg/120 ml drinking water for one to two weeks) may be useful. Orange juice may be added to the drinking water to make the drug more palatable.<sup>71</sup>

### ***Leucocytozoon***

*Leucocytozoon* spp. occur worldwide except for South America (where appropriate simuliid vectors are absent). These parasites may infect either erythrocytes or leukocytes. Parasitized cells are so distorted by the organism that it may be difficult to determine their origin. Pigment is not produced by leucocytozoon and schizonts do not appear in peripheral blood. Megalosphizonts can be found in brain, liver, lung, kidney, intestinal tissue and lymphoid tissue.

Most leucocytozoon infections are subclinical, although vague signs of illness and death were reported in infected Crested Oropendolas from a zoo in Florida. These birds hemorrhaged from protozoal cysts within hepatic and renal tissue. It was thought that the leucocytozoon may have been transmitted from free-flying black flies infected by feeding on local leucocytozoon-infected crows. The oropendolas, which had been trapped in South America, may have been particularly susceptible because of lack of previous exposure to the parasite.<sup>52</sup>

Leucocytozoon-like megalosphizonts have also been described in association with acute and fatal hepatocellular necrosis in canaries in Texas. Outbreaks of the disease were controlled with dimetridazole.<sup>55</sup>

Some other passerine species that have been reported to harbor *Leucocytozoon* spp. include Fringillid finches, swallows, tits, warblers, thrushes, starlings, blackbirds, canaries and lyrebirds.<sup>38,43,57</sup>

### ***Trypanosoma***

Trypanosomes are found worldwide but their incidence is low and they may only be found during summer months in temperate climates. Vectors are thought to include hippoboscids flies (*Ornithomyia avicularia*), red mites (*Dermanyssus gallinae*), simuliids and mosquitoes. Evidence suggests that the parasites may be transmitted by contamination rather than inoculative routes. Diagnosis is by finding the parasites on stained blood smears.<sup>38</sup> High prevalence levels of this parasite (8.3%) have been reported along the coast of the Baltic Sea in Europe.<sup>72</sup> Treatment is not warranted.

Trypanosomes have been identified in over 14 passerine families, including Fringillid finches and canaries, swallows, tits and pipits.<sup>38,43</sup>

### **Avian Piroplasmosis**

Piroplasmosis is an important tick-borne infection that has been identified in many species of birds in the Mediterranean, Asia and Africa but it has not yet been found in Australia. *Aegyptianella* sp. is a rickettsial organism that appears as a small, signet ring-shaped structure in the cytoplasm of infected erythrocytes. Clinical signs of infection may include anemia, fever, lethargy and occasionally jaundice. Some passerine species in which piroplasmosis has been identified include crows, rooks, larks, sparrows and buntings.<sup>38</sup> Treatment with doxycycline or antimalarial drugs may be useful.

### **Filarial Worms**

Microfilaria and adult filarial nematodes (*Serfatospiculum amaculata* and *Diplotrinaena* sp.) have been reported at a low prevalence in a variety of species of passerines such as lyrebirds, Estrilid finches, honeyeaters, thrushes, grackles, sparrows and corvids. Most infections have not been associated with any disease and the parasites have been found incidentally in blood smears (microfilaria) or at necropsy (adults). *Splendidofilaria passerina* may be pathogenic in sparrows. Treatment is not generally warranted but levamisole may be useful.<sup>38,43,57</sup>

## **Internal Parasites**

### **Acanthocephalans**

Both adult and intermediate stages of acanthocephalan parasites may be found in free-ranging passerines. Adult worms are generally susceptible to benzimidazole anthelmintics. Genera affecting passerines include *Polymorphous*, *Plagiorhynchus*, *Prosthorhynchus* and *Centrorhynchus*.

The Superb Lyrebird, the largest passerine species, is a ground-dwelling inhabitant of rain forests in southeastern Australia. The acanthocephalan parasite *Plagiorhynchus menurae* has been identified in lyrebirds showing weakness, emaciation and respiratory distress. Duodenal necrosis has been demonstrated at necropsy. Invertebrates are postulated to be the intermediate hosts.<sup>48,50</sup>

Small cysts, 2 to 3 mm long and shaped like rice grains, may sometimes be found in the subcutaneous tissues of the neck and thorax in a wide variety of Australian passerine birds. These cysts are intermediate stages of the acanthocephalan *Oncicola poma-tostomi*, the adult stages of which are found in the intestines of dingos and feral cats. The initial host is postulated to be scavenging insects.<sup>50</sup>

### Cestodes

Because tapeworms require arthropods as intermediate hosts, they are predominately a problem in softbill and insectivorous finches. They are normally not seen in canaries or exclusively seed-eating birds (such as Gouldian Finches), except in situations where parent birds feed insects to their offspring or the insects are accidentally consumed with the seeds.

Many different tapeworms have been described in passerines but in most cases, infectivity levels are low, and the parasites cause no clinical disease. Emaciation, diarrhea, general debilitation and death may occur in birds that are stressed and are continuously exposed to infected intermediate hosts. Proglottids or hexacanth larvae may be noted on gross or microscopic examination of droppings, but these are passed only intermittently. Certain finch species, eg, parrot finches and Diamond Firetails, are particularly prone to developing intestinal obstructions from heavy *Choanotaenia* sp. infections. These high levels of infectivity are common in densely planted aviaries with compost heaps or other sources of infected intermediate hosts.

Tapeworms can be avoided by limiting access to intermediate hosts and by using insect-proof screening. Other sources of protein (such as commercially available formulated diets, insectivore mixes, egg food or grated cheese) may replace live invertebrates as food items. However, some birds may not accept these alternative foods and may die or be left susceptible to disease because of poor nutrition. Others will be reluctant to breed without live food or may desert their nestlings.

Effective anthelmintics for passerines include praziquantel and oxfendazole. In cases where it is not appropriate to prevent access to intermediate hosts, a regular deworming program will lower the infection rate.<sup>18</sup>

### Trematodes

These parasites have complicated life cycles that typically involve snails as initial intermediate hosts and other invertebrates as secondary intermediate hosts. It is unlikely that appropriate conditions for completion of the life cycle will be found, except possibly in planted aviaries.

Trematodes are seen occasionally in wild-caught passerines.<sup>38,50</sup> *Collyriculum* sp. may be found encysted in the skin of birds. *C. faba* forms 4 to 6 mm cysts on passerine birds such as sparrows and starlings, as

well as gallinaceous birds. These cysts have been reported to cause death in wood thrushes by obstructing the cloaca.

Schistosomes are trematodes that live in blood vessels. *Gigantobilharzia huronensis* is a blood fluke that has been reported in North American goldfinches and cardinals. It has also been experimentally transmitted to canaries.

*Prosthogonimus* sp. are trematodes affecting the intestinal tract, cloaca, bursa or oviduct. These parasites have been found worldwide in passerine species such as sparrows, corvids, starlings and thornbills.<sup>38</sup> They are not particularly pathogenic, and if clinical signs occur they are generally nonspecific. Dragonflies and snails are intermediate hosts. Praziquantel may be useful in treating trematodes.

### Nematodes

- **Ascaridia:** Two main types of roundworms affect passerines: *Ascaridia* spp., which have direct life cycles, and *Porrocecum* spp., which have indirect life cycles with invertebrates such as earthworms as the intermediate host. Both types of roundworms may be associated with weight loss, diarrhea, general debility and sometimes neurologic symptoms. *Ascaridia* spp. are uncommon in passerines.

*Porrocecum* spp. have been found in a variety of free-ranging passerines, for example pipits, quail-thrush, thrush, blackbirds, Australian magpies, currawongs and corvids. Fibrous tumors, believed to have been induced by larval *Porrocecum* spp. have been described in blackbirds on the peritoneal surface of the intestine.<sup>38,50</sup> Fenbendazole, piperazine and levamisole are useful in treating ascarid infections.

- **Capillaria:** *Capillaria* spp. are cosmopolitan in their distribution and affect a range of passerine species. The life cycle is direct or may involve earthworms as paratenic hosts. Susceptibility does not depend on dietary preferences, and the parasite has been found to cause disease in a variety of seed-eaters (such as canaries), insectivorous and omnivorous species (such as weavers, whydahs, jays and mynahs) and honeyeaters.

Birds with low numbers of capillaria may be subclinical. Higher parasite loads may lead to weight loss, diarrhea, general ill health and death. These worms may localize to a variety of sites along the gastrointestinal tract. They may be associated with white or cream plaques in the buccal cavity or pharynx and swelling and lumen distension of the crop, proven-

triculus, intestine or bowel. Typical bi-polar plugs may be found by directly swabbing lesions or by fecal flotation.

Capillaria are often more difficult to treat than ascarids. Aviary hygiene and removal of earthworms are important control measures. Levamisole, fenbendazole and oxfendazole may be effective in some cases.

- **Spiruroid:** *Acuaria skrjabini* has been associated with significant mortalities in Australian aviaries housing both native and imported finches. This ventricular and proventricular worm parasite does not affect psittacine birds. The parasite lives under the koilin lining of the ventriculus, and characteristic embryonated eggs are passed in the feces. Attempts to identify intermediate hosts in this species have been unsuccessful, but other species of *Acuaria* are believed to be transmitted by arthropod vectors. The parasite is resistant to treatment with many common anthelmintics, but oxfendazole may be effective.

*Acuaria* spp. have been reported in a variety of free-ranging passerines in Australia, eg, bushlarks, trillers, thrush, flycatchers, whistlers, shrike-thrush, honeyeaters, Australian magpies, currawongs and corvids.<sup>50</sup>

Other spiruroid worms that occur worldwide and may be found in the proventriculus or ventriculus of passerine species include *Dispharnyx nasuata* (which has been described in the House Sparrow, starling, catbird and gallinaceous birds) and *Spiroptera incerta*. These worms have been reported to cause swelling of the proventricular mucosa and may inhibit the passage of food.<sup>74</sup>

- **Eye Nematodes:** *Oxyspirura mansoni* has been reported in mynahs, sparrows and other passerines. The parasite is found behind the nictitating membrane or in the conjunctival sac or the nasolacrimal duct. The intermediate host is the cockroach. Worms should be mechanically removed and any inflammation treated symptomatically. Ivermectin is effective.<sup>36</sup>
- **Respiratory Nematodes:** *Syngamus trachea* (gape-worm) affects a range of passerine species as well as birds from other orders. Corvids, starlings and blackbirds are particularly susceptible. Earthworms may act as transport hosts. Levamisole, ivermectin and fenbendazole are effective in treating this parasite, but caution should be exercised when treating birds with heavy infections. Tracheal obstruction may oc-

cur when the parasites are killed. Mechanical removal of worms and treatment with low doses of anthelmintics over several days is an effective therapeutic plan.

### Arthropod Parasites

- **Respiratory Mites:** Respiratory acariasis ("air sac mite infection") caused by *Sternostoma tracheacolum* is a common cause of dyspnea, open-mouthed breathing and wheezing respiration in canaries and Gouldian Finches. "Air sac mites" is a misnomer given that these parasites are frequently found in the trachea, particularly near the syrinx. Occasionally, the mites may be visualized by wetting the feathers of the bird's neck with alcohol and transilluminating the trachea with a bright source of light. If mites are present, they may be visible as tiny, dark, moving, pinhead-sized spots. Failure to see the mites does not rule out their occurrence because the mites may be present lower in the respiratory tract.

There are several options for treating this mite. Ivermectin may be used orally or topically. A dichlorvos pest strip may be placed (according to manufacturer's directions) near but out of reach of the birds. Birds may also be sprayed with pyrethrin synergized with piperonyl-butoxide insecticide spray.

Other species of passerines apart from canaries and Gouldian Finches may harbor *S. tracheacolum*, but they are less frequently affected and less likely to show severe clinical symptoms. Other species of *Sternostoma* mites have been recorded in passerines including *S. sialophilus* in Eastern Bluebirds, *S. spatulatum* in Olive-backed Thrush and *S. cryptohyncheum* in sparrows. A nasal rhynonyssid mite *Speleognathus sturni*, which occasionally causes nasal discharge, has been recorded in starlings.

*Cytodites nudus* is another mite that has been associated with respiratory disease in free-ranging passerines. It is much less common than *Sternostoma* sp. and may be found in the abdominal cavity as well as the respiratory system. Heavy infections have been associated with granulomatous pneumonia, peritonitis and obstruction of the respiratory passages.<sup>38</sup> Treatment is as described for other air sac mites.

### External Parasites

#### Skin and Feather Mites

- **Scaly Mites:** *Knemidokoptes pilae* (and several other less common species) tend to cause hyperkeratotic lesions on the feet in passerines. This is in contrast

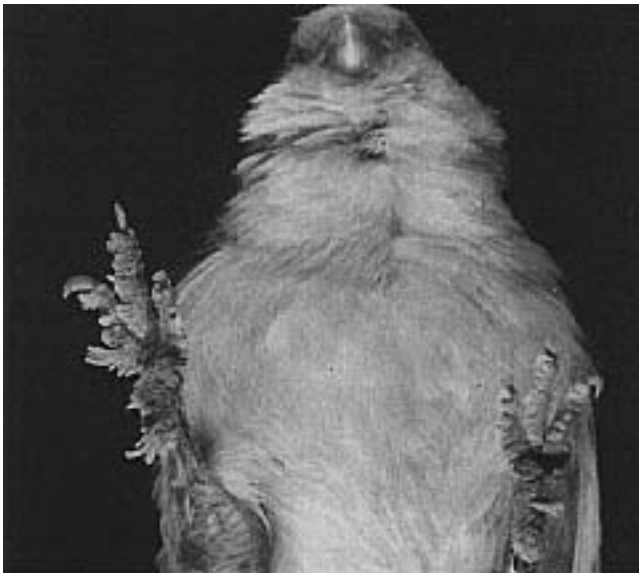
to infections in psittacine birds, which are primarily associated with beak lesions. Hyperkeratosis caused by scaly mite needs to be differentiated from generalized hyperkeratosis of the feet and legs that occurs with malnutrition and age in some canaries and other passerines (see Color 24). Scaly mite lesions start as crusts on the plantar surface of the foot and gradually get thicker. Flexion of the joints of the digits causes the thickening keratin to split and gradually enlarge, making it difficult for the bird to perch. Scaly mite lesions in passerines are sometimes referred to as “tassel foot” because of this characteristic appearance (Figure 43.14). European goldfinches and canaries are particularly susceptible to *Knemidokoptes* spp. but the condition has been reported in a wide range of Passeriformes (Figure 43.15).

*Knemidokoptes* spp. may be treated with topical ivermectin. A single dose may be effective in mild cases. A repeat dose three weeks later may be needed in more severe cases.

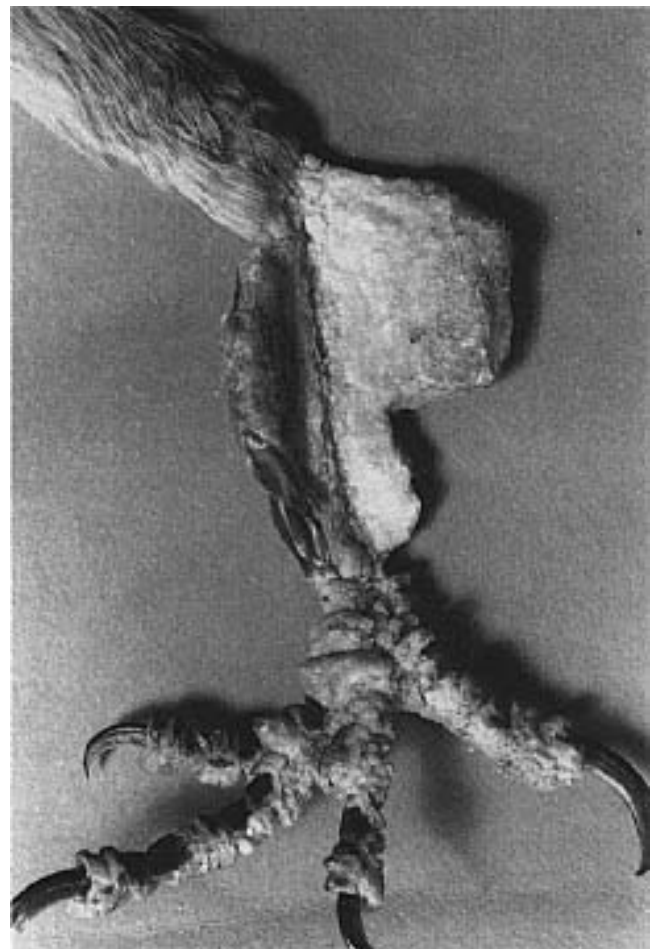
- **Feather Mites:** *Dermanyssus* sp. (red mites) and *Ornithonyssus* sp. (fowl mites) are not host-specific and may be found on a variety of Passeriformes including canaries, starlings and mynahs. These mites commonly cause irritation and anemia. Deaths have been reported with heavy infections in small birds. Non-pathogenic feather mites of a variety of genera (*Analgas*, *Megninia* and *Rivoltasia*) may also occur. Lightly dusting birds with pyrethrin or carbaryl pow-

ders may be effective. Placing the powder in a salt shaker and “lightly salting” is sufficient.

- **Quill mites** are not particularly species-specific and may attack both passerine and non-passerine species. *Dermoglyphus*, *Syringophilus*, *Picobia* and *Harpyhynchus* are genera that have been reported on Passeriformes. *Harpyhynchus* sp. has been associated with extensive dermatitis as well as cysts and skin tumors on hawfinches and a Lanceolate Warbler. Hanging a dichlorvos pest strip near birds affected with quill mites has eliminated the parasite in some cases. Treating the bird with ivermectin should be effective.
- **Epidermoptic Mites**, which may be carried mechanically by hippoboscids flies, cause a depilating dermatitis followed by scale formation (Figure 43.16). *Myialges* sp. (from a Blue Tit and Pekin Robin),



**FIG 43.14** A mature female canary was presented with a three-week history of anorexia and lying on the bottom of the enclosure. The proliferative hyperkeratotic lesions on this canary's foot are characteristic for a *Knemidokoptes* sp. infection (“tassel foot”) (courtesy of Terry Campbell).



**FIG 43.15** A group of several hundred robins died following the ingestion of pesticide-contaminated worms. Several of the birds had hyperkeratotic lesions on the feet and legs. These were confirmed to be caused by *Knemidokoptes* sp. by demonstrating the mite on skin scrapings.

*Epidermotes bilobatus* (from canaries) and *Microlichus avus* (from canaries, House Sparrows and mynahs) have been described in Passeriformes. Epidermoptic mites may be easily identified on microscopic examination of skin scrapings. Trombidiform mites of the genus *Neochelytiella* have also been reported to cause depilum mangle in canaries and Pekin Robins. Treatment options are like those described for quill mites.<sup>38</sup>

### Lice

Lice are more common on Passeriformes than they are on Psittaciformes. Some of the genera of biting lice (*Amblycera*) that occur on passerines include *Colpocephalum*, *Menacanthus*, *Machaerilaemus*, *Mysidea* and *Rininus*. These lice are not specialized for life on particular feathers and are able to move quickly. Chewing lice (*Ischnocera*) are often specifically adapted to a particular part of the bird's body and are generally more sluggish than biting lice. Some genera that affect passerines include *Bruelia* (on canaries and House Sparrows), *Sturnidoecus* (on starlings and other passerines), *Degeeriella* and *Philopterus*. Signs of the presence of lice include restlessness and biting, excessive preening and damage to plumage. Some cases of baldness in canaries are caused by lice.

Lice undergo a complete life cycle on the bird, and a weekly dusting with pyrethrin is an effective method of control.



**FIG 43.16** A number of external parasites including quill mites, epidermoptic mites and lice can cause skin irritation, pruritus and plumage damage.

## Metabolic Diseases

### Iron Storage Disease and Related Entities

Various Passeriformes species including Indian Hill Mynahs, Rothschild's Mynahs, quetzals, Birds of Paradise, Green Cat Birds and tanagers have been reported to be susceptible to excessive accumulation of iron in the liver.<sup>28,30,59</sup> In a group of 11 mynah birds that varied from five to ten years in age, clinical signs associated with hepatomegaly and ascites included a three-day to three-month history of listlessness, regurgitation, dyspnea, weight loss, diarrhea, coughing, wheezing and syncope. Most of the birds died within several days of presentation.<sup>59</sup>

Radiographs may reveal hepatic enlargement and ascites in affected birds. Liver enzymes are typically elevated while total serum protein is low. Diagnosis using biopsy is discussed in Chapters 13 and 20.

At necropsy birds may show an enlarged, congested liver which may be tan in color (see Color 20). Histologically the distinction is made between hemosiderosis, where there is no visible tissue alteration but an increased amount of hemosiderin, and hemochromatosis, where there are pathologic changes in the hemosiderin-containing tissues. Hepatic pathology may include congestion, focal necrosis, accumulation of inflammatory cells and fibrosis. Iron-processing cells are absent from the spleen and the spleen does not contain iron pigments.<sup>28,30,34</sup>

Neoplasia including lymphosarcoma, hepatocellular carcinoma and erythroblastosis has been associated with iron storage disease. The neoplastic cells do not contain iron.

Iron storage disease is believed to be associated with high dietary iron levels in avian species with problems in processing iron. Susceptible species should be kept on low-iron diets such as fresh fruit and commercially available formulated rations that are low in iron (less than 60 parts per million) (see Chapter 20).

### Amyloidosis

Amyloidosis is common in Gouldian Finches and is occasionally seen in other Passeriformes species.<sup>39</sup> Affected birds may be found dead, have a chronic nonspecific history of illness or suffer from concurrent infections (polyomavirus, cryptosporidio-



sis). Social stress may play a role in the development of the disease. The liver and kidneys may appear normal at necropsy even though they may be severely affected histologically. More often they will appear pale and yellowish. A hereditary predisposition is suspected.<sup>18,46</sup>

### Hepatic Lipidosis

Fatty livers are occasionally seen in Estrilid finches (Zebra Finches, parrot finches and Star Finches) and may be associated with inadequate exercise and high-energy diets such as soft foods and mealworms. The liver is swollen, yellow or tan in color and may float in formalin.<sup>18</sup> The use of some formulated diets may help resolve or prevent hepatic lipidosis.

### Toxicosis

Canaries and finches are particularly susceptible to inhalant toxins because they breathe more air per gram of body weight than larger birds, and they have a highly efficient gas exchange system (see Chapter 22). Carbon monoxide exposure from any source (car exhaust, gas furnace leaks, kerosene stoves) can be rapidly fatal. There may be minimal changes at necropsy or the lungs and blood may appear bright red. Carbon dioxide poisoning may occur in crowded, poorly ventilated shipping boxes. Passerines, like psittacines, are very susceptible to the gases released from overheated polytetrafluoroethylene<sup>65</sup> (see Chapter 37).

Certain varieties of avocado may be toxic to some Passeriformes. Postmortem findings in intoxicated birds include hydropericardium and subcutaneous edema in the pectoral area.<sup>32</sup> Deaths have occurred in American Goldfinches after consuming green almonds, presumably from cyanide released by hydrolysis of amygdalin, a cyanogenic glycoside.

Ethanol toxicity has been reported in free-ranging passerines (especially Cedar Waxwings) following the ingestion of hawthorn pomes or other fruits that have frozen and then thawed allowing yeast fermentation of sugars to produce ethanol. Birds are lethargic, ataxic or may be in a stupor (“drunk”). Many intoxicated birds die from accidents that occur while they are “flying under the influence.” Diagnosis is based on analyzing crop contents for ethanol concentrations.<sup>19</sup>

Heavy metal toxicities caused by the consumption of wire are uncommon in passerines because they have limited capacity to damage metal objects. Lead or zinc toxicosis has occasionally been seen when galvanized wire has been used in the construction or repair of enclosures. Heavy metal particles may be identified on radiographs, but most affected birds die quickly. Removing the source of heavy metals and administration of chelation therapy are recommended. The occurrence of “new wire disease” can be reduced by scrubbing galvanized wire with a dilute acetic acid solution and allowing it to weather before it is used for enclosure construction; however, even wire that is washed may still be toxic (see Chapter 37).

### Neoplastic Diseases

Passeriformes have one of the lowest incidence of tumors of any order of birds or mammals. Neoplasms that have been regularly reported include leukosis in canaries, adenomas associated with poxvirus, papillomas in finches and neoplasia associated with iron storage disease.

#### Products Mentioned in the Text

- a. Vira-A, Parke Davis, Morris Plains, NJ
- b. PEP-E, Phylomed, Plantation, FL
- c. Biomune, Inc, Lenexa, KS

## References and Suggested Reading

- Bauk L: Lymphosarcoma/avian leukosis in pet birds: Case reports. *Proc Assoc Avian Vet*, 1986, pp 241-245.
- Bauk L: Radical surgery for the treatment of feather cysts in the canary. *J Assoc Avian Vet* 1(5):200-201, 1987.
- Bauk L: Diseases of the finch as seen in a commercial import station. *Proc Assoc Avian Vet*, 1989, p 196-201.
- Bennett GF, et al: Blood parasites of some birds from the Lorraine Region, France. *J Wildl Dis* 18:81-88, 1982.
- Birkhead TR, Pellatt JE: Vasectomy in small passerine birds. *Vet Rec* 125:646, 1989.
- Blagburn BL, et al: *Cryptosporidium* sp. infection in the proventriculus of an Australian diamond firetail finch (*Steganopleura bella*: Passeriformes, Estrildidae) *Avian Dis* 34:1027-1039, 1990.
- Box ED: Recovery of *Sarcocystis* sporocysts from feces after oral administration. *Proc Helminth Soc Washington* 50:2, 1983.
- Buckley PA: Plumage and pigmentation. In Petrak ML (ed): *Diseases of Cage and Aviary Birds* 2nd ed, 1982, pp 59-74.
- Campbell TW: Infraorbital sinus aspiration. *Assoc Avian Vet Newsletter* 4:38, 1983.
- Christadis I, Schodde R: Relationships of Australo-Papuan songbirds: Protein evidence. *Ibis* 133:277-285, 1991.
- Davis AJ, et al: Morphology of cytoplasmic neuronal inclusions in canaries with poxvirus infection. *Proc 37th West Poul Dis Conf*, 1988, pp 108-109.
- Desmidt M, et al: Cytomegalovirus-like conjunctivitis in Australian finches. *J Assoc Avian Vet* 5(3):132-136, 1991.
- Devriese LA, et al: Tracheitis due to *Enterococcus faecalis* infection in canaries. *J Assoc Avian Vet* 4(2):113-116, 1990.
- Dhillon AS, et al: Toxoplasmosis in mynahs. *Avian Dis* 26(2):445-449, 1982.
- Dorrestein GM, et al: Disease of passerines, especially canaries and finches. *Proc Assoc Avian Vet*, 1985, pp 53-70.
- Dustin LR: Clinical conditions in a pet canary practice. *J Assoc Avian Vet* 4(2):80-82, 1990.
- Fain-Binda JC, et al: Canaries: Systemic candidosis. *Veterinaria Argentina* 2:186-189, 1985.
- Filippich LJ: Diseases of finches. *Proc 178 Post Grad Comm Vet Sci, Univ Sydney*, 1991, pp 357-381.
- Fitzgerald, et al: Suspected ethanol toxicosis in two wild cedar waxwings. *Avian Dis* 34:488-490, 1990.
- Flammer K: Clinical aspects of toxoplasmosis in canaries. *Proc Assoc Avian Vet*, 1987, pp 33-35.
- Flammer K: Bacterial diseases of caged birds. *Proc 178 Post Grad Comm Vet Sci, Univ Sydney*, 1991, pp 149-154.
- Forshaw D, et al: Infection with a virus resembling papovavirus in gouldian finches (*Erythrura gouldiae*). *Aust Vet J* 65:26-28, 1988.
- Fowler A: Avian malaria in sparrows at Taronga Zoo. *Proc Wildl Dis Assoc (Aust Branch)*, Warrumbungles National Park, (supplementary pages) 1992.
- Gardiner CH, Imes GD: *Cryptosporidium* sp. in the kidney of a black-throated finch. *J Am Vet Med Assoc* 185(11):1401-1402, 1984.
- Gaskin JM: Mycoplasmosis of caged birds. *Proc Assoc Avian Vet*, 1987, pp 57-60.
- Gerlach H: Virus diseases in pet birds. *Vet Clin No Am* 14(2):299-315, 1984.
- Gerlach H: Bacterial diseases. In Harrison GJ, Harrison LR (eds): *Clinical Avian Medicine and Surgery*. Philadelphia, WB Saunders Co, 1986.
- Gerlach H: The so-called iron storage disease in mynahs. *Proc 1st Intl Conf Zool & Avian Med, Hawaii*, 1987, pp 79-86.
- Glander G, Siegmund O: Occurrence of *Aeromonas hydrophila* in wild birds. *Avian Pathol* 18:685-695, 1989.
- Gosselin SJ, Kramer LW: Pathophysiology of excessive iron storage in mynah birds. *J Am Vet Med Assoc* 183(11):1238-1240, 1983.
- Greenham LW, et al: *Clostridium perfringens* in pelleted food. *Vet Rec* 120:23, 557, 1987.
- Hargis AM, et al: Avocado (*Persea americana*) intoxication in caged birds. *J Am Vet Med Assoc* 194(1):64-66, 1989.
- Harrigan K: Bird parasitism. *Post Grad Comm Vet Sci, Univ Sydney*, 1981, pp 337-396.
- Hill JE, et al: Hepathology and lymphosarcoma in a mynah bird with excessive iron storage. *Avian Dis* 30(3):634-636, 1986.
- Immelmann K: The influence of early experience upon the development of social behaviour in estrildine finches. *Proc XVth Intl Ornith Cong*, 1972, pp 316-338.
- Karpinski LG: Ophthalmology. In Harrison GJ, Harrison LR (eds): *Clinical Avian Medicine and Surgery*. Philadelphia, WB Saunders, 1986, pp 278-281.
- Karpinski LG, Clubb S: An outbreak of avian pox in imported mynahs. *Proc Assoc Avian Vet*, 1986, pp 35-37.
- Keymer: Parasitic diseases. In Petrak ML (eds): *Diseases of Cage and Aviary Birds* 2nd ed. Philadelphia, Lea & Febiger, 1982, pp 535-598.
- Janovski MD: Disseminated aspergillosis in a mynah bird. *J Am Vet Med Assoc* 149:944-949.
- Johnson BJ, Castro AE: Canary pox causing high mortality in an aviary. *J Am Vet Med Assoc* 189(10):1345-1347, 1986.
- Johnson KM, Riddell C: Intranuclear inclusion bodies in finches. *Can Vet J* 27:432-434, 1986.
- Lina PH, et al: Detection of virus in squamous papillomas of the wild bird species *Fringilla coelebs* (chaffinch). *J Natl Cancer Inst* 50:567-571, 1973.
- Mackerras MJ, Mackerras IM: Haematocytosis in Australian birds. *Aust J Zool* 8(2):226-265, 1960.
- Macwhirter PJ: Avian practice in Australia. *Proc Assoc Avian Vet*, 1989, pp 46-56.
- Maich R, et al: Viral papillomatosis in canaries. *Pet's Ciecia* 4(23):352-357, 5107 AGua de Oro, Cordoba, Argentina, 1988.
- Marshall R: Papova-like virus in a finch aviary. *Proc Assoc Avian Vet*, 1989, pp 203-207.
- McOrist S: Mortality in the canary in Australia. *AAV Newsletter* 5(4):97, 1984.
- McOrist S, Scott PC: Parasitic enteritis in superb lyrebirds (*Menura novae-hollandiae*). *J Wildl Dis* 25(3):420-421, 1989.
- Mitchell G, et al: Mucormycosis in canaries (*Serinus canarius*) fed damp germinated seed. *Vet Pathol* 23:625-627, 1986.
- Mawson PM, et al: A checklist of helminths from Australian birds. *Rec S Aust Mus* 19(15):219-325, 1986.
- Osterhaus AD, et al: Identification and characterization of papillomavirus from birds (Fringillidae). *Intervirology* 8:351-359, 1977.
- Page DC, et al: Leucocytozoonosis in crested oropendolas (*Psarocolius decumanus*). *J Assoc Avian Vet* 1(4):155-157, 1987.
- Pal M: *Cryptococcus neoformans* var *neoformans* and *munia* birds. *Mycoses* 32:250-252, 1989.
- Panigrahy B, Gilmore WC: Systemic salmonellosis in an African gray parrot and salmonella osteomyelitis in canaries. *J Am Vet Med Assoc* 183:699-700, 1983.
- Panigrahy B, et al: Hemorrhagic disease in canaries (*Serinus canarius*). *Avian Dis* 28:536-541, 1984.
- Perrins CM: *Intl Coun Preser Birds, The Illustrated Encyclopaedia of Birds*, Headline, 1990.
- Perry RA: Rehabilitation of Birds. *Proc 104 Post Grad Comm Vet Sci, Univ Sydney, Australian Wildlife*, 1988, pp 115-209.
- Perry RA: Skin, beak, claw and feather disorders. In Macwhirter P (ed): *Everybird, a Guide to Bird Health*. 1987, pp 98-121.
- Randall MG, et al: Hepatopathy associated with excessive iron storage in mynah birds. *J Am Vet Med Assoc* 179:1214-1217, 1981.
- Reece RL: Hepatic coccidiosis (*Eimeria* sp) in a wild magpie-lark (*Grallina cyanoleuca*). *Avian Pathol* 18:357-362.
- Reece RL, et al: Some unusual diseases of birds in Victoria, Australia. *Vet Rec* 130:178-185, 1992.
- Reinhard GR, et al: Subcutaneous salmonella granulomas in canaries. *Lab An Sci* 38:505, 1988.
- Roskopf WJ, et al: Pet avian conditions and syndromes. *Proc Assoc Avian Vet*, 1986, pp 377-400.
- Rotz A, et al: A fatal herpesvirus infection in gouldian finches (*Choebia gouldiae*). *Schweizer Archiv fur Tierheilkunde* 126:651-658, 1984.
- Sakas P: Call for information on polytetrafluoroethylene toxicity. *Assoc Avian Vet Newsletter* 6(4):102, 1985.
- Scanes CG: Pituitary gland. In Sturkie PD (ed): *Avian Physiology* 4th ed. New York, Springer-Verlag, 1986.
- Slatter DH, et al: Hereditary cataracts in canaries. *J Am Vet Med Assoc* 183(8):872-874, 1983.
- Todd KS, Hammond DM: Coccidia of Anseriformes, Galliformes and Passeriformes. In Davis JW (ed): *Infectious and Parasitic Diseases of Wild Birds*. Ames, Iowa State University Press, 1971, pp 185-233.
- van der Hage M: A bacterial proventriculitis in canaries (*Serinus canaria*). *Avian Pathol* 13(3):561-572, 1984.
- van der Hage M: Finches with disturbance of the digestive tract. *J Assoc Avian Vet* 4(2):83, 1990.
- Vogelnest L: Avian Clinical Pathology. 1. Hematology and Biochemistry. *Post Grad Comm Vet Sci, Proc 178, Avian Medicine*, 1991, pp 243-313.
- Val'kyunas GA: Some characteristics of infections with blood protozoa in passerine birds. *Lietuvos-TSR-Mokslu-Akademijos-Darbai-C-Serijai-Biologijos-Mokslai* 3:88-96, 1987.
- Van Ripper C: Discovery of *Toxoplasma* in Hawaii. *J Parasitol* 73(5):1071-1073, 1987.
- Wehr EE: Nematodes. In Davis JW (ed): *Infectious and Parasitic Diseases of Wild Birds*. Ames, Iowa State University Press, 1971, pp 185-233.
- Woods LW: Papova-like virus in a painted finch. *Proc Assoc Avian Vet*, 1989, pp 218-219.
- Worell A: Phlebotomy for treatment of hemochromatosis in two sulfur-breasted toucans. *Proc Assoc Avian Vet*, 1991, pp 9-14.