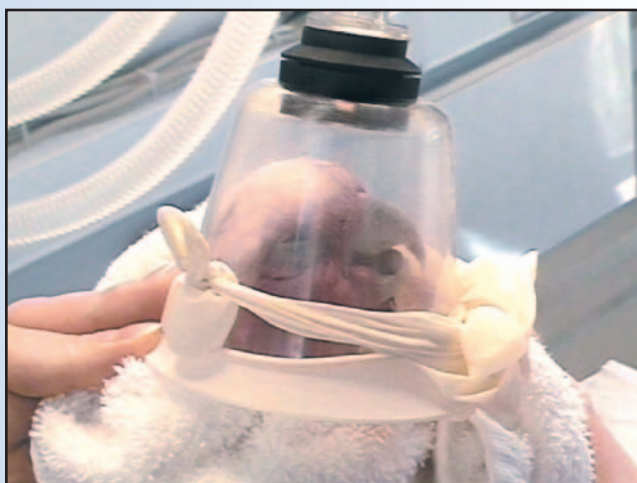

Updates in

Anesthesia and Monitoring

THOMAS M. EDLING, DVM, MSpVM



Although avian anesthesia has made significant advances in the past several years, anesthetizing a bird should never become a procedure to be taken lightly. Unlike common anesthetic procedures in mammals, birds are seldom clinically healthy when anesthesia is utilized. In addition, the anatomy and physiology of birds greatly complicates anesthetic risk. Even a procedure that lasts only 5 minutes can easily put a bird into a hypercapnic state that can be fatal. This being said, birds are now commonly being anesthetized for periods exceeding 2 hours with very little morbidity and mortality. These advances are due to the use of inhalation agents, such as isoflurane^b and sevoflurane^c, plus better monitoring techniques. The newer monitoring techniques effectively control apnea, hypothermia and hypoventilation, the most commonly experienced problems during anesthesia. As in mammals, there is no formula involving respiratory rate and tidal volume that can be employed to correctly determine the ventilatory status of the patient. The only way to accurately assess ventilation in any animal is through some measure of arterial carbon dioxide. Recent advances in avian anesthesia have shown that capnography (the continuous graphing of the carbon dioxide content of expired air) can be effectively used to monitor anesthesia in birds, and the use of intermittent positive pressure ventilators, electrocardiograms (ECG), pulse oximetry and doppler flow probes have greatly advanced the science of anesthesia in avian species.

Systems Overview

PULMONARY SYSTEM

The avian respiratory system is unique to the animal kingdom. It employs two separate and distinct functional systems for ventilation and gas exchange. The ventilatory components consist of the larynx, trachea, syrinx, intra- and extrapulmonary primary bronchi, secondary bronchi, parabronchi, air sacs, skeletal system and respiratory muscles. The gas exchange system utilizes two types of lungs, the paleopulmonic and neopulmonic. Both of these lung types rely on the parabronchi for gas exchange.

Anatomy

The oronasal cavity is separated from the trachea by the larynx, which opens into the trachea through the slot-like glottis. The larynx extends into the pharynx and attaches directly to the base of the tongue. It consists of four laryngeal cartilages: the cricoids, procricoid, and paired arytenoid cartilages.¹⁹ This is different from the mammalian larynx in that the thyroid and epiglottic cartilages are absent in birds. The functions of the larynx are to open the glottis during inspiration, aid in swallowing, modulate sound and act as a barrier to keep inappropriate matter from entering the trachea.¹⁹ This anatomy makes intubation of most companion avian species easier than mammalian intubation, as the clinician can visualize the glottis and pass the endotracheal tube with relative ease.

The trachea probably exhibits the greatest degree of variability of any of the respiratory system components. The avian trachea consists of four layers: mucous membrane, submucosa, cartilage and adventitia. The cartilaginous layer forms complete rings throughout the length of the trachea.¹⁹ The internal lining of the larynx and trachea is composed of simple and pseudostratified, ciliated columnar epithelium, with simple alveolar mucous glands and goblet cells.¹⁹

Unusual tracheal variations seen in some avian species include modifications such as an inflatable sac-like diverticulum in emus and ruddy ducks, tracheal bulbous expansions in many male Anseriformes, and the complex tracheal loops and coils located in the caudal neck, keel, thorax or a combination. Another unusual tracheal modification is the trachea is divided by a septum in the cranial portion into two tubes in some penguins, mallards and petrels.¹⁹ Most birds commonly seen in a companion avian practice do not have significant tracheal variations.

The avian tracheal modifications create significant func-

tional consequences relating to anesthesia. The most important is tracheal dead air space. The “typical” bird trachea is longer and wider than that of comparably sized mammals, which increases the tracheal dead space volume. Birds compensate for this increased dead air space volume with a deeper and slower breathing pattern.

The syrinx is the sound-producing organ in birds, located at the bifurcation of the trachea. The shape, size and location of the syrinx in the coelomic cavity vary greatly depending on species. The location and structure of the syrinx explains why an intubated bird can still produce sound. The tracheal tube does not pass through the syrinx, thus the syrinx remains functional if enough force is applied to the air sacs, as in resuscitation efforts, or if the bird vocalizes due to a light plane of anesthesia.

The avian bronchial system is composed of three structural levels.¹² The primary bronchus comprises two components: the extrapulmonary portion that extends from the syrinx to the lung parenchyma and the intrapulmonary portion, which extends throughout the length of the lung ending at the abdominal air sac. In most birds, the secondary bronchus is divided into four groups: medioventral, mediodorsal, lateroventral and laterodorsal, based on their anatomic location.²⁰

Most companion birds have nine air sacs comprised of the paired cervical, single clavicular, paired cranial thoracic, paired caudal thoracic and paired abdominal air sacs. Based on their bronchial connections, air sacs are separated functionally into two groups. The cranial group consists of the cervical, clavicular and cranial thoracic air sacs, and the caudal group comprises the caudal thoracic and abdominal air sacs. Functionally, the air sacs serve as bellows to the lung. They provide airflow to the relatively rigid avian lung during both inspiration and expiration; but, the air sacs are poorly vascularized and contribute less than 5% of the total respiratory system gas exchange.¹⁷

VENTILATION

In birds, unlike in mammals, both inspiration and expiration require muscular activity. When the inspiratory muscles contract, the internal volume of the coelomic cavity increases. Pressures within the air sacs become negative, relative to ambient atmospheric pressure, and air flows from the atmosphere into the respiratory system, across the gas exchange surfaces of the lungs and into the air sacs.¹² The reverse process occurs with contraction of the expiratory muscles: air flows from the air sacs across the gas exchange surface of the lungs and out to the atmosphere. During the resting phase, the system stops halfway between inspiration and expiration.

Gas Exchange

In the avian patient, gas exchange occurs in the parabronchus. The parabronchi are long, narrow tubes that have numerous openings into chambers termed atria. The atria have funnel-shaped ducts (infundibula) that lead to air capillaries.²⁵ The air capillaries form an anastomosing, three-dimensional network interlaced with a similarly structured network of blood capillaries where gas exchange takes place.¹²

There are two types of parabronchial tissues in the avian lung. The paleopulmonic parabronchial tissue, consisting of parallel, minimally anastomosing parabronchi, is found in all birds. The second type, neopulmonic parabronchi tissue, is a network of anastomosing parabronchi located in the caudolateral portion of the lung.²⁵ Penguins and emus have only paleopulmonic parabronchi. Pigeons, ducks and cranes have both types of tissues, with the neopulmonic parabronchi accounting for 10 to 12% of the total lung volume in these species.¹² In songbirds and parrots, the neopulmonic parabronchi are more developed and may account for 20 to 25% of the total lung volume.

During inspiration and expiration, the direction of gas flow in the paleopulmonic parabronchi is unidirectional, whereas the direction of gas flow in the neopulmonic parabronchi is bi-directional. A process involving aerodynamic valving controls the direction of gas flow through the intrapulmonary primary bronchus, secondary bronchi and the paleopulmonic parabronchi.²⁶

The gas exchange system in the avian parabronchi is best described with a crosscurrent model. In this system, parabronchial gas is constantly changing in composition as it flows along the length of the lung. The degree to which capillary blood is oxygenated and carbon dioxide is eliminated depends on where the blood contacts the blood-gas interface. Another important note in this crosscurrent design is that it is not dependent on the direction of gas flow. Gas exchange occurs equally well with gas flow originating from either end of the parabronchus.

The respiratory gas volume per unit body mass of the avian respiratory system is 2 to 4 times that of a dog. Although the volume of gas in the parabronchi and air capillaries is only 10% of the total specific volume in birds, in the mammalian lung it is 96%. This results in a small functional residual capacity (FRC) in birds and makes periods of apnea critical. Without airflow through the lungs, gas exchange does not occur and the physiological acid-base balance maintained by the respiratory system is made ineffective. Apneic episodes will cause

significant problems during anesthesia and must be carefully managed.

Control

The control of ventilation in birds is complex and poorly understood. In both birds and mammals, respiration originates as a rhythmic motor output from the central nervous system. Reflexes, in response to changes in activity and the environment, modulate the basic rhythm. Birds also possess central and arterial chemoreceptors involved in ventilatory control. Central chemoreceptors respond to changes in the partial pressure of arterial carbon dioxide (PaCO_2) and pH, while arterial chemoreceptors are sensitive to changes in the partial pressure of arterial oxygen (PaO_2), PaCO_2 and pH. These arterial receptors account for the ventilatory response to hypoxia in birds and mammals. In addition, birds have a unique group of receptors, termed intrapulmonary chemoreceptors (IPCs), located in the parabronchial mantle. IPCs are acutely sensitive to CO_2 and insensitive to hypoxia, and affect the rate and depth of breathing on a breath-to-breath basis.

CARDIOVASCULAR SYSTEM

The avian heart is a four-chambered muscular pump very similar in function and physiology to that of mammals. In contrast, birds have a proportionally larger heart, larger stroke volume, lower heart rate, higher blood pressure and a higher cardiac output than comparably sized mammals.³⁰ Birds also possess both right and left cranial vena cavae, their aorta arches to the right and they have a tricuspid (right AV) valve with a single leaf. Sympathetic and parasympathetic nerves innervate the atria and ventricles.³⁰

The main cardiac sympathetic neurotransmitters are norepinephrine and epinephrine.³⁰ Excitement increases the concentration of these neurotransmitters, especially epinephrine, which has significant implications because inhalant anesthetics, especially halothane, sensitize the myocardium to catecholamine-induced cardiac arrhythmias. Hypoxia, hypercapnia and anesthetics each depress cardiovascular function.

The conduction system of the avian heart consists of the sinoatrial node, the atrioventricular node and its branches, and Purkinje fibers.³⁰ Birds have type 2 Purkinje fibers that completely penetrate the ventricular myocardium. Ventricular activation appears to originate from both the endocardium and epicardium and vice versa, an adaptation thought to facilitate synchronous beating at high heart rates.

Special Considerations

AIR SACS AND POSITIONING

Air sacs in birds, as previously discussed, do not contribute significantly to gas exchange, and therefore do not play a major role in the uptake of inhalation anesthetics, nor do they accumulate or concentrate anesthetic gases.

The position of the patient during anesthesia can alter ventilation. While a bird is in dorsal recumbency, normal ventilation is reduced. This is primarily due to the weight of the abdominal viscera compressing the abdominal and caudal thoracic air sacs, and reducing their effective volume. While in dorsal recumbency, adequate ventilation can be achieved through the use of intermittent positive pressure ventilation (IPPV).

Because of the flow-through design and the crosscurrent gas exchange in the avian respiratory system, it is possible to provide inhalation anesthetics from either the trachea via the glottis or a cannulated air sac. Cannulation also offers an effective means to ventilate an apneic bird or patient with an obstructed trachea.

DIVE RESPONSE

In some birds, especially waterfowl, episodes of apnea and bradycardia can occur during induction of anesthesia due to a physiologic response termed a dive response. It is thought to be a stress response mediated by stimulation of trigeminal receptors in the beak and nares. It can be elicited simply by placing a mask snugly over a bird's beak without anesthetic gas involvement. The dive response usually happens during the initial phase of induction of gas anesthesia with a mask. If the dive response occurs, turn off the anesthetic gas, remove the mask from the bird's head and provide oxygen to the bird's beak via open anesthetic mask until the bird has recovered.

INTERMITTENT POSITIVE PRESSURE VENTILATION

Providing manual IPPV during inhalation anesthesia is a tried-and-true method for maintaining an animal in a normal physiologic state. The next step in the progression of avian anesthesia is the use of mechanical ventilators to provide IPPV. Mechanical devices can provide a much greater consistency in this effort and free the clinician or technician for other critical duties during surgical procedures. There are two types of assisted ventilation machines — volume-limited and pressure-limited. The volume-limited delivers a set tidal volume, regardless of airway pressure, and the pressure-limited delivers a tidal volume until a predetermined airway pressure is

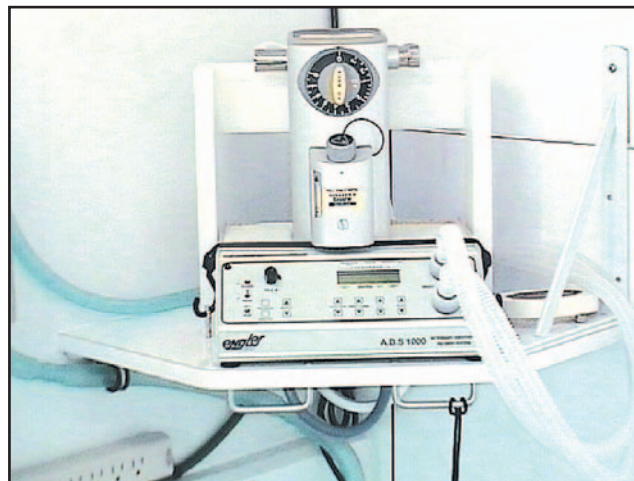


Fig 33.1 | Sevoflurane vaporizer^a mounted to the ADS (anesthesia delivery system) 1000 mechanical ventilator. The ventilator allows mask induction, and then changes to an endotracheal tube with the flip of a switch.

reached. In pressure-limited ventilation, if the airway becomes occluded, the machine will deliver a lower tidal volume for the same airway pressure. Similarly, changes in lower respiratory compliance over time may alter tidal volume at a given pressure. Thus, gradual hypoventilation may result without the operator becoming aware. In contrast, if the endotracheal tube becomes occluded during pressure regulated volume-limited ventilation, the resulting high airway pressure triggers an alarm that will alert the operator. If the system leaks, gradual hypoventilation may develop due to a loss of a portion of each tidal volume.

Use caution when using all ventilators during surgical procedures in the coelomic cavity, where there is a large opening in an air sac. Because volume-limited ventilators deliver only a preset volume of anesthetic gas, it is almost impossible to control ventilation and anesthesia because most of the anesthetic gas leaks from the opening in the air sac. Although difficult, it is possible to control ventilation under the same circumstances with a pressure-limited ventilator because this type of system will continue to supply anesthetic gas until the preset pressure is achieved. There will be continuous flow from the ventilator through the respiratory tract if there is a large rent.

Pressure- and volume-limited ventilation machines are commonly used in veterinary practice, and manufacturers offer mechanical ventilators designed specifically for small or laboratory animals. These machines are excellent choices for avian anesthesia (**Fig 33.1**).

It has been hypothesized that it is possible to reverse the direction of gas flow within the avian lung during PPV. Because the crosscurrent gas exchange system is not

dependent on the direction of flow, a reversal of gas flow will not adversely affect gas exchange.⁹

General Considerations

HISTORY

A complete and thorough history, obtained from the bird's owner, is perhaps the most important information one can acquire prior to anesthesia. The history will provide invaluable information concerning husbandry issues and events that will lead you toward specific concerns. Observant owners will recognize changes in their bird's behavior prior to the clinical manifestation of disease. The history should include all parameters concerning husbandry. These include cage size, cage construction, cage grate, substrate, cage location, perches, toys, food/water bowls, other animals in the household, exposure to other birds (boarding, visits, bird club meetings, etc), exposure to toxins, supervision, changes in household, cleaning (agents used, frequency, etc), and vaccination history, to name a few pertinent factors.

PHYSICAL EXAMINATION

After obtaining the history, quietly observe the bird as it perches in its cage. Watch for signs of awareness and attention to its surrounding environment, body position, feather condition, and respiratory rate and depth. After the initial observations, a thorough physical examination should be performed. Remove the bird from its cage and examine it for any abnormalities. Special attention should be given to the nares, oral cavity, choanal slit, glottis, abdomen, cloaca and muscle mass covering the keel. The heart, lungs and air sacs should be auscultated for signs of disease. Observation of the bird's respiratory rate and depth after handling, when the bird is back on its perch, also provides valuable information on the respiratory condition of the patient. If the physical exam, history or other parameters warrant, blood should be collected for evaluation. Refer to Chapter 6, Maximizing Information from the Physical Examination.

ACCLIMATION

Placing a bird into a new or different environment is usually a stressful situation. When a bird is stressed, it generally will attempt to hide any signs of illness. This can make observing the bird for signs of infirmity difficult. If time and physical parameters allow, acclimating the bird prior to anesthesia can help. If the bird does become acclimated to the new environment, signs of disease that were masked while the bird was stressed may become evident, but they can rarely hide respiratory distress.

It also is possible that the patient will not become acclimated to the new surroundings during the period of time allowed. In these cases, the bird's stress level will elevate and its disease state may worsen. The bird may refuse to eat and drink, and will need to be given supportive care. When managing the highly stressed bird, it is best to bring it into the clinic as closely as possible to the time of anesthesia, while still allowing time for a complete physical evaluation. Preliminary testing such as blood work can be done prior to the day anesthesia will be performed.

FASTING

Ensuring that the crop is empty prior to anesthesia is very important due to the hazards associated with regurgitation. There is controversy as to the length of time a bird should be fasted prior to induction. Because of a bird's high metabolic rate and poor hepatic glycogen storage, it has been recommended that fasting be limited to no more than 2 to 3 hours. However, when working with cockatiel-sized and larger birds in good physical condition, removing their food the night before and their water 2 to 3 hours prior to anesthesia does not appear to be harmful.⁷ Always palpate the crop before anesthesia. If there are residues, especially liquid, they can be aspirated prior to anesthesia.

RESTRAINT

The use of proper physical restraint is important in the management of avian patients. Improper capture or restraint can result in serious physical trauma such as fractures, lacerations and dislocations. Owners will judge the veterinarian's clinical abilities on how their bird looks after its visit. Birds must be restrained so that the legs and wings are not allowed to flail. In psittacine restraint, the head must be controlled at all times. In species such as macaws with bare cheek patches, restraining the bird by placing your fingers on these cheek patches can cause bruising, which inevitably will cause the owners to lose confidence in your abilities. Each avian species has its own unique defense mechanism that needs to be addressed to ensure proper restraint. The beak of a parrot can cause significant soft tissue injury and its feet can inflict painful scratches. Birds of prey use their talons as their defense mechanism. Their feet must be carefully restrained or serious injury will result. Although most raptors do not bite as a general rule, great horned owls can use their beaks very effectively. Cranes and herons typically use their long, pointed beaks to attack the eyes of their handlers.

The most common method of restraint is a soft, tightly-woven towel appropriately sized to be able to encircle the patient. The bird is carefully grasped through the



Fig 33.2 | Non-rebreathing circuit. The non-rebreathing anesthesia circuits allow for the removal of CO₂ with high oxygen flow (100-200 ml/kg/minute). This type of circuit also is capable of almost instantaneous changes in the percentage of anesthetic gas delivered to the patient when the vaporizer settings are adjusted.

towel, being careful to control the animal while allowing the sternum freedom of movement for respiration. The animal can either be left in the towel or removed from the towel, depending on the skill and comfort level of the clinician or technician restraining the bird. When using a towel for restraint during an examination it is easy for a bird to become hyperthermic, so be careful to monitor the patient for signs of overheating. During a physical exam, a bird of normal weight will start to pant if wrapped in a towel for more than 5 minutes; therefore, obese birds should be examined within 1 to 2 minutes.

Inhalant Anesthetics

BREATHING CIRCUITS AND GAS FLOW

Non-rebreathing circuits such as Magill, Ayre's T-piece, Mapleson systems a-f, Jackson-Rees, Norman mask elbow and Bain circuit are typically used during companion bird anesthesia. These systems rely on a relatively high fresh gas flow rate to remove carbon dioxide. They offer advantages over a rebreathing circuit such as an almost immediate response to vaporizer setting changes and a lower resistance to breathing. Oxygen flow in a non-rebreathing circuit should be 2 to 3 times the minute ventilation or 150 to 200 ml/kg per minute²³ (Fig 33.2).

INDUCTION METHODS

Mask induction techniques are used with companion birds in most circumstances. The masks can range from commercially available small animal masks to plastic bottles and syringe cases (Fig 33.3). The size and shape of



Fig 33.3 | Standard small-mammal face masks with latex gloves fitted across the openings, producing tight-fitting induction masks. The hole should be slightly smaller than the neck size of the animal being induced, and the animal's head should fit completely inside the mask. When fitted correctly, it is possible to provide intermittent positive pressure ventilation in some circumstances.

the mask is dependent upon the size and shape of the bird's head and beak. The mask should be stable and as small as possible. Eye lubrication should be administered at this time. During induction, the entire head of the bird should be placed inside the mask, being careful not to cause eye and beak damage.

A disposable latex glove can be placed over the mask opening with a central hole cut for insertion of the head. The hole should be roughly the same size as the bird's neck (Fig 33.4). When fashioned properly, the glove will provide a seal around the patient's neck tight enough to allow for positive pressure ventilation. The tight seal also helps reduce the amount of waste gas released into the environment (Fig 33.5). Too tight of a seal may occlude major vessels.

Other methods of induction have been successfully used. Clear plastic bags can be used to completely enclose a cage and induce anesthesia for patients that are difficult to control. Anesthetic chambers also have been used for induction. Both of these techniques can be effective, but have their disadvantages. The anesthetist cannot physically feel how the bird is responding during induction or have the ability to auscultate the animal using these methods. In addition, the bird can injure itself when not being restrained during the excitement phase of anesthesia.

Several induction techniques have been described in the literature,¹ including the use of preoxygenation techniques and slowly increasing the concentration of the gas anesthetic agent until the desired effect has been attained. This method does induce anesthesia, but has the disadvantage of taking longer to achieve a loss of



Fig 33.4 | Induction masks can be made from a variety of existing articles such as plastic bottles, syringe cases, pill containers and plastic containers. Only the shape of the animal's head and your imagination limit the variety of induction masks.

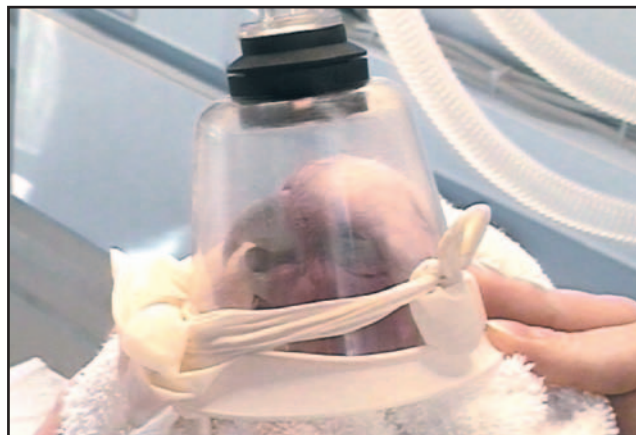

Fig 33.5 | Mask induction of a rose-breasted cockatoo. Note that the head is completely enclosed in the mask and the opening of the mask is covered with a latex glove.

consciousness and may increase the excitement level of the patient. The most common method is to simply place the induction mask over the head of the bird with a high oxygen flow rate (1-2 L/minute), adjust the anesthetic vaporizer concentration to a high concentration (depending on the anesthetic agent, 4 to 5% for isoflurane^b, 7-8% for sevoflurane^c, individual setting is necessary) and securely restrain the bird for the few seconds it takes to achieve induction. The vaporizer setting is then reduced to a setting near the minimum anesthetic concentration (MAC). When performed correctly, this method reduces the induction time and stress level on the bird.

INTUBATION

When short (10 minutes or less), non-invasive procedures such as radiography, blood collection, and physical examinations are to be performed, intubation is usually not necessary. If the procedure is to be invasive or longer than 10 minutes, intubation of the patient can be crucial.

Most birds 100 g in body weight and larger can be intubated with minimal difficulty. It is possible to intubate birds as small as 30 g in body weight, but they present a much greater challenge. In these smaller birds, an endotracheal tube can be fashioned using a red rubber catheter of an appropriate diameter (**Fig 33.6**). Some birds have unique anatomical features, such as the ventral crest in some hornbills and median tracheal septum in some penguins, which can interfere with intubation. In psittacine birds, intubation can be difficult because the glottis is located at the base of the fleshy tongue.

Care must be taken during intubation to ensure that the trachea is not damaged. The endotracheal tube should provide a good seal with the glottis, but should not fit tightly. If the tube is cuffed, the cuff should not be inflated or should be inflated with tremendous care. An over-

inflated cuff can cause damage to the tracheal mucosa because of the complete cartilaginous rings. Tracheal damage may not become apparent for several days following intubation, when the bird presents with dyspnea due to a stricture in the lumen of the trachea.

The most common problem associated with intubation of companion birds is airway obstruction. Small endotracheal tube diameters and cold, dry gases increase the probability of a complete or partial airway obstruction. As the airway becomes occluded, the expiratory phase of ventilation is prolonged.¹² The obstruction can be corrected by extubating the patient and cleaning the endotracheal tube. Positive pressure ventilation, even during spontaneous breathing, can help prevent the formation of endotracheal mucus plugs, even in the smallest patients.

Once the patient is intubated, the endotracheal tube should be securely attached to the lower beak. This will help prevent the endotracheal tube from becoming dislodged while preparing the bird for the procedure and also will help reduce the likelihood of tracheal damage (**Fig 33.7**). Another important aspect to address at this juncture of the procedure is caring for the patient's eyes. The eyes of most companion birds are prone to physical damage, since they protrude from their heads. A method to help reduce eye damage is to provide a ring of soft material to encircle the eye that is going to be closest to the table. An eye lubricant also should be administered at this time.

ANESTHETIC POTENCY

Anesthetic potency can be expressed in many ways. One method is to assess the MAC of the inhalation anesthetic during surgical anesthesia. The MAC is generally defined as the minimum alveolar concentration of an anesthetic that produces no response in 50% of patients exposed to




Fig 33.6 | Examples of endotracheal tubes. Cole and red rubber catheter endotracheal tubes can be fashioned for smaller patients.

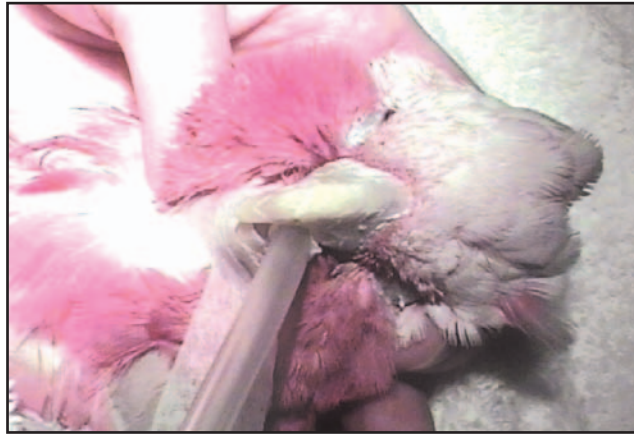


Fig 33.7 | Intubation of the bird in Fig 33.5 with a modified Cole endotracheal tube. Notice that the endotracheal tube is taped to the lower beak to help avoid damaging the trachea and to allow for a better seal with the glottis.

painful stimulus. MAC values are measured as the end-tidal concentration of anesthetic and are not vaporizer settings. In birds, the term MAC is not appropriate because birds do not have an alveolar lung. It has been suggested that in avian species, MAC be defined as the minimum anesthetic concentration required to keep a bird from purposeful movement to a painful stimulus.¹³ The MAC for isoflurane^b in cockatoos, ducks, and Sandhill cranes is 1.44%,¹² 1.32%¹⁵ and 1.35%,⁹ respectively.

Another method of comparing anesthetic agents is by their ability to cause respiratory depression and apnea in an animal. The Anesthesia Index (AI) can predict this effect: the lower the AI, the greater the chance of apnea. The AI for isoflurane^b in dogs, cats, horses and ducks is 2.51,²⁹ 2.40,²⁹ 2.33²⁸ and 1.0¹⁵ respectively. These values indicate that isoflurane^b depresses ventilation more in birds than in mammals.

INHALATION AGENTS

Inhalation anesthetic agents are used to produce general anesthesia. Their safe use requires knowledge of their pharmacologic effects and physical and chemical properties. Anesthetic doses required for surgery produce unconsciousness (hypnosis) and hyporeflexia. With unconsciousness (no response) all pain physiologically still occurs. Inhalation anesthetics provide optimal control of anesthesia, rapid induction and recovery from anesthesia, and relatively few adverse side effects.²¹

There are two agents currently used for inhalation anesthesia by most avian practitioners, isoflurane^b and sevoflurane^c. A third agent, desflurane, recently has become available, although due to its specialized vaporizer and pungent odor it is doubtful whether it will ever become a commonly used anesthetic agent in avian practice. However, even with the relative high cost of sevoflurane,

it quickly is becoming the inhalation anesthetic agent of choice for companion avian practitioners. All three of these inhalation anesthetic agents produce dose-dependent central nervous system, respiratory and cardiovascular effects.

Isoflurane^b currently is the preferred choice for avian anesthesia due to its low relative cost, comparatively rapid induction and recovery, low blood solubility and minimal metabolism. In addition, it does not sensitize the heart to catecholamine-induced arrhythmias.²²

Sevoflurane also has been shown to be an excellent anesthetic agent, as it has a lower blood gas partition coefficient than isoflurane^b (sevoflurane^c = 0.69, isoflurane^b = 1.41) and is therefore less soluble in blood, although it is less potent (MAC 2-3%). This decreased solubility accounts for the shorter recovery time and time to standing with sevoflurane compared with isoflurane^b.⁸ In critical or prolonged surgical procedures, the use of sevoflurane^c can help increase the chance of a successful outcome due to the faster recovery time when compared to other inhalation anesthetics. In addition, sevoflurane does not cause respiratory tract irritation, as do isoflurane^b and desflurane^d, and therefore reduces the stress involved with mask induction.

Desflurane^d is a less potent (MAC 6-8%) anesthetic agent that requires a specialized temperature-controlled and pressurized vaporizer to accurately deliver the anesthetic agent to the patient. It has the lowest blood gas partition coefficient (0.42) of the three agents and tissue solubility (desflurane^d and sevoflurane^c blood-brain tissue coefficient = 1.3 and 1.7, respectively).⁷ These physical attributes provide for a faster recovery time than those of isoflurane^b and sevoflurane^c, especially after prolonged anesthetic procedures. In humans, the pungency of desflurane^d caused respiratory tract irritation, cough-

ing, breath holding and laryngospasms, and thus is not used for mask inductions.⁷

Even when using these reliable anesthetic agents, anesthesia remains risky because it depresses ventilation at concentrations required for surgery.¹³ Specifically, as the concentration of isoflurane^b increases, the PaCO₂ increases, which manifests clinically as a respiratory acidosis.¹³

Halothane is no longer considered to be a safe and reliable anesthetic agent in avian species. As in mammals, halothane sensitizes the heart to catecholamine-induced cardiac dysrhythmias. Fatalities due to pre-existing high levels of circulating catecholamines in stressed birds have been associated with halothane.

Injectable Anesthetics

There are many inherent disadvantages associated with the use of injectable anesthetic agents, the most notable being significant species variation, cardiopulmonary depression, prolonged and violent recoveries, and the difficulty involved in delivering a safe and effective volume.¹² The advantages of injectable anesthesia are few and are mostly related to cost and ease of administration. The disadvantages significantly outweigh the advantages in all but the most severe situations, such as field conditions where inhalant anesthesia is not feasible. See Chapter 1, Clinical Practice for a field anesthesia setup. If the decision is made to use injectable anesthesia in companion avian species, the clinician should realize that most of the positive attributes associated with inhalation anesthesia cannot be exploited. When using any of the injectable anesthetic agents, it is advisable to intubate the patients and monitor their physiologic state as if they were undergoing general inhalation anesthesia. Also, an I.V. catheter should be in place for rapid vascular access for fluid therapy and pharmaceuticals

PREANESTHETICS

Parasympatholytic Agents

The use of routine parasympatholytic agents in avian species, as in mammals, is no longer thought to be necessary and is, in fact, counterproductive in most circumstances. Parasympatholytic agents (atropine and glycopyrrolate) in avian species exacerbate thickening of salivary, tracheal and bronchial secretions, and increase the risk for airway obstruction.

Tranquilizers

Tranquilizers such as diazepam and midazolam are benzodiazepines that have excellent muscle relaxant properties. They lack analgesic properties whether used alone

or in combination with primary anesthetics such as ketamine. I.V. diazepam can be used to tranquilize a bird prior to mask induction with an inhalant anesthetic, thus reducing the stress involved with the procedure.¹² Uptake of diazepam is slow and unpredictable with I.M. injection. An important feature of diazepam, in contrast to midazolam, is its shorter duration of action leading to a shorter recovery time. Midazolam is more potent and longer lasting than diazepam, and does not adversely affect mean arterial blood pressure and blood gases in select avian species. I.M. uptake is rapid and almost complete. When midazolam is given to geese, raptors and pigeons, the effects last for several hours after the termination of anesthesia, which can be undesirable.³¹

Alpha-adrenergic Agents

Xylazine, medetomidine and other related alpha₂-adrenergic agonists have sedative and analgesic properties. They can have profound cardiopulmonary effects including second-degree heart block, bradyarrhythmias and increased sensitivity to catecholamine-induced cardiac arrhythmias. When used alone in high doses, xylazine is associated with respiratory depression, excitement and convulsions in some species.¹² Hypoxemia and hypercapnia were observed in Pekin ducks (*Anas domestica*) given xylazine, and a combination of xylazine and ketamine.¹⁴ When used in combination with ketamine, the sedative and analgesic effects of xylazine are enhanced. One positive aspect of this class of drug is that an overdose or slow recovery can be treated with an alpha-adrenergic antagonist reversal agent such as yohimbine or atipamezole.

Opioids

Opioids are commonly used as a premedication in small mammal medicine, both for presurgical analgesia and to reduce the amount of inhalation anesthesia necessary to achieve a surgical plane. In pigeons, it appears that the kappa opioid receptors account for the majority of the opioid receptor sites.¹⁸ Thus butorphanol, a kappa agonist, may be a better analgesic than mu opioid agonists. In addition, it has been demonstrated that butorphanol reduces the concentration of isoflurane^b necessary to maintain anesthesia in cockatoos.³ Please refer to Chapter 8, Pain Management for a comprehensive assessment of analgesia in avian species.

In a recent study it was found that the administration of hydromorphone to healthy dogs undergoing elective ovariohysterectomy or castration may result in transient increases in PaCO₂ postoperatively, and that the administration of hydromorphone or butorphanol may result in transient decreases in PaO₂; however, the increases and decreases were mild and within reference limits.² Due to

the unique physiology of avian species, it is possible that the postoperative increases in PaCO₂ and decreases in PaO₂ due to the administration of opioids may be more pronounced. More study in this area is necessary to reach a conclusion.

Local Anesthetics

Local anesthetics are an excellent tool for preemptive analgesia in avian species. However, local anesthetics do not provide any relief from the stress involved with the restraint and handling of the awake bird.

It has been demonstrated in humans and animals that pain is easier to prevent than to treat. In fact, it has been shown that the repeated stimulation of the neurons that mediate nociception in the dorsal horn of the spinal cord can cause them to become hypersensitized. The morphology of these neurons actually changes and becomes “wound up,” and as a result, the response to subsequent incoming signals is changed. The neuronal hypersensitivity continues even after the noxious stimulus stops and can last 20 to 100 times longer than the original stimulus.³² The technique of administering a preoperative local anesthetic to block the transmission of noxious stimuli can prevent or attenuate the “windup.” This procedure is especially effective for painful procedures such as amputations, fracture repairs and coelomic surgeries. However, when using local anesthetic agents, care must be taken not to induce seizures or cardiac arrest with an overdose. One common method to ensure the correct dosage is to calculate the maximum safe dose and, if necessary, dilute it to a more convenient volume for administration. See Chapter 8, Pain Management for an indepth review of local anesthetic.

In summary, local anesthetic agents should be used primarily as an adjunct to general anesthesia in helping to prevent “windup.” In general, they should not be used for local anesthesia in an awake bird due to the high levels of stress involved with handling and restraint, except in rare circumstances where a companion bird is not overly stressed and the procedure is simple such as in the case of a broken toenail.

General Anesthetics

Ketamine hydrochloride, a cyclohexamine, produces a state of catalepsy and can be given by any parenteral route. When used alone, ketamine is suitable for chemical restraint and moderate analgesia for minor surgical and diagnostic procedures, but is not suitable for major surgical procedures.¹⁴

Ketamine is generally used in conjunction with other drugs such as diazepam or xylazine to improve the quality of the anesthesia by providing more muscle relax-

ation or increased analgesia. There appears to be significant species variation when using ketamine in birds. For example, in several raptor species and waterfowl, the commercially available form of ketamine induced poor-quality chemical restraint and anesthesia.¹⁴

Propofol is a substituted phenol derivative developed for intravenous induction and maintenance of general anesthesia. Its major advantage is that it has a rapid onset and recovery, and thus has very little residual or cumulative effect. Its major disadvantage is its dose-dependent cardiovascular and respiratory depression¹⁶ (see Chapter 8, Pain Management).

Patient Monitoring

Monitoring the avian patient during anesthesia is the most critical aspect of the process. The bird must be maintained and monitored correctly, and appropriate responses to the animal's physiologic state performed in a timely fashion.

Apnea, hypoventilation, hypothermia and regurgitation are the most common problems experienced during anesthesia and, because of the bird's small FRC, periods of apnea are critical. Without adequate airflow through the lungs, gas exchange does not occur and the physiologic acid base balance maintained by the respiratory system is made ineffective.

RESPIRATORY SYSTEM

Both the respiratory rate and tidal volume should be monitored during anesthesia to help assess the adequacy of ventilation. These parameters can be supervised by observing the respiratory rate and pattern and auscultating the coelomic cavity. But, there is no formula involving respiratory rate and tidal volume that can be employed to correctly determine the ventilatory status of the patient. The only way to accurately assess ventilation in an animal is through some measure of arterial CO₂.

One study in African grey parrots (*Psittacus erithacus*) suggests that capnography can be effectively used to monitor arterial CO₂. The study indicates that the End Tidal Carbon Dioxide (ETCO₂) consistently overestimates arterial CO₂ by approximately 5 mmHg.⁴ When using capnography in avian patients, a side stream capnograph should be utilized and the dead air space associated with the endotracheal tube must be minimized. The capnograph can be connected to the breathing circuit through an 18-gauge needle inserted into the lumen of the endotracheal tube adapter (Figs 33.8, 33.9). It is imperative that the needle does not obstruct the lumen of the endotracheal tube.

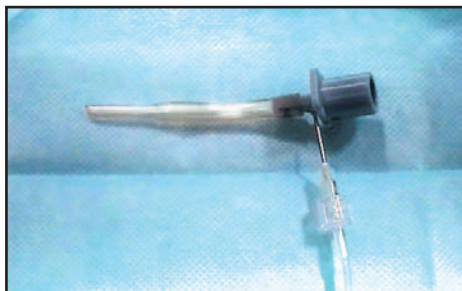


Fig 33.8 | Cole endotracheal tube shortened to reduce dead air space. The endotracheal tube adapter has been modified to allow the attachment of a side stream capnograph. This has been accomplished by mounting an 18-ga needle into the lumen of the adapter with the needle bevel facing the patient.




Fig 33.9 | Example of a red rubber catheter with the endotracheal tube adapter modified to allow side stream capnography on a cockatiel.

Positive pressure ventilation through the use of a mechanical ventilator or by manual compression of the reservoir bag can be used to effectively maintain the avian patient during inhalation anesthesia. During positive pressure ventilation, airway pressures should not exceed 15 to 20 cm H₂O to prevent volutrauma to the air sacs. When using positive pressure ventilation, adjust the ventilations per minute mechanically or manually according to the ET CO_2 , striving to maintain the patient within normal physiologic ranges. A guideline that can be used with some caution was found in studies with African grey parrots. An ET CO_2 of 30 to 45 mmHg indicated adequate ventilation during inhalation anesthesia in African grey parrots.⁴

CIRCULATORY SYSTEM

The heart can be monitored through a number of noninvasive methods such as pulse, auscultation and an electrocardiogram (ECG). Monitoring the pulsations of blood through a peripheral artery can assess heart function. The Doppler flow probe^c is an effective means to monitor pulse rate and rhythm. Standard bipolar and augmented limb leads can be used to monitor and record the ECG, which reports the electrical activity of the heart. The ECG must be able to detect and accurately record the high heart rates (up to 500 bpm) associated with avian species. A new technique to obtain ECG readings is through the use of an esophageal probe^f (Figs 33.10, 33.11). The probe is inserted into the esophagus of the patient and attached to the standard ECG via an adapter (Figs 33.12, 33.13). This technique achieves accurate readings and eliminates the need for attaching leads to the limbs. It is difficult to directly measure arterial blood pressure in psittacine birds due to their small size, the invasiveness of the procedure and the cost of the equipment.

CENTRAL NERVOUS SYSTEM

Eye reflexes, jaw tone, cloacal reflex, pedal reflex and muscle relaxation can be used to assess avian patients during anesthesia. One study described the ideal anesthetic level as when the patient's eyelids were completely closed, pupils mydriatic, the pupillary light reflex was delayed, the nictitating membrane moved slowly over the entire cornea, the muscles were all relaxed and all pain reflexes were absent.¹⁰ Breathing depth and frequency are the best manual assessment tools.

OXYGENATION

Ensuring that an adequate PaO₂ is present in a patient's arterial blood is very important. An intubated bird on 100% oxygen during inhalation anesthesia is usually well oxygenated. Problems such as apnea, ventilation perfusion mismatch and tracheal obstructions can significantly alter the partial pressure of arterial oxygen. The only accurate method for determining a patient's arterial oxygen status is through arterial blood gas analysis. Mucous membrane color can be used to monitor change but is not effective in a critical patient. Studies using pulse oximetry indicate that while it is a valuable tool for assessing mammalian oxygen saturation, it is not consistently accurate on avian patients²⁷ (Fig 33.14). It is very important that the anesthetist be careful not to interpret sufficient oxygenation as being adequately ventilated. Birds can be well oxygenated and at the same time be extremely hypercapnic.⁶ PaO₂ is not a reliable indicator of the ventilatory status of a bird or any other animal.

TEMPERATURE

Studies show that without thermal support anesthetized birds rapidly lose heat. The flow of dry anesthetic gases through the respiratory system, removing feathers for sterile skin preparation, surgical skin preparation liquids,



Fig 33.10 | Patient with a companion ECG probe^f (green line).

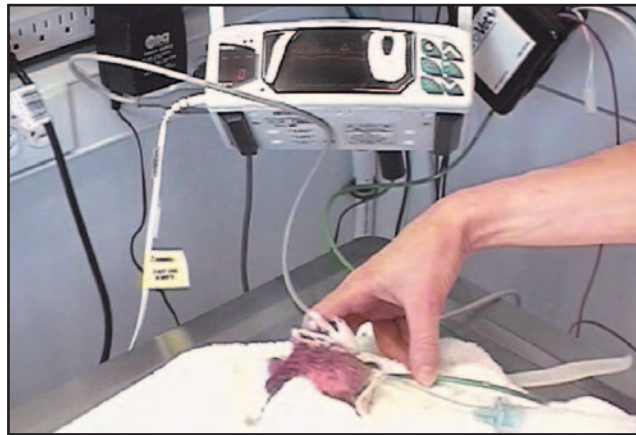


Fig 33.11 | Overview of the patient attached to the companion ECG probe connected to the combination ECG and pulse oximetry monitor^f. Notice the adapter box to the right of the monitor (black box). The adapter allows standard ECG leads to connect to the esophageal ECG probe.



Fig 33.12 | ECG probe^f with adapter. This adapter box connects standard ECG leads to the esophageal probe.



Fig 33.13 | ECG probe^f. This probe is inserted into the esophagus of the patient and eliminates the need of attaching separate ECG leads.

blunted physiologic responses to the reduction in body temperature, the small body mass in relation to the surface area and many other factors all serve to quickly reduce a bird's body temperature during anesthetic procedures. Hypothermia is the most common problem associated with prolonged anesthesia, as it decreases the requirement of anesthetic, and it also causes cardiac instability and prolongs recovery. Hypothermia also is significant after anesthesia because hypothermic patients must then use critical energy reserves to generate heat by shivering. There are many methods for ensuring that a bird's body temperature does not drop significantly during anesthesia, including a circulating water blanket, heated surgery tables, warm towels, warm IV fluids and warm air blankets. When using warm air blankets, be certain to keep the patients' eyes well lubricated, as these devices tend to dry out the animals' eyes. The most effective method for providing heat during anesthesia appears to be from providing an external heat source.²⁴ Korbel showed that medical oxygen has no moisture content and this caused evaporation from the

mucous membranes, dropping body temperature. If he warmed that oxygen and added moisture, he got negligible body temperature loss during anesthesia.^{9,10}

Recent research has demonstrated that forced-air warming systems^k more effectively minimize hypothermia in avian patients while undergoing inhalant anesthesia than the traditional thermal devices (eg, circulating water blankets and infrared heat emitters) (Tully, T. unpublished data, 2001).

Temperature can be reliably monitored with a long, flexible thermistor probe inserted into the esophagus to the level of the heart. Cloacal temperature monitoring can be accurate, but is dependent on body position and cloacal activity over time.

Anesthetic Emergencies

Emergency situations arising from anesthesia no longer



Fig 33.14 | Several manufacturers offer combination anesthesia monitoring equipment such as this pulse oximeter and ECG instrument^f.

occur as frequently as in the past. It is now common to perform anesthesia on a psittacine bird for 2 or more hours and have a low incidence of morbidity and mortality. This is primarily due to the advances in the practitioner's ability to monitor and maintain the patient within its normal physiologic parameters. Although emergencies are not common, emergency drugs should be prepared and available prior to anesthesia.

COMMON EMERGENCY TREATMENTS

- **Doxapram^g** - Positive inotrope, direct action on respiratory centers in the medulla, stimulates ventilation.
- **Isotonic Crystalloid** - Hypotension: Expand blood volume and increase tissue perfusion.
- **Epinephrine HCl^h** - Positive inotrope, initiates heartbeats, increases heart rate and cardiac output.
- **Atropineⁱ** - Parasympatholytic effects, may correct supraventricular bradycardia or a slow ventricular rhythm by stimulating supraventricular pacemakers.

Recovery

Recovering the patient following inhalation anesthesia is usually a rapid process once the anesthetic gas is turned off. Disconnect the bird from the anesthetic circuit and flush the circuit with fresh oxygen. Reconnect the bird

to the circuit and continue the recovery with the patient on 100% oxygen.

Most birds will initially experience muscle fasciculations as they become lighter. If the bird is being auscultated at this time, the heart sounds will become less audible due to the muscle movement.⁴ Care should be taken not to incorrectly interpret this as a deep plane of anesthesia. This is especially important during surgical procedures. As the bird becomes lighter, more apparent movements such as wing flutter and leg withdrawal will become evident. When the patient starts exhibiting jaw movement, it should be extubated to keep it from severing the endotracheal tube. The bird should be held lightly in a towel in an upright position once extubated. Wrapping the towel too tightly will not only inhibit breathing, but can lead to excessive retention of body heat leading to hyperthermia. The mask used for induction, without the latex glove, should be placed over its head or beak to provide oxygen. The patient should be held in this fashion, being careful not to inhibit the movement of the sternum, until it can hold itself upright. At that point it should be placed in a dark, padded box and the box placed in a heated, oxygenated cage. This will allow the animal to fully recover in a less stressful environment. If a bird has not been fasted correctly prior to surgery, regurgitation can occur during recovery. Most patients will appear fully recovered from anesthesia within 30 minutes to 2 hours.

Products Mentioned in the Text

- ADS 1000 Penlon Sigma Delta — Sevoflurane Vaporizer, Penlon Limited, Radley Road, Abingdon, OX14 3PH, UK; Positive Pressure Ventilator, Engler Engineering Corp, 1099 E. 47th St, Hialeah, FL, USA
- Isoflo, Abbot Laboratories, North Chicago, IL, USA
- Ultane, Abbot Laboratories, North Chicago, IL, USA
- Suprane, Anaquest, Madison, WI, USA
- Parks Doppler Pediatric Probe, Parks Electronics, Aloha, OR, USA
- Cardio Companion ECG Probe; Cardio Companion Esophageal Lead; ECG-Pulse oximeter V3404, SurgiVet Inc, SurgiVet Anesco, Veterinary Surgical Products, Waukesha, WI, USA
- Dopram-V, Fort Dodge Laboratories, Fort Dodge, IA, USA
- Epinephrine 1:1000, Vedco, Inc, St. Joseph, MO, USA
- Atropine, Elkins-Sinn, Inc, Cherry Hill, NJ, USA
- Respirot, Novartis, Agro Benelux BV, Animal Health Sector, Steenvelden 10, Rousendiial, The Netherlands
- Bair Hugger, www.bairhugger.com

Parts of this chapter are reprinted or paraphrased from Exotic DVM 5(3):15-20, 2003 and from BSAVA Manual of Psittacine Birds 2nd Ed 2005, pp 87-96. Permission granted by Zoological Education Network, Inc and BSAVA 2005.

References and Suggested Reading

1. Abou-Madi N: Avian Anesthesia. In Heard DJ (ed): Vet Clin No Am. Exot An Prac 4:147-167, 2001.
2. Campbell VL, Drobatz KJ, Perkowski SZ: Postoperative hypoxemia and hypercarbia in healthy dogs undergoing routine ovariohysterectomy or castration and receiving butorphanol or hydromorphone for analgesia. J Am Vet Med Assoc 222:330-336, 2003.
3. Curro TG, Brunson DB, Paul-Murphy J: Determination of the ED50 of isoflurane and evaluation of the isoflurane-sparing effect of butorphanol in cockatoos (*Cacatua* spp.). Vet Surg 23:429-433, 1994.
4. Edling TM: Gas anesthesia: How to successfully monitor and keep them alive. Proc Assoc Avian Vet, 2001, pp 289-301.
5. Edling TM, et al: Capnographic monitoring of African grey parrots during positive pressure ventilation. J Am Vet Med Assoc 219:1714-1717, 2001.
6. Eger EI II: New inhalational agents: Desflurane and sevoflurane. Can J Anaesth 40(5):R3-R5, 1993.
7. Franchetti DR, Kilde AM: Restraint and anesthesia. In Fowler ME, (ed): Zoo and Wild Animal Medicine. Philadelphia, WB Saunders Co, 1978, pp 359-364.
8. Greenacre CB, Quandt JE: Comparison of sevoflurane to isoflurane in Psittaciformes. Proc Assoc Avian Vet, 1997, pp 123-124.
9. Korbel R: Vergleichende Untersuchungen zur Inhalationsanästhesie mit Isofluran (Forene) und Sevofluran (SEVOrane) bei Haustauben (*Columba livia* Gmel., 1789, var. *domestica*) und Vorstellung eines Narkose-Referenzprotokolls fuer Voegel. Tierärztliche Praxis 26 (K):211-223, 1998.
10. Korbel R, et al: Aerosacul perfusion with isoflurane: An anesthetic procedure for head surgery in birds. Proc Assoc Avian Vet, 1993, pp 9-37.
11. Kramer MH: Managing endotracheal tube mucus plugs in small birds. Exotic DVM 4(5):9, 2002.
12. Ludders JW, Mathews N: Birds. In Thurmon JC, Tranquilli WJ, Benson JG (eds): Lumb and Jones Veterinary Anesthesia 3rd ed. Baltimore, MD, Williams & Wilkins, 1996, pp 645-669.
13. Ludders JW, Rode J, Mitchell GS: Isoflurane anesthesia in sandhill cranes (*Grus canadensis*): Minimal anesthetic concentration and cardiopulmonary dose-response during spontaneous and controlled breathing. Anesth Analg (Cleve) 68:511-516, 1989.
14. Ludders JW, Rode JA, Mitchell GS: Effects of ketamine, xylazine and a combination of ketamine and xylazine in Pekin ducks. Am J Vet Res 50(2):245-249, 1989.
15. Ludders JW, Mitchell GS, Rode J: Minimal anesthetic concentration and cardiopulmonary dose response of isoflurane in ducks. Vet Surg 19:304-307, 1990.
16. Machin KL, Caulkert NA: The cardiopulmonary effects of propofol in mallard ducks. Proc Am Assoc Zoo Vets, 1996, pp 149-154.
17. Magnussen H, Willmer H, Scheid P: Gas exchange in air sacs: Contribution to respiratory gas exchange in ducks. Respir Physiol 26:129-146, 1976.
18. Mansour A, et al: Anatomy of CNS opioid receptors. Trend Neurosci 11:308-314, 1988.
19. McLelland J: Larynx and trachea. In King AS, McLelland J (eds): Form and Function in Birds Vol 4. London, Academic Press, 1989, pp 69-103.
20. McLelland J: Anatomy of the lungs and air sacs. In King AS, McLelland J (eds): Form and Function in Birds Vol 4. London, Academic Press, 1989, pp 221-279.
21. Muir WW, Hubbell LA: Inhalation anesthesia. In Muir WW, Hubbell LA (eds): Handbook of Veterinary Anesthesia. St. Louis, MO, Mosby, 2000, pp 154-163.
22. Muir WW, Hubbell LA: Pharmacology of inhalation anesthetic drugs. In Muir WW, Hubbell LA (eds): Handbook of Veterinary Anesthesia. St. Louis, MO, Mosby, 2000, pp 164-181.
23. Muir WW, Hubbell LA: Anesthetic machines and breathing systems. In Muir WW, Hubbell LA (eds): Handbook of Veterinary Anesthesia. St. Louis, MO, Mosby, 2000, pp 210-231.
24. Phalen DN, Lau MT, Filippich IJ: Considerations for safely maintaining the avian patient under prolonged anesthesia. Proc Assoc Avian Vet, 1997, pp 111-116.
25. Powell FL, Scheid P: Physiology of gas exchange in the avian respiratory system. In King AS, McLelland J (eds): Form and Function in Birds Vol 4. London, Academic Press, 1989, pp 393-437.
26. Scheid P, Piiper J: Aerodynamic valving in the avian lung. Acta Anaesth Scand 33:28-31, 1989.
27. Schmitt PM, Gobel T, Trautvetter E: Evaluation of pulse oximetry as a monitoring method in avian anesthesia. J Avian Med Surg 12(2):91-99, 1998.
28. Steffey EP, et al: Enflurane, halothane, and isoflurane potency in horses. Am J Vet Res 38:1833-1836, 1977.
29. Steffey EP, et al: Isoflurane potency in the dog and cat. Am J Vet Res 39:573-577, 1978.
30. Sturkie PD: Heart and circulation: Anatomy, hemodynamics, blood pressure, blood flow. In Sturkie PD (ed): Avian Physiology 4th ed. New York, Springer-Verlag, 1986, pp 130-166.
31. Valverde A, et al: Determination of a sedative dose and influence of midazolam on cardiopulmonary function in Canada geese. Am J Vet Res. 51(7):1071-1074, 1990.
32. Woolf CJ, Chong MS: Preemptive analgesia: Treating postoperative pain by preventing the establishment of central sensitization. Anesth Analg 77(2):362-379, 1993.