

of species as they are killed. The methods may thus be applied to assess the effects of anaesthesia or killing procedures on the welfare of fish. The application of the tests should make it possible to ensure that fish are killed with the minimum of suffering, and may also help to improve the existing slaughter procedures or devise new, more humane, methods.

#### ACKNOWLEDGEMENTS

The authors would like to thank the captain and crew of the trawler 'Koningin Juliana' for providing facilities for the deep-sea study and the owners of UK, Dutch, Norwegian and Spanish fish farms for providing fish and facilities. Dr P. D. Warriss and Mr A. Phillips are thanked for their help and assistance in the experimental studies.

#### References

- ANIL, M. H. (1991) Studies on the return of physical reflexes in pigs following electrical stunning. *Meat Science* **30**, 13-21
- FAWC (1996) Report on the welfare of farmed fish. London, Farm Animal Welfare Council
- GREGORY, N. G. (1987) Determination of impaired brain function in animals in the laboratory. In Pre-slaughter Stunning of Food Animals. Eds H. E. Carter, V. R. Carter. Horsham, European Conference Group on the Protection of Farm Animals. pp 2-16

- GREGORY, N. G. & WOTTON, S. B. (1983) Studies in the central nervous system: visually evoked cortical responses in sheep. *Research in Veterinary Science* **34**, 315-319
- GREGORY, N. G. & WOTTON, S. B. (1990) Effect of stunning on spontaneous physical activity and evoked activity in the brain. *British Poultry Science* **31**, 215-220
- KESTIN, S., WOTTON, S. & ADAMS, S. (1995) The effect of CO<sub>2</sub> concussion or electrical stunning of rainbow trout (*Oncorhynchus mykiss*) of fish welfare. In Quality in Aquaculture. Special Publication 23. Gent, European Aquaculture Society. pp 380-381
- KESTIN, S. C., WOTTON, S. B. & GREGORY, N. G. (1991) Effect of slaughter by removal from water on visual evoked activity in the brain and reflex movement in rainbow trout (*Oncorhynchus mykiss*). *Veterinary Record* **128**, 443-446
- MCFARLAND, W. M. (1959) A study of the effects of anaesthetics on the behaviour and physiology of fishes. *Publications of the Institute of Marine Science* **6**, 22-55
- MAFF (1995) The Welfare of Animals (Slaughter or Killing) Regulations. Statutory Instruments number 731. London, HMSO
- PALLIS, C. (1983) ABC of Brain Stem Death. London, British Medical Journal
- ROBB, D. H. F., WOTTON, S. B., MCKINSTRY, J. L., SØRENSEN, N. K. & KESTIN, S. C. (2000) Commercial slaughter methods used on Atlantic salmon: determination of the onset of brain failure by electroencephalography. *Veterinary Record* **147**, 298-303
- ROSS, L. G. & ROSS, B. (1999) Anaesthetic and Sedative Techniques for Aquatic Animals. Oxford, Blackwell Science
- VAN DE VIS, J. W., OEHLenschLÄGER, J., KUHLMANN, H., MÜNKNER, W., ROBB, D. H. F. & SCHELVIS-SMIT, A. A. M. (2001) Effect of commercial and experimental slaughter of eels (*Anguilla anguilla* L.) on quality and welfare. In Farmed Fish Quality. Eds S. C. Kestin, P. D. Warriss. Oxford, Blackwell Science. pp 234-248

## Myopathy in brown pelicans (*Pelicanus occidentalis*) associated with rancid feed

H. L. SHIVAPRASAD, R. CRESPO, B. PUSCHNER, S. LYNCH, L. WRIGHT

**Three adult brown pelicans (*Pelicanus occidentalis*) were observed to be weak, anorexic and unresponsive to antibiotics, anti-inflammatory drugs, vitamins including vitamin E, and steroids. Blood chemistry revealed high activities of aspartate aminotransferase, creatinine kinase and lactate dehydrogenase. Radiographs of the birds' leg muscles revealed multiple opacities suggestive of calcification; the gross lesions included white streaks in the leg, wing, and heart muscles, and the microscopical lesions consisted of various degrees of degeneration and necrosis characterised by eosinophilia, variations in fibre size, loss of striations, myolysis, mineralisation, and proliferation of mononuclear cells in the skeletal muscles and the myocardium. The levels of heavy metals, selenium and vitamin E in the birds' livers were not abnormal. The level of peroxide in their diet of capelin fish was high, 69 meq/kg, (normal <20 meq/kg) consistent with rancid feed, and the level of vitamin E was very low, 0.5 iu/kg (normal 20 to 30 iu/kg). It was concluded that the myopathy was probably caused by vitamin E deficiency due to feeding the pelicans a rancid diet.**

THE main diet of brown pelicans is anchovies, sardines and other surface-schooling fish (Anderson and others 1994). Some fish are very susceptible to autoxidation during storage because of their high concentrations of long-chain polyunsaturated fatty acids. Feeding rancid diets may induce myopathy, poor performance, or even death (Børsting and others 1998), because rancid fat contains toxic products that can decrease the palatability and digestibility of nutrients and damage cell membranes (Comporti 1993, Børsting and others 1998).

Vitamin E is a natural antioxidant that inhibits the formation of lipid-derived oxidation products (Rucker and Morris 1997); as a result, high dietary intakes of polyunsaturated dietary fats increase the utilisation of vitamin E. Nutritional degenerative myopathy due to vitamin E defi-

ciency has been recognised in many animal species, including birds (Campbell and Montali 1980, Nichols and others 1986, Austic and Scott 1997). In commercial poultry, and especially turkeys, vitamin E deficiency has been associated with encephalomalacia and myopathy of skeletal muscle, gizzard and heart, and vitamin E-related myopathy in wild birds and ostriches affects primarily the skeletal muscles (Hulstaert and others 1976, Campbell and Montali 1980, Nichols and others 1986, Austic and Scott 1997, Mushi and others 1998). Pansteatitis due to vitamin E deficiency has been reported in great blue herons (Nichols and others 1986).

Campbell and Montali (1980) attributed myopathy and sudden death in pelicans to a vitamin E deficient diet, but they did not analyse the birds' feed. Furthermore, in diagnosing vitamin E deficiency, the levels of peroxide in the feed are

*Veterinary Record* (2002)  
150, 307-311

H. L. Shivaprasad, BVSc, MS, PhD,  
R. Crespo, DVM, MS, DVSc, California Animal Health and Food Safety Laboratory System (CAHFS), Fresno Branch, University of California, Davis, 2789 South Orange Avenue, Fresno, CA 93725, USA  
B. Puschner, DVM, PhD, CAHFS Davis Branch, University of California, West Health Sciences Drive, Davis, CA 95617, USA  
S. Lynch, DVM,  
L. Wright, DVM, Chaffee Zoological Garden, 894 West Belmont Avenue, Fresno, CA 93728, USA

rarely analysed. This paper describes nutritional myopathy in three pelicans due to their being fed a rancid diet, even though it had been supplemented with vitamin E. The fish fed to the pelicans were tested for peroxide levels and vitamin E concentration.

**MATERIALS AND METHODS**

**Clinical history**

Three brown pelicans (*Pelicanus occidentalis*) were examined in April 1999. Two of them had been in the Chaffee Zoological Garden since 1996, and one had been acquired in 1998. Owing to the scarcity of smelt (*Spirinchus starksi*) due to the El Niño weather patterns during late 1998 and early 1999, capelin (*Mallotus villosus*) were fed to the pelicans. The fish were purchased in January 1999 and stored frozen. However, investigation revealed that the capelin had been caught in July 1998. Each pelican received approximately 1 kg of fish per day, and was supplemented with one tablet of commercially available avian multivitamins (Mazuri) daily, 25 mg of vitamin K (Merck) once a week, and 50 iu of vitamin E (Astra Zeneca) twice a week.

Two weeks before they were euthanased the pelicans showed signs of weakness and anorexia. Radiographs of the leg muscles showed areas of increased density (Fig 1), which were interpreted as calcification. Analysis of blood samples (IDEXX Labs) (Table 1) from the three pelicans showed that they had abnormally high activities of aspartate aminotransferase (AST), between 3000 and 5250 iu/litre (normal range 26 [2] iu/litre), creatinine kinase (CK), between 129,030 and 260,238 iu/litre (normal range 583 [76] iu/litre) and lactate dehydrogenase (LDH), between 6378 and 13,041 iu/litre (normal range 994 [258] iu/litre) (Puerta and others 1991). Two of the birds had a high count of white blood cells, probably in response to tissue injury (Table 1).

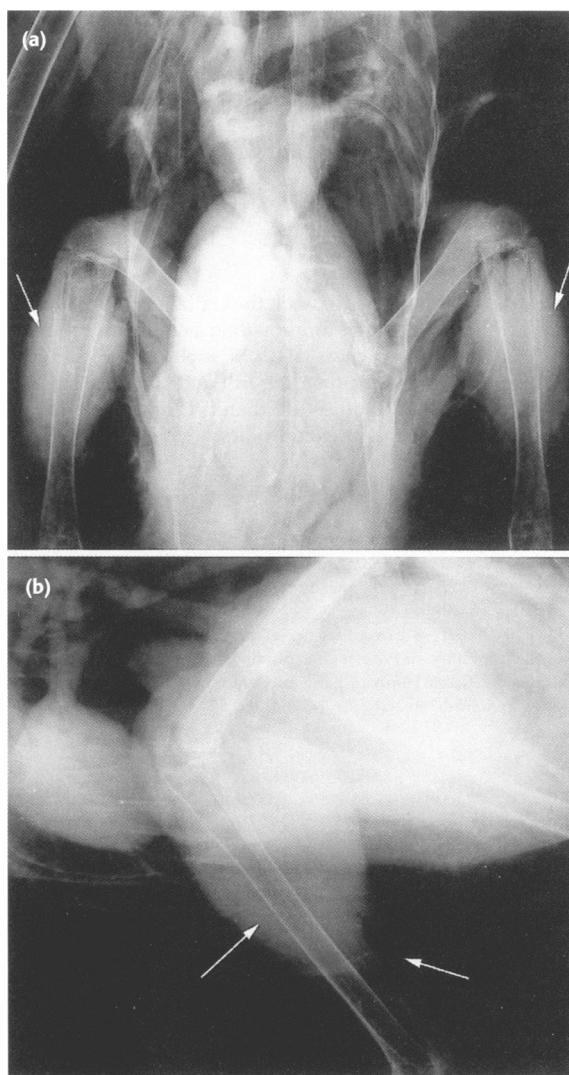
The three pelicans were treated orally with 17.7 mg/kg enrofloxacin (Bayer) daily for five days, intramuscularly with 0.1 mg/kg vitamin E/selenium (Schering-Plough) for two days, and orally with 0.06 mg/kg prednisone (Pharmacia & Upjohn) for one day. The first two pelicans were also treated orally with 30.5 mg/kg trimethoprim sulphadiazine (Coopers Animal Health) daily for five days. In addition, one of the pelicans was treated intramuscularly with 0.07 mg/kg dexamethasone (Steris) for one day. One week after the treatments the birds became recumbent and showed signs of respiratory distress, although the activities of AST, CK and LDH had decreased slightly (Table 1). Because of their physical deterioration and lack of response to treatment, the birds were euthanased with intravenous sodium pentobarbital (110 mg/kg) (Abbot).

**Postmortem examination**

The three birds were examined thoroughly postmortem and the gross lesions were recorded. Portions of skeletal muscle, heart, peripheral nerve, brain, bone, kidney, liver, spleen, eyes, sinus together with turbinates, trachea, lung, air sacs, oesophagus, proventriculus, gizzard, intestine, pancreas, adrenals, thyroids and gonads, were fixed in 10 per cent neutral buffered formalin, embedded in paraffin, sectioned at 4 µm, stained with haematoxylin and eosin, and examined by light microscopy.

**Toxicology**

Liver samples from the pelicans and muscle from one of them were analysed for heavy metals (arsenic, cadmium, copper, iron, lead, manganese, mercury, molybdenum and zinc), selenium and vitamin E, and the concentrations were expressed on a fresh weight basis. The heavy metals and selenium were analysed by inductively coupled plasma spectrometry (Galey



**FIG 1: Detail of (a) frontal and (b) lateral radiographs showing radiopacity of leg muscles (arrows) in one of the brown pelicans**

and others 1990). Vitamin E was analysed by high-pressure liquid chromatography (McMurray and Blanchflower 1979). The capelin were analysed for vitamin E and selenium concentrations in the same way, and the concentration of vitamin E in the capelin was also expressed on a fresh weight basis. To compare this value with the recommended level of vitamin E, which is expressed on a dry matter basis, the capelin

**TABLE 1: Haematological and biochemical measurements in blood samples taken from the pelicans before treatment and one week after treatment with vitamin E**

Variable	Pelican 1		Pelican 2		Pelican 3		Normal (se)* values
	Before	After	Before	After	Before	After	
Aspartate aminotransferase (iu/litre)	5250	3969	2835	3000	1827	26 (2)	
Creatinine kinase (iu/litre)	260,238	193,221	167,958	129,030	64,119	583 (76)	
Lactate dehydrogenase (iu/litre)	13,041	9366	7203	6378	4290	994 (258)	
Total protein (g/dl)	3.5	3.6	3.2	4.1	3.9	3.4 (0.3)	
Cholesterol (mg/dl)	176	228	214	198	270	99 (10)	
Glucose (mg/dl)	136	60	116	140	108	191 (20)	
Calcium (mg/dl)	9.9	9.4	8.5	9.7	9.9	NA	
Uric acid (mg/dl)	5.3	4.3	4.6	5.2	3.3	5.5 (0.1)	
Haematocrit (%)	45	42	46	46	44	41.1 (1.0)	
White blood cells (x10 <sup>3</sup> /µl)	14.0	21.5	21.4	24.5	26.3	13.5 (1.1)	
Heterophils (x10 <sup>3</sup> /µl)	11.3	13.1	16.7	15.9	21.3	8.0 (1.4)	
Lymphocytes (x10 <sup>3</sup> /µl)	1.8	8.2	4.5	7.8	4.7	4.8 (1.3)	
Eosinophils (x10 <sup>3</sup> /µl)	0.5	-	-	0.7	-	0.4 (0.1)	
Basophils (x10 <sup>3</sup> /µl)	0.4	0.2	0.2	0.1	0.3	0.1 (0.1)	

\* Puerta and others (1991)  
NA Not available

were assumed to contain 20 per cent dry matter. In addition the concentration of peroxide in the oil extracted from the capelin was determined by the method described by the American Oil Chemists' Society (1998).

### Microbiology

Samples of liver, heart blood and trachea were cultured for aerobic bacteria on 3 per cent sheep blood and MacConkey's agars (Remel), and incubated at 37°C in 7.5 per cent carbon dioxide for 48 hours. The trachea was also cultured for mycoplasma in modified Frey's medium and agar (Frey and others 1968). The plates were examined for typical mycoplasma colonies for two weeks. The intestines and their contents were cultured for salmonella in selenite broth, incubated at 37°C for 24 hours, and streaked on to brilliant green agar plates. Samples of liver and spleen from one bird were tested for chlamydia with a commercial fluorescent monoclonal antibody test (Bartels).

### Serology

Samples of serum from two of the pelicans were examined for antibodies to avian influenza virus (AIV) by agar gel immunodiffusion and for avian paramyxovirus 1 (APMV-1) by haemagglutination-inhibition tests, using reagents from the National Veterinary Services Laboratories, USA.

## RESULTS

### Pathology

The three pelicans were emaciated and weighed 2.9, 3.1 and 3.3 kg; they had no significant coelomic or subcutaneous fat stores. The most striking gross lesions were pale white streaks in the skeletal muscles of the wing, thigh and legs (Fig 2). Most of the muscles in the thighs and legs were also mildly to moderately enlarged and pale. Two of the birds had a few pale foci, 2 to 3 mm in diameter on the epicardium, which extended into the myocardium. In one bird, the papillary muscle beneath the mitral valve was diffusely pale (Fig 3), and in two birds the mitral valves were moderately thickened. In all the three birds the pectoral muscles were atrophied but did not have any pale streaks.

Microscopically, most of the skeletal muscles except for the pectoral muscles showed various degrees of degeneration and



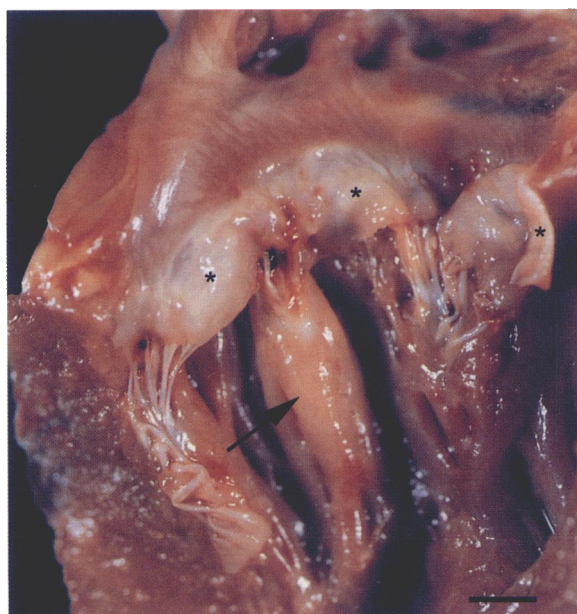
**FIG 2:** Pale white streaks in the leg muscles of one of the pelicans

necrosis, characterised by eosinophilia, loss of striations, variations in fibre size, vacuolations, mineralisation, and a proliferation of mononuclear cells (Fig 4). Similarly, the myocardium had mild to severe, multifocal degeneration of myofibres, occasional foci of necrosis, proliferation of mononuclear cells, and mild mineralisation (Fig 5). The periocular muscles were similarly affected, but to a milder degree. In addition, all the skeletal muscles including the pectorals, and the heart to a milder degree, had fatty infiltration in the interstitium. The adrenal glands had vacuolations in the cytoplasm of the cortical cells.

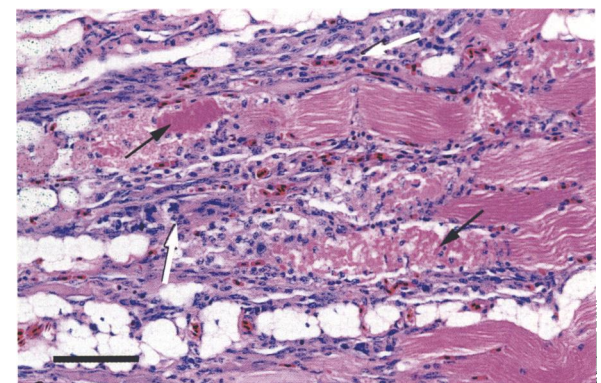
### Toxicology

The concentrations of heavy metals, vitamin E and selenium in the birds' livers were within the expected ranges for avian species (Puls 1994a, b). The concentrations of heavy metals, vitamin E and selenium have been established in muscle tissue for poultry (Table 2), but their normal levels in the muscle of other avian species are not known. Liver is generally the best organ for determining the concentrations of heavy metals and vitamin E.

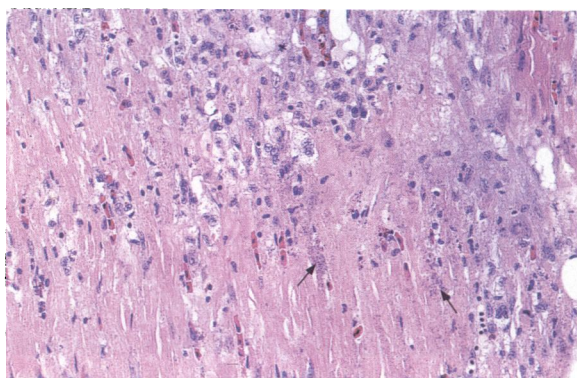
In the capelin fish, the concentration of vitamin E, 0.5 iu/kg fresh weight (2.5 iu/kg dry weight) (expected concentration 20 to 30 iu/kg of feed), was particularly low, and the concentration of selenium, 0.204 mg/kg fresh weight (1.02 mg/kg dry weight) (expected concentration 1.30 to 2.00 mg/kg of feed), was lower than expected (National Research Council US Subcommittee on Poultry Nutrition 1994) (Table 2). The concentration of peroxide in the capelin was very high, 69 meq/kg oil (Table 2); non-rancid feed should contain less than 20 meq/kg peroxide (Edmunds 1990).



**FIG 3:** Heart of one of the pelicans, showing a pale white area in the papillary muscle (arrow) beneath the mitral valves (★). There are also white streaks in the endocardium of the auricle. Bar=0.5 cm



**FIG 4:** Photomicrograph of skeletal muscle with extensive degeneration, necrosis (black arrows) and proliferation of mononuclear cells (white arrows). There are adipocytes scattered throughout the section. Haematoxylin and eosin. Bar=75 µm



**FIG 5: Photomicrograph of myocardium showing extensive degeneration, necrosis, infiltration of mononuclear cells and mineralisation (arrows). Haematoxylin and eosin. x 250**

### Microbiology and serology

The routine cultures were negative for aerobic bacteria including salmonella and mycoplasma. The bird tested for chlamydia was negative. The serum samples from the two birds tested for antibodies to AI and APMV-1 were negative.

### DISCUSSION

The clinical signs, the haematological findings, and the gross and microscopic lesions in the pelicans were indicative of myopathy, which was probably due to vitamin E deficiency. The concentration of vitamin E in their diet of capelin was extremely low (0.5 iu/kg fresh weight or 2.5 iu/kg dry matter). This low concentration of vitamin E in the fish probably resulted from the high level of peroxides, 69 meq/kg oil, due to rancidity. Although the pelicans were supplemented with 50 iu/kg of vitamin E twice weekly, it was insufficient because it is known that for optimum performance most birds require 20 to 30 iu of vitamin E/kg diet when fed a non-rancid diet (National Research Council US Subcommittee on Poultry Nutrition 1994). The capelin supplied only 3.5 iu per week, and the supplement of 100 iu per week would therefore have been inadequate to make up the shortfall, particularly in the presence of high levels of peroxide.

The long-term storage of the fish probably caused it to become rancid, owing to an increase in peroxide level that also resulted in low vitamin E levels. It is known that the long-term storage of fish can result in a depletion of vitamin E (Geraci and St Aubin 1990). The long-term storage of fish was attributed as the cause of vitamin E deficiency resulting in myopathy in captive brown pelicans (Campbell and Montali 1980).

The vitamin E concentrations in the livers of two of the pelicans were within the normal range because the pelicans had been supplemented with vitamin E for a week before they were euthanased. In addition, the concentrations of AST and CK, plasma enzymes associated with muscle damage, decreased, suggesting a slight improvement as a result of the supplementation. However, the birds' clinical signs did not improve, probably because of the extensive and severe muscle damage. Since the capelin fed to the pelicans were rancid and had high peroxide levels, it is hypothesised that most of the vitamin E in the fish had been depleted while it was being transported or stored, in the process of removing free radicals (Rucker and Morris 1997). Rancid feed also contains toxic aldehydes which can damage the mitochondria and cell membranes (Comporti 1993).

The myopathy in these pelicans affected primarily the leg and wing muscles, and to a smaller extent the heart. The lesions were similar to those described in pelicans fed a diet consisting solely of frozen smelt in which hypovitaminosis E

**TABLE 2: Concentrations of vitamin E, selenium, heavy metals and peroxide in the livers of the three pelicans, in the muscle of pelican 3, and in their capelin fish diet, expressed on a fresh weight basis**

	Pelican 1	Liver Pelican 2	Pelican 3	Normal† values	Muscle (Pelican 3)	Capelin
Vitamin E (iu/kg)	68.6	56.1	31.4	15-40	100	0.5
Selenium (mg/kg)	1.92	0.945	0.999	0.35-1.0	0.195	0.204
<b>Heavy metals</b>						
Arsenic (ppm)	Not detected	Not detected	Not detected	0.02-0.25	2	ND
Cadmium (ppm)	0.8	Not detected	Not detected	0.01-0.5	Not detected	ND
Copper (ppm)	4.7	3.1	5.5	3.0-15.0	1.3	ND
Iron (ppm)	662	204	281	60-300	47.8	ND
Lead (ppm)	Not detected	Not detected	Not detected	0.1-0.5	Not detected	ND
Manganese (ppm)	1.96	2.27	3.39	2.0-4.0	0.13	ND
Mercury (ppm)	Not detected	Not detected	Not detected	0.01-0.1	Not detected	ND
Molybdenum (ppm)	0.5	Not detected	Not detected	NA	Not detected	ND
Zinc (ppm)	28	66.3	31.7	25-40	17.9	ND
Peroxide (meq/kg/oil)	ND	ND	ND	NA	ND	69

† Normal values for poultry (Puls 1994a, b)

ND Not determined, NA Not available

was suspected (Campbell and Montali 1980, Nichols and others 1986). The presence of high concentrations of peroxide in the diet has also been associated with skeletal and cardiac myopathies (Cabel and others 1988, Kennedy and Rice 1992). Steatitis has also been associated with hypovitaminosis E in several species of mammals and birds (Dennis and Alexander 1982, Nichols and others 1986, Hulland 1993, Rucker and Morris 1997). No steatitis was observed in these three pelicans, probably because their fat stores had been depleted, and possibly because the lesions induced by hypovitaminosis E may be different in different species of birds.

Other morphologically similar myopathies may be caused by overexertion (Jones and others 1974) and ionophore toxicosis (Cardona and others 1993). Exertional myopathy was unlikely because the pelicans had been in captivity for some time and the pectoral muscles were not involved, and ionophore toxicosis was ruled out because ionophores were not added to their diet.

This case demonstrates that when purchasing fish its date of catch should be known, so that fish which may have become rancid while being transported and stored can be rejected. A knowledge of the effects of storage time on the nutrient composition of different species of fish, good communication with the seafood distributors and the length and quality of transport and storage are important factors when buying a diet for fish-eating animals. Unless they are supplemented with an adequate amount of vitamin E, nutritional myopathy may occur when birds are fed rancid feed, as a result of vitamin E depletion and/or the accumulation of toxic products. The results also demonstrate the value of measuring peroxides in the feed as a useful tool for establishing a diagnosis of vitamin E deficiency, rather than relying on the analysis of vitamin E in liver. This is especially important in animals which have been supplemented with vitamin E but continue to show muscle degeneration due to feeding the rancid diet.

### ACKNOWLEDGEMENTS

The authors thank the staff at Chaffee Zoo, CAHFS – Fresno, and the toxicology department at CAHFS – Davis, for their excellent technical assistance, and Dr Michael McFarland for reviewing the manuscript.

### References

AMERICAN OIL CHEMISTS' SOCIETY (1998) Peroxide value, acetic acid-chloroform method. In Official and Recommended Practices of the AOCS.

- 5th edn. Champaign, American Oil Chemists' Society. Section Cd8-53
- ANDERSON, D., ELLIOT, B., GRESS, F., VINCENT, K. & WOEK, T. (1994) California brown pelican. In *Life on the Edge: a Guide to California's Endangered Natural Resources: Wildlife*. Eds C. G. Thelander, M. Crabtree. Santa Cruz, California, BioSystem Books. pp 132-135
- AUSTIC, R. E. & SCOTT, M. (1997) Nutritional diseases. In *Diseases of Poultry*. 10th edn. Eds B. W. Calnek, H. J. Barnes, C. W. Beard, L. R. McDougald, Y. M. Saif. Ames, Iowa State University Press. pp 47-73
- BØRSTING, C. F., ENGBERG, R. M., JENSEN, S. K. & DAMGAARD, B. M. (1998) Effects of high amounts of dietary fish oil of different oxidative quality on performance and health of growing-furring male mink (*Mustela vison*) and of female mink during rearing, reproduction and nursing periods. *Journal of Animal Physiology and Animal Nutrition* **79**, 210-223
- CABEL, M. C., WALDROUP, P. W., SHERMER, W. D. & CALABOTTA, D. F. (1988) Effects of ethoxyquin feed preservative and peroxide level on broiler performance. *Poultry Science* **67**, 1725-1730
- CAMPBELL, G. & MONTALI, R. (1980) Myodegeneration in captive brown pelicans attributed to vitamin E deficiency. *Journal of Zoo Animal Medicine* **11**, 35-40
- CARDONA, C. J., GALEY, F. D., BICKFORD, A. A., CHARLTON, B. R. & COOPER, G. L. (1993) Skeletal myopathy produced with experimental dosing of turkeys with monensin. *Avian Diseases* **37**, 107-117
- COMPORITI, M. (1993) Lipid peroxidation. Biopathological significance. *Molecular Aspects of Medicine* **14**, 199-207
- DENNIS, J. M. & ALEXANDER, R. W. (1982) Nutritional myopathy in a cat. *Veterinary Record* **111**, 195-196
- EDMUNDS, B. K. (1990) Chemical analysis of lipid fractions. In *Feedstuff Evaluation*. Eds J. Wiseman, D. J. A. Cole. Boston, Butterworths. pp 197-213
- FREY, M. L., HANSON, R. P. & ANDERSON, D. P. (1968) A medium for the isolation of avian mycoplasma. *American Journal of Veterinary Research* **29**, 2163-2171
- GALEY, F. D., STENNING, B. D., ANDERSON, M. L., BRENNEMAN, P. C., LITTLEFIELD, E. S., MELTON, L. A. & TRACY, M. L. (1990) Lead concentrations in blood and milk from periparturient dairy heifers seven months after an episode of acute lead toxicity. *Journal of Veterinary Diagnostic Investigation* **2**, 222-226
- GERACI, J. R. & ST AUBIN, D. J. (1990) Nutritional disorders of captive fish-eating animals. In *The Comparative Pathology of Zoo Animals*. Washington, DC, Smithsonian Institution Press. pp 41-49
- HULLAND, T. J. (1993) Muscles and tendons. In *Pathology of Domestic Animals*. Eds K. V. F. Jubb, P. C. Kennedy, N. Palmer. 4th edn. San Diego, California, Academic Press. pp 183-264
- HULSTAERT, C. E., MOLENAAR, I., DE GOEIJ, J. J., ZEGERS, C. & VAN PIJPE, P. L. (1976) Selenium in vitamin E-deficient diets and the occurrence of myopathy as a symptom of vitamin E deficiency. *Nutrition and Metabolism* **20**, 91-94
- JONES, J. M., KING, N. R. & MULLINER, M. M. (1974) Degenerative myopathy in turkey breeder hens: a comparative study of normal and affected muscle. *British Poultry Science* **15**, 191-196
- KENNEDY, S. & RICE, D. A. (1992) Histopathologic and ultrastructural myocardial alterations in calves deficient in vitamin E and selenium and fed polyunsaturated fatty acids. *Veterinary Pathology* **29**, 129-138
- MCMURRAY, C. H. & BLANCHFLOWER, W. J. (1979) Application of a high-performance liquid chromatographic fluorescence method for the rapid determination of alpha-tocopherol in the plasma of cattle and pigs and its comparison with direct fluorescence and high-performance liquid chromatography-ultraviolet detection methods. *Journal of Chromatography* **178**, 525-531
- MUSHI, E. Z., ISA, J. F. W., CHABO, R. G., BINTA, M. G., NYANGE, J. & MODISA, L. (1998) Selenium-vitamin E responsive myopathy in farmed ostriches (*Struthio camelus*) in Botswana. *Avian Pathology* **27**, 326-328
- NATIONAL RESEARCH COUNCIL US SUBCOMMITTEE ON POULTRY NUTRITION (1994) *Nutrient Requirements of Poultry*. 9th revised edn. Washington, DC, National Academy Press
- NICHOLS, D. K., CAMPBELL, V. L. & MONTALI, R. J. (1986) Pansteatitis in great blue herons. *Journal of the American Veterinary Medical Association* **189**, 1110-1112
- PUERTA, M. L., GARCÍA DEL CAMPO, A. L., HUECAS, V. & ABELANDA, M. (1991) Hematology and blood chemistry of the white pelican (*Pelecanus onocrotalus*). *Comparative Biochemistry and Physiology. A: Comparative Physiology* **98**, 393-394
- PULS, R. (1994a) *Mineral Levels in Animal Health: Diagnostic Data*. 2nd edn. Clearbrook, BC, Sherpa International. pp 26-296
- PULS, R. (1994b) *Vitamin Levels in Animal Health: Diagnostic Data and Bibliographies*. 2nd edn. Clearbrook, BC, Sherpa International. pp 112-113
- RUCKER, R. B. & MORRIS, J. G. (1997) The vitamins. In *Clinical Biochemistry of Domestic Animals*. Eds J. J. Kaneko, J. W. Harvey, M. L. Bruss. 5th edn. San Diego, California, Academic Press. pp 703-739

*Veterinary Record* (2002)  
**150**, 311-313

**D. S. Mills**, BVSc, MRCVS,  
**S. Cook**, BSc, Animal  
Behaviour, Cognition and  
Welfare Group, Faculty  
of Applied Sciences,  
De Montfort University  
Lincoln, Caythorpe Court,  
Caythorpe, Lincolnshire  
NG32 3EP

**B. Jones**, BSc, MSc, PhD,  
Department of Medical  
Statistics, Faculty of  
Computing Sciences and  
Engineering, De Montfort  
University Leicester, The  
Gateway, Leicester  
LE1 9BH

Mr Mills' present address  
is Animal Behaviour,  
Cognition and Welfare  
Group, University of  
Lincoln, Caythorpe,  
Lincolnshire NG32 3EP

## Reported response to treatment among 245 cases of equine headshaking

**D. S. MILLS, S. COOK, B. JONES**

THE treatment of equine headshaking remains a problematic area for the veterinary practitioner despite recent advances (Newton and others 2000). Many potential treatment options are not exclusive to the veterinary surgeon, but in the interests of equine welfare and client service, it is important that the practitioner has an informed opinion about the potential utility of these. The aim of this study was, therefore, to review the current treatment choices of owners with afflicted horses, their reported success and the potential reasons for this.

Data for this study were gathered as part of the National Equine Headshaking Survey (NEHS) (Mills and Geering 1997).

## SHORT COMMUNICATIONS

Owners were asked to complete a 64-item, self-administered postal questionnaire relating to their horse, its management and clinical history. Details regarding the survey technique and population characteristics are described by Mills and others (2002). Fourteen of the items on the questionnaire related to treatment which was classified under the following nine headings: traditional veterinary therapy; use of 'back' specialists; homoeopathy; other alternative therapies; use of a nose net; use of an ear net; use of a face net; use of feed supplements; and any other method. A three-point scale ranging from complete through partial to no success was used to qualify the level of response to each type of treatment tried. A chi-squared analysis was used to test for any association between any degree of positive response to treatment among the different types of net (facial, nose and ear). Chi-squared analysis was also used to test for an association between success with an ear net and the occurrence of side-to-side headshaking.

Two hundred and forty-five useable responses to the survey were received and all owners had attempted some form of treatment. Approximately 75 per cent (184) of these reported that they had consulted a veterinary surgeon about their horse's condition, but traditional veterinary therapy was used