

- RIGGS, J. E. (1995) Neurological manifestations of electrolyte disturbances. In *Neurology and General Medicine: the Neurological Aspects of Medical Disorders*, 2nd edn. New York, Churchill Livingstone, p 325
- ROBERTSON, G. L., AYCINERA, P. & ZERBE, R. L. (1982) Neurogenic disorders of osmoregulation. *American Journal of Medicine* 72, 339-353
- SEWARDS, T. V. & SEWARDS, M. A. (2000) The awareness of thirst: proposed neural correlates. *Consciousness and Cognition* 9, 463-487

## Incidence of juvenile osteodystrophy in hand-reared grey parrots (*Psittacus e erithacus*)

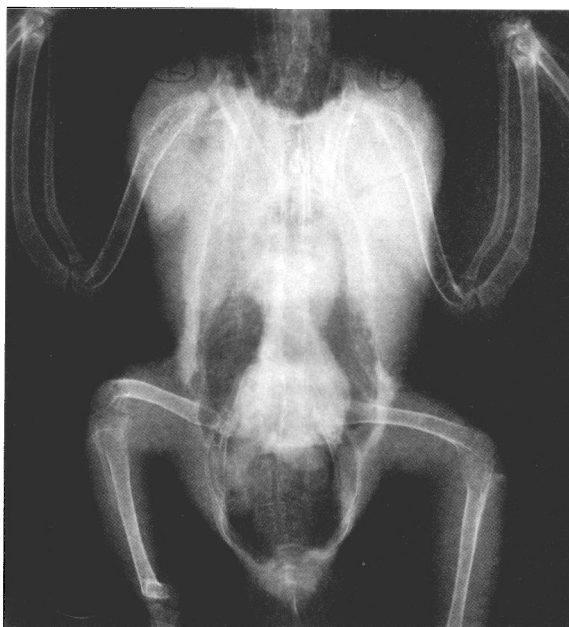N. HARCOURT-BROWN

IT is widely accepted that captive grey parrots (*Psittacus e erithacus*) are often affected by clinical signs that can be attributed to a lack of calcium and vitamin D in their diets. Adult pet birds (unproductive birds) can suffer from hypocalcaemic convulsions (McDonald 1988), adult breeding birds (productive birds) can be affected by egg-binding and also osteoporosis, and growing birds can be affected by bony deformities that range from relatively inapparent to gross deformities with the birds obviously crippled (Macwhirter 1994). Radiography has been used routinely to demonstrate juvenile osteodystrophy in many species of birds (Kostka and others 1988). Juvenile osteodystrophy causes weakness of the bones as they are growing, resulting in the weakened bones bending and twisting as the bird becomes heavier and stronger. Once they have occurred these deformities are permanent. This short communication describes the incidence of osteodystrophy in hand-reared grey parrots.

During a prospective study of pet parrots which were obsessively chewing and plucking their feathers, each bird was examined using a standardised procedure. As part of this, the bird was anaesthetised and examined. The examination included palpation of the bones and joints to assess any abnormal shape and longitudinal rotational deformity. Each bird was then examined radiographically using the same film, screens and processing, as well as views and positioning. The aim of this radiographic examination was to assess the whole bird, especially the body cavity. It was not possible to assess the birds for the presence of osteodystrophy without anaesthesia and a physical and radiographic examination.

During the course of the study, it became apparent that many of the grey parrots had bony deformities. From the group of 44 birds of various species, the radiographs of all the grey parrots (34 birds) were examined for signs of juvenile osteodystrophy. All the birds were known to have been hand reared. None of the breeders of these birds was known and neither were the diets of the parent birds, nor the diet on which the birds had been fed while they were growing. At the time of presentation, all the birds were skeletally mature; their ages ranged from 16 weeks to 13 years (average 3.8 years) and they were being fed on a variety of diets.

The following bones were selected for examination: furcula (fused clavicles), carina (keel), ribs, humerus, radius, ulna and pelvis, including the synsacrum, femur and tibiotarsus. The radiographs were examined for signs of skeletal diseases and, if necessary, comparing them with radiographs and skeletons of wild-caught, imported, adult grey parrots.



**FIG 1: Ventrodorsal view of a grey parrot, taken with the carina superimposing the notarium and the wings and legs slightly extended. Both radii and ulnae and the right tibiotarsus can be seen to have been deformed by juvenile osteodystrophy**

The ventrodorsal view (Fig 1) showed all the bones that were being assessed. The lateral view (Fig 2) had superimposition of many of the long bones; it was very helpful if the legs were positioned so that they were not superimposed. Two views were usually needed to make a decision about the shape of the bone. A single view, especially of minor deformities, tended to be misleading.

Examination of the radiographs showed that, of the group of 34 grey parrots, 19 birds (56 per cent) had normal bones and 15 birds (44 per cent) had signs of juvenile osteodystrophy. None of the birds had been presented because the owners thought that it had a problem with any of its limbs or bones. Although in some cases the deformities were quite severe, none of them appeared to be related to the bird's obsessive feather plucking and chewing. Twelve of the birds could not fly; in 10 cases this was due to a clipped wing, mutilation, or because the bird was not allowed out of its cage. Of the two cases with the greatest wing deformity (bent radii and ulnae), one could not fly well, but the other could fly (by the owner's standards).

Some of the birds appeared to adopt a wide-based stance when perched normally. Five cases also had apparent leg problems: a deformed foot, an apparently lame left leg, a pressure lesion on the plantar aspect of the metatarsophalangeal junction of digit I, flat feet, and one bird sucked one foot. While the first case had deformed tibiotarsi, especially on the side with the deformed foot, the other four cases showed no signs of osteodystrophy.

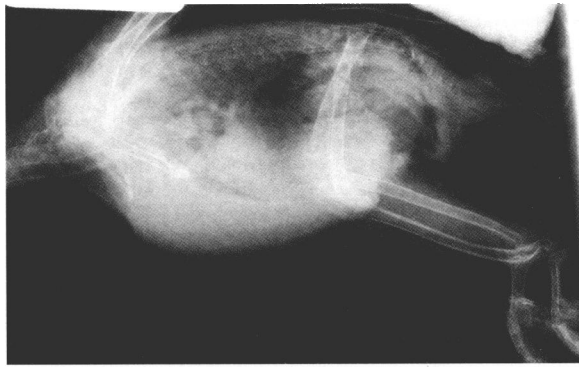
Based on its radiographic appearance, the furcula was not affected in any of the birds but the tibiotarsus was affected in all the birds. In addition, in 25 per cent of the birds the keel was affected, in 41 per cent the ribs were affected, in 8 per cent the humerus was affected, in 33 per cent the radius was affected, in 33 per cent the ulna was affected, in 25 per cent the pelvis/synsacrum was affected and in 25 per cent the femur was affected.

Presuming that all bones in a bird are equally affected by osteodystrophy, the distribution of deformity in this study, where the tibiotarsus was always affected and the furcula never affected, may be explained by the weight-bearing potential of each bone. The tibiotarsus is the bone that takes all the bodyweight when standing or walking, whereas the furcula acts as a spring while flying, so will be unaffected by any strain in growing birds. In addition, limb deformity causes abnor-

*Veterinary Record* (2003)  
152, 438-439

**N. Harcourt-Brown,**  
BVSc, DipECAMS, FRCVS,  
30 Crab Lane, Harrogate,  
North Yorkshire HG1 3BE

**FIG 2: Lateral view of the grey parrot in Fig 1, with the wings held in dorsal extension by a sandbag and the legs extended caudoventrally with ties, showing both tibiotarsi deformed by juvenile osteodystrophy**



mal weight distribution which leads to pressure sores on the plantar aspect of the foot; this is common in older, deformed birds.

These birds had been sold for relatively large sums of money and all the owners had been assured that the birds were well reared and correctly fed. None of the owners realised that there were significant deformities in these birds. This study shows that it is important that breeders feed their birds a diet which contains adequate calcium and vitamin D. This includes the parent birds because the female birds lay down medullary bone from about six weeks before egg laying. No breeders think that they are feeding a bad diet; however, none of them tests the results of their breeding programme. It is suggested that breeders should test the results of their breeding/rearing by having a proportion of their young birds examined radiographically. When buying a bird, a thorough pre- or postpurchase examination should include radiography.

### References

- KOSTKA, V., KRAUTWALD, M. E., TELLHELM, B. & SCHILDGER, B. (1988) A contribution to radiologic examination of bone alterations in psittacines, birds of prey and pigeons. *Proceedings of the Association of Avian Veterinarians*. Lake Worth, USA, 1988. pp 37-59
- MCDONALD, L. J. (1988) Hypocalcaemic seizures in an African grey parrot. *Canadian Veterinary Journal* **29**, 928-930
- MACWHIRTER, P. (1994) Malnutrition. In *Avian Medicine: Principles and Application*. Eds B. W. Ritchie, G. J. Harrison, L. R. Harrison. Lake Worth, Wingers Publishing. pp 842-861

## Evaluation of an anaesthetic protocol for the neutering of eight- to 12-week-old puppies

C. M. PATEL, D. YATES

THE conventional age for the neutering of dogs is six months or older; however, there appears to be no scientific reason for the selection of this age (Lieberman 1987). Numerous studies in the USA have been carried out showing the safety of standard neutering techniques and a number of anaesthetic protocols for the neutering of eight- to 12-week-old puppies (Grandy and Dunlop 1991, Faggella and Aronsohn 1994). However, the agents and, in particular, the combinations used

**TABLE 1: Mean values for age, weight and surgical time of the 30 puppies**

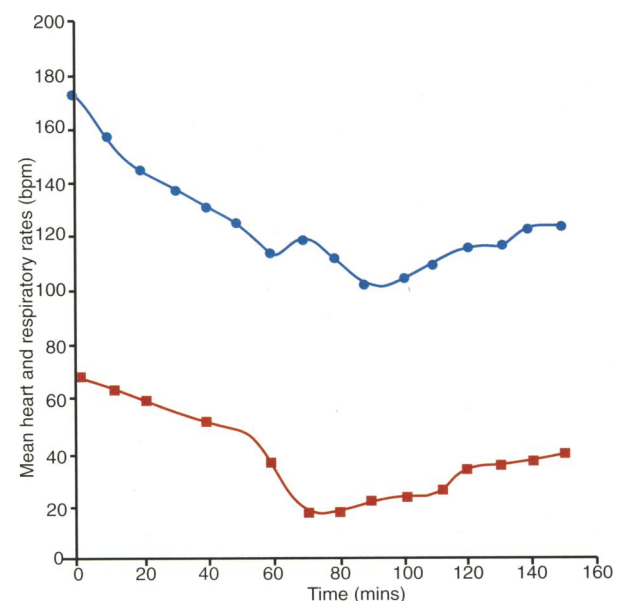
	Male	Female	All puppies
Mean age (weeks)	10	10.6	10.3
Mean weight (kg)	5.2	4.4	4.8
Mean surgical times (mins)	8.2	13.5	10.9

**TABLE 2: Mean values for induction, recovery and total anaesthetic periods**

	Male	Female	All puppies
Mean induction to intubation time (mins)	3.5	4.4	4.0
Mean extubation to standing time (mins)	8.5	8.5	8.5
Mean total anaesthetic period (mins)	26.5	33.5	30.0

in the most recent study (Faggella and Aronsohn 1994) may be unfamiliar to the general veterinarian. The long-term effects of neutering puppies aged seven weeks on their physical, skeletal and behavioural development have been shown to be similar to neutering dogs aged seven months (Salmeri and others 1991). This short communication describes the evaluation of an anaesthetic protocol using readily available and licensed agents in the UK to anaesthetise eight- to 12-week-old puppies for the purpose of early neutering.

Thirty puppies aged eight to 12 weeks (mean age 10.3 weeks old) of varying breeds comprising of 15 males and 15 females, were selected from puppies presented to the Royal Society for the Prevention of Cruelty to Animals – Greater Manchester Animals Hospital for rehoming. The puppies were given a full physical examination, were weighed on digital scales (mean weight 4.8 kg), were treated with oral febantel, praziquantel and pyrantel embonate at one tablet per 10 kg bodyweight (Drontal Plus; Bayer) and immunised with a standard canine vaccine (Nobivac DHPPi & Lepto; Intervet). Food was withheld for two to four hours before surgery only. The puppies were premedicated with 0.02 mg/kg buprenorphine (Vetergesic; Alstoe Animal Health)



**FIG 1: Effect of the premedication (t=0) and induction (t=60) on the mean heart (●) and respiratory (■) rates up to 150 minutes after premedication**

*Veterinary Record* (2003)  
152, 439-440

C. M. Patel, BVetMed,  
MRCVS,  
D. Yates, BVSc, MRCVS,  
RSPCA – Greater  
Manchester Animals  
Hospital, 411 Eccles New  
Road, Salford,  
Manchester M5 5NN

Mr Patel's present address  
is 97 Uxbridge Road,  
Rickmansworth,  
Hertfordshire WD3 7DJ